

# A Rare Case of Neoplastic Transformation in a Longstanding Case of Fistula-in-Ano

Neeru Gupta\*, Chhaya Gupta, Aruna Sud

Department of pathology, Sri Balaji Action Medical Institute, New Delhi, India

**Keywords:** *Mucinous Adenocarcinoma , Fistula In-Ano*

### ABSTRACT

Mucinous adenocarcinoma developing in a long standing case of fistula in-ano is rare. A case of fistula– in-ano diagnosed as low grade mucinous adenocarcinoma on biopsy and confirmed on Immunohistochemistry is discussed. It was established that the carcinoma had developed within the fistula and was not a secondary manifestation of any other tumor.

**\*Corresponding author:**

Dr. Neeru Gupta, BN-41, East Shalimar Bagh, Delhi.110088, India

Phone: +91- 9871603553

E-mail: drguptaneeru@gmail.com



## Introduction

Fistula in ano may rarely show neoplastic transformation without any prior or pre-existing rectal mucosal carcinoma. Rosser first reported a series of 7 patients in 1934. Skir in 1948 reported 50 cases and added 2 cases of his own. By 1966, Heindenreich et al were able to collect reports of a total 131 such occurrences. Each report usually cited only 1 or 2 cases of these rare tumors.<sup>[1]</sup> Nelson et al reported 6 cases of cancer in fistulas which had been present for an average of 13.8 years.<sup>[2]</sup> Most of these malignancies are low grade mucinous type, slow growing and are diagnosed as insidious finding in a clinically unsuspected scenario. The biopsy tissue sent from the fistulous tract is superficial and does not include the representative area is the common pitfall entrapping the histopathologist. The tissue examined comprises of external opening of the tract which reveals extensive scarring fibrosis and inflammatory infiltrate resulting in missing the underlying carcinoma<sup>[3,4]</sup>. Out of various diagnostic imaging modalities, Magnetic resonance imaging (MRI) has proven to be most one of accurate pre-operative imaging technique and should be considered in the cases of perianal fistula specially if they are long standing and recurrent.<sup>[5]</sup>

## Case Report

A 61-year-old male presented in the surgical OPD with history of anal pain and pus discharge from the anal region for past 6 months. The clinical examination performed revealed perianal abscess. The pus discharge was collected for microbiological examination and did not reveal any growth after 24 hours, 72 hours and after 1 week of culture. The haematological investigation revealed neutrophilia. The excision biopsy was also performed from the anorectal fistula detected. The histopathological examination revealed low grade well differentiated mucinous adenocarcinoma

with neoplastic glands enclosed in the lakes of extracellular mucin (Fig 1,2). Lymph node sampling was not carried out as clinicians were not suspecting any malignancy. However further investigations were carried out once the report of malignancy was released and communicated to the clinicians. No hidden neoplastic regions were observed in the bowel mucosa on sigmoid colonoscopy carried out during post operative phase. Immunohistochemistry (IHC) was also performed after discussion with the treating clinician positivity for CK7, CK20 and CEA (Fig 3-5) was reported. Magnetic resonance imaging (MRI) performed histopathological workup did not reveal any residual disease but showed residual small pocket collections in the subcutaneous region of the perineum with one tract extending towards the posterior part of the anal verge and another tract extending towards the posterior part with few cystic spaces in its proximal aspect approximately 5cm from the anal verge.

The patient is kept under observation and did not develop any new complaints pertaining to the disease treated. The standard treatment modality comprising of abdominoperineal resection with or without neoadjuvant radiotherapy was not carried out as no residual tumor was detected on MRI and patient refused to undergo any further treatment.

## Discussion

Development of carcinoma in a case of long standing fistula-in-ano is very uncommon and often leads to diagnostic and therapeutic dilemmas for both pathologists as well as for treating clinicians in view of its rarity. In most of the cases clinical symptoms pertaining to the perianal disease are noted and development of supervening malignancy is overlooked.<sup>[3]</sup> Anal pain, rectal bleeding and secretion of pus from the perianal area are the frequent clinical

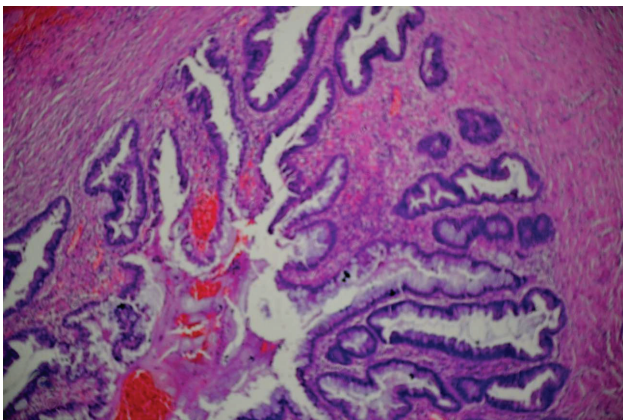


Fig. 1: Fistulous tract lined by tall columnar mucin secreting epithelium (H&E stain,600X)

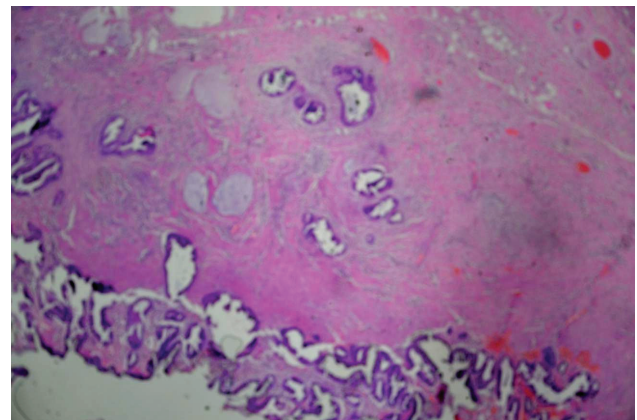
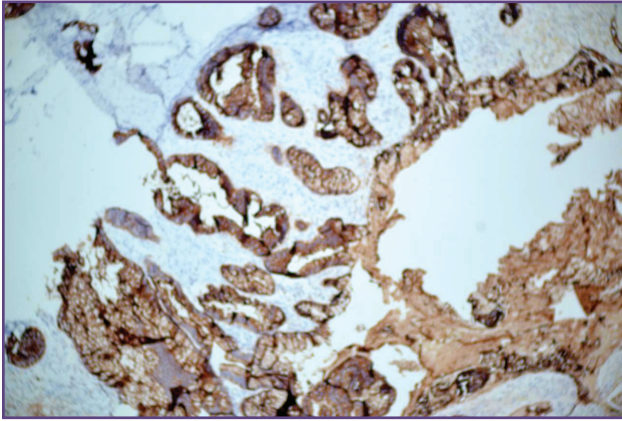
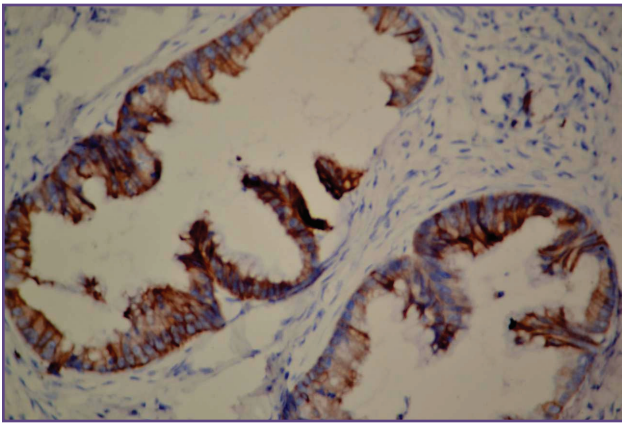


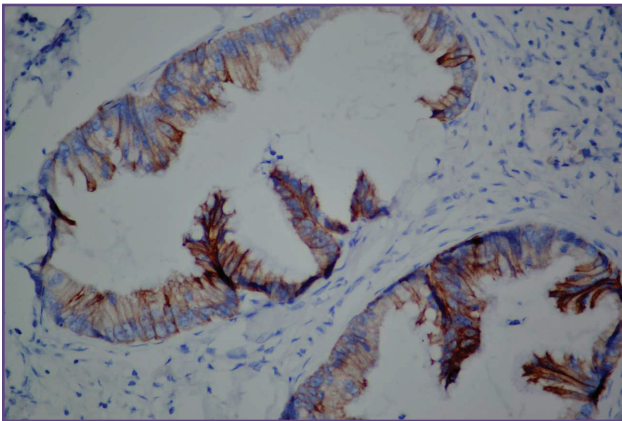
Fig. 2: Fistulous tract epithelium showing neoplastic change with focus of invasion (H&E stain,400X)



**Fig. 3: Fistulous tract epithelium showing neoplastic change with focus of invasion (CEA,100X, Inset 400X )**



**Fig. 4: Focus of Adenocarcinoma (CK7,400X )**



**Fig. 5: Focus of Adenocarcinoma (CK20,400X )**

symptoms addressed.<sup>[3,6]</sup> Biopsies of the fistulous tract or perianal mass are necessary to establish the diagnosis. An accurate staging of the neoplasm using endoanal ultrasound, MRI or CT scans are needed to plan the appropriate treatment<sup>[6]</sup> However MRI is the one best non

invasive imaging modality available.<sup>[4,5]</sup> The pathogenesis, biological behaviour and treatment modalities available are the matter of debate. Various features are being described to differentiate the malignancy originating in case of fistula-in-ano and perianal abscess along with the emphasis to separate them out from the usual rectal carcinoma. The study performed by Jones and Morson suggested that the fistulous tracts are congenital duplications of the lower end of the hindgut lined by rectal mucosa that is prone to malignant change to mucinous adenocarcinoma. Prioleau et al had ascertained that the disorder originates from the glands of the anal duct and fistulous tract precedes the development of malignancy which could be one possibility in our case. Three essential criteria were also defined by Rosner to document establishment of malignancy within the fistula<sup>[7]</sup> He stated that fistula should be chronic and must be present for last 8 – 10 years before the development of carcinoma into it. This is one of the best explanation in our case as our patient had suffered from 3 episodes of perianal abscess in last 3-4 years which got resolved after antibiotic treatment. Our patient also gave history of sigmoid colonoscopy performed outside which was normal. Rosner also documented that mucosal epithelium as well as mucosa of both the anal canal and rectum should be free of any primary tumor. Lastly the fistulous opening within the rectum or anal canal should not harbour any neoplastic tissue. In the present case, the opening of the fistula within the anal canal did not reveal tumor as proven on histopathology and MRI investigation showed no residual tumor post fistulectomy.

Abdominoperineal resection with or without neoadjuvant chemotherapy and radiotherapy is the main treatment modality.<sup>[5,6]</sup> The prognosis after surgical treatment is good if the condition is diagnosed and treated early and patient may not need adjuvant chemoradiotherapy. However the follow up of the patient is required.

### Conclusion

Perianal mucinous adenocarcinoma arising from an anorectal fistula is an uncommon malignant entity. However all the patient presenting with fistula-in-ano along with recurrent perianal abscess should be subjected to histopathological examination to obtain any hidden pockets of neoplastic transformation as in our case which is also the take home message of this case report. Although MRI investigation is one of the pre-invasive technique available but it is at clinician discretion to plan the work up based on his clinical suspicion. In our case MRI was carried out in post operative state to establish any hidden evidence of residual disease .

**Funding**

NIL

**Competing Interests**

NIL

**Reference**

1. Getz BS, Ough YD, Patterson RB, Kovalcir PJ. Mucinous adenocarcinoma developing in chronic anal fistula. *Diseases of colon and rectum* 1981;24:7,562-6
2. Nelson RL, Prasad ML, Abcarian H. Anal carcinoma presenting as a perirectal abscess or fistula. *Arch Surg* 1985;120:632-5
3. Nemandra S, Patsy RP, Antonio C, Andrew PZ. Synchronous mucinous adenocarcinoma of the rectosigmoid seeding onto a pre-existing anal fistula. *International Seminars in Surgical Oncology* 2006;3:25:1-3
4. Nagat AA, Mustafa AS, Ali A, Almabrouk A. Mucinous cystadenocarcinoma in chronic anorectal fistula: Clinical and MRI characteristics. *Ibnosina J Med B S* 2013;5:345-50
5. Nuray H, Esra O, Ayse E. MRI findings of mucinous adenocarcinoma arising from perianal fistula: Report of two cases. *GMJ* 2013;24:87-89
6. Linas V, Zilvinas S, Algimantas T, Darius P, Dainius P. Mucinous adenocarcinoma arising in an anorectal fistula. *Medicina (Kaunas)* 2009; 45(4)
7. Welch GH, Finlay IG. Neoplastic transformation in longstanding fistula-in-ano. *Postgraduate Medical J* 1987;63:503-504