

# HIV Seropositivity and Neoplasms with Plasma Cell Morphology: Plasmablastic Lymphoma and Plasma cell Myeloma : Is it a Chance Association or an Increasing Occurrence?

**Anupama Gupta, Dinkar Kumbhalkar, Sanjay Parate, Shirish Kawthalkar, Suprita Nayak, P. Kodate, N. Shende, G. Hake**

Department of Pathology, Government Medical College, Nagpur, Maharashtra, India

*Keywords: HIV, Plasma Cell Myeloma, Multiple Myeloma*

### ABSTRACT

Plasma cell tumors have shown an increased incidence in Human Immuno Deficiency Virus (HIV) positive patients. Plasma cell tumors in these patients occur in a younger age group than that in the general population, present at unusual sites and progress rapidly to involve multiple sites, including the soft tissues and viscera. Pathologically, many of these tumors show plasmablastic morphology. We present here six interesting cases of plasma cell tumor in HIV seropositive patients diagnosed on fine needle aspiration cytology (FNAC) and confirmed on histopathology and immunohistochemistry. These lesions presented at unusual locations like subcutaneous, oral and nasal. They presented at younger age, had aggressive behavior and unusual cytomorphology.

**\*Corresponding author:**

Dr. Anupama Gupta, , 203, Shyam Dham , C. A. Road, Ambedkar Square, Babulban, Nagpur, Maharashtra, India, Pin-440008

Phone: +91-9422477887

E-mail: pama\_gpta@rediffmail.com



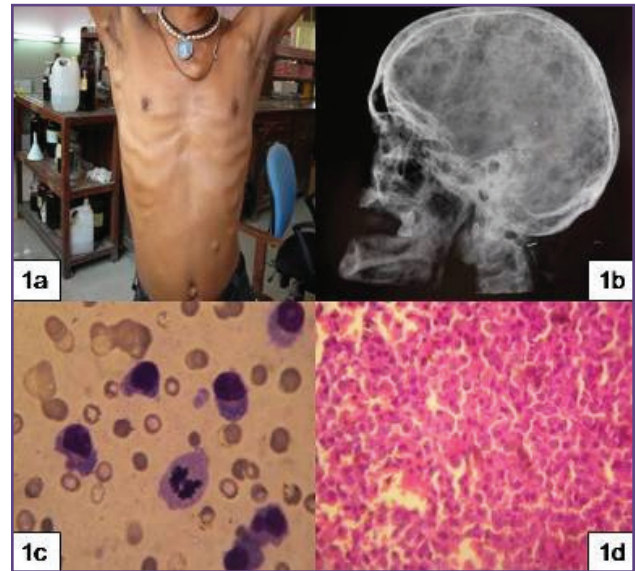
## Introduction

Acquired Immuno Deficiency disease (AIDS) is a retroviral disease characterized by profound immunosuppression that leads to opportunistic infections, secondary neoplasm and neurologic manifestations. The common malignancies associated with HIV infection are kaposi sarcoma, non hodgkin's lymphoma and squamous cell carcinoma. Plasma cell tumors have shown an increased incidence in HIV-positive patients. Plasma cell tumors in HIV positive patients occur in a younger age group (approximately 33 years) than their non HIV counterparts (50-75 years).<sup>[1]</sup> Plasma cell tumors in HIV-positive patients may present at unusual sites and progress rapidly to involve multiple sites, including the soft tissues and viscera, skin, breast, testes, oral cavity. <sup>[2, 3, 4]</sup> Pathologically, many of these tumors show plasmablastic morphology. The prognosis is generally poor.

## Case Report(S)

**Case No 1** - A thirty two years old HIV seropositive male patient presented with multiple subcutaneous nodules (30 in number) all over body involving left thigh, right hand, right cervical region, axilla, front and back of abdomen. CD 4 count was 576. He was on anti retroviral therapy (ART) since five months. He also had bilateral cervical and axillary lymph nodes palpable. Peripheral smear showed rouleaux formation and occasional atypical plasmacytoid cell. Total Leukocyte Count (TLC) and Differential Leukocyte Count (DLC) was within normal limits. X ray skull, chest wall and MRI brain, contrast & plain study revealed multiple heterogeneously enhancing intracalvarial lesions in frontal & right parietal region with multiple lytic lesions in skull vault and ribs. FNAC from right cervical lymph node and left chest wall subcutaneous nodule showed dispersed population of plasmacytoid cells with eccentrically placed nuclei with uni, bi and multinucleation. Nucleus showed features of immaturity in the form of open chromatin and presence of nucleoli. Cytoplasm was bluish with perinuclear hof and vacuolation. Serum protein electrophoresis revealed presence of 5mm thick sharp dense M band at gamma region 9mm away from slit. Bence Jones proteins were positive in urine. With above cytological, radiological features and positive M band diagnosis of Multiple Myeloma (MM) with extramedullary deposits was offered. Bone marrow aspirate showed 45 % atypical and typical plasma cells. Biopsy of the subcutaneous nodule confirmed presence of extramedullary deposits of Plasma cell neoplasm. [Fig 1] Patient started responding to chemotherapy and ART with decrease in subcutaneous nodules and decrease in bone marrow plasma cells.

**Case No. 2** – A thirty five years old HIV seropositive male patient presented with right sided nasal mass and severe

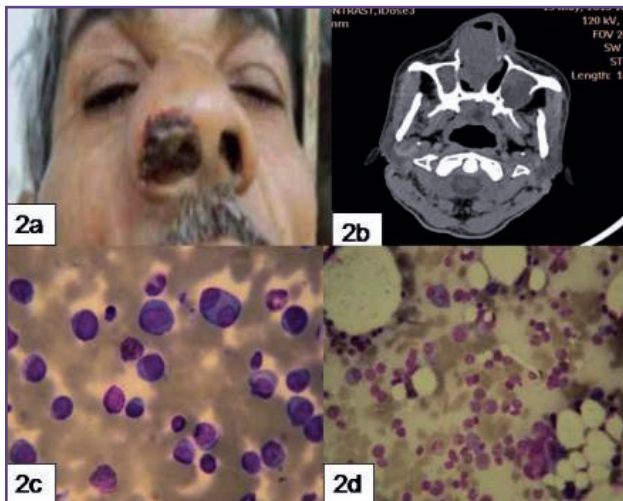


**Fig. 1:** (1a) clinical photograph showing multiple subcutaneous nodules over both axilla, suprasternal notch, chest wall, abdominal wall. (1b) X ray skull showing multiple punched out lytic lesions. (1c)(MGG stain 100X) FNAC from subcutaneous nodule showing plasma cells with eccentrically placed enlarged nuclei and a mitotic figure. (1d) (HE stain 10X) Biopsy of skin nodule showing sheets of plasma cells

headache since 3 to 4 months. CD 4 count was 300. He was not on ART. He had decreased appetite & weight loss. He had no history of fever/tuberculosis or trauma. There was a mass of 1x2 cm in right nostril coming out of vestibule. There was no cervical lymphadenopathy. Computed Tomography showed moderately enhancing lesion in right nostril and similar lesion in left maxillary sinus.

On FNAC, there was profuse bleeding. FNA smears showed mostly scattered population of plasmacytoid cells with uni/binucleation, enlarged, hyperchromatic nuclei at places with nucleoli and moderate amount of cytoplasm showing perinuclear hof. Scattered lymphoid cells, occasional eosinophils & lymphoglandular bodies were also seen. On FNAC diagnosis was offered as plasmacytoma. Serum protein electrophoresis revealed positive M band. Urine showed presence of Bence Jones proteins. Bone marrow study revealed presence of 40% plasma cells in bone marrow. Thus diagnosis of multiple myeloma with extramedullary mucosal deposits was offered. It was later confirmed on biopsy of nasal mass. [Figure 2] He responded to chemotherapy and nasal mass almost disappeared.

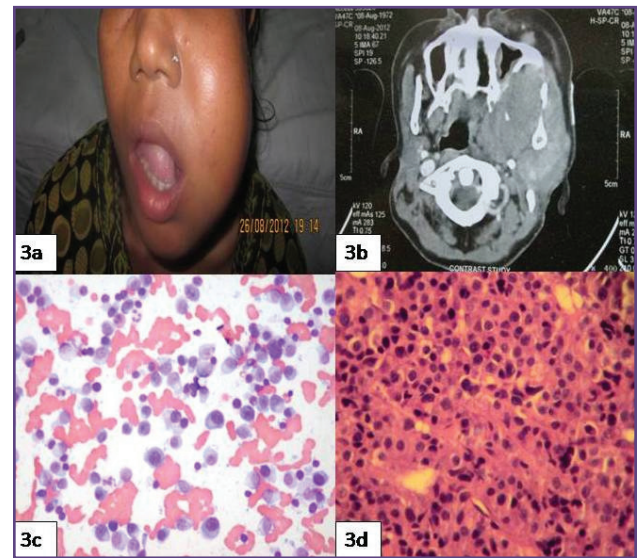
**Case 3** - A forty years old female, known HIV positive, chronic tobacco chewer who was on ART since eight months presented with swelling over left side of face since



**Fig. 2:** (2a) Clinical photograph showing friable mass in right nostril. (2b) Computed Tomography showing moderately enhancing lesion in right nostril and similar lesion in left maxillary sinus. (2c)(MGG stain 100X) FNAC of nasal mass showing scattered population of plasmacytoid cells with uni and bi nucleation. (2d)(leishman stain 40X) Bone marrow aspiration showing plenty of mature as well as immature plasma cells.

two months and mass in oral cavity which was rapidly increasing and was associated with pain and intermittent oral bleeding since one and half months. She gave past history of pulmonary tuberculosis one year back and had completed treatment. Her husband died due to some unknown disease five years back. She had multiple left cervical lymphadenopathy and a single lump in left breast in upper outer quadrant of size 2x2 cm which was firm, non tender, mobile. There was diffuse swelling over left side of face extending over left submandibular and submental region of size 10 x 8 cm. Swelling was firm, tender with raised local temperature. Oral cavity showed ulceroproliferative growth involving left side buccal mucosa, hard palate, upper alveolus, and floor of mouth, tonsillar fossa pushing uvula to right side which bled when touched. Investigation revealed haemoglobin of 9.8 gm %, HBsAg was positive. CD 4 counts were 256. Other haematological investigations were within normal limit. X-ray chest, X –ray spine and skull were within normal limits. Computed Tomography of oral cavity with neck revealed a large heterogeneously enhancing mass in relation to left hemimandible causing lytic destruction of left parapharyngeal and masticator space , extending superiorly up to left infra temporal fossa with erosion of pterygoid plate and inferiorly up to thyroid cartilage. Ultra sonography of abdomen showed multiple peripancreatic, perisplenic, and right iliac lymphadenopathy. FNAC

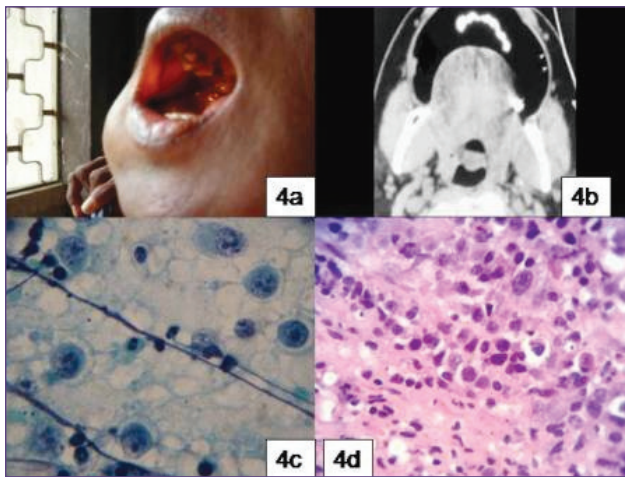
from oral growth and breast lump showed features of plasmacytoma. M Band was positive on serum electrophoresis. Urine Bence Jones proteins were negative. Biopsy from oral lesion showed sheets of plasma cells with uni, bi nucleation and presence of nucleoli. Bone marrow aspiration showed more than 45% plasma cells both typical and atypical thus confirming our diagnosis of plasma cell myeloma with extraosseous deposits. She died within one month after diagnosis. [Fig 3]



**Fig. 3:** (3a) Clinical photograph showing swelling over left side of face. (3b) Computed Tomography of oral cavity with neck showing a large heterogeneously enhancing mass in relation to left hemimandible causing lytic destruction of left parapharyngeal and masticator space , left infra temporal fossa with erosion of pterygoid plate and inferiorly up to thyroid cartilage. (3c) (MGG stain 40X) USG guided FNAC of left face swelling showing plenty of plasma cells and RBC showing rouleaux formation. (3d) (HE stain 10X) Biopsy from oral lesion showing sheets of plasma cells.

**Case 4** - A sixty five years old female presented with ulcerative growth over right buccal mucosa since three months. She had pain at local site. She gave history of washing mouth with tobacco containing product. Local examination revealed ulcerative, irregular growth over right buccal mucosa of 4X4 cm and swelling over cheek. There was no evidence of any lymphadenopathy. She was tested for HIV which was positive. . CD 4 count was 250. ART was started. M band was negative on serum electrophoresis. Computed Tomography of oral cavity showed mildly enhancing polypoidal mass involving right buccal mucosa. Scrape cytology & FNAC from growth in oral cavity showed singly scattered cells with moderate

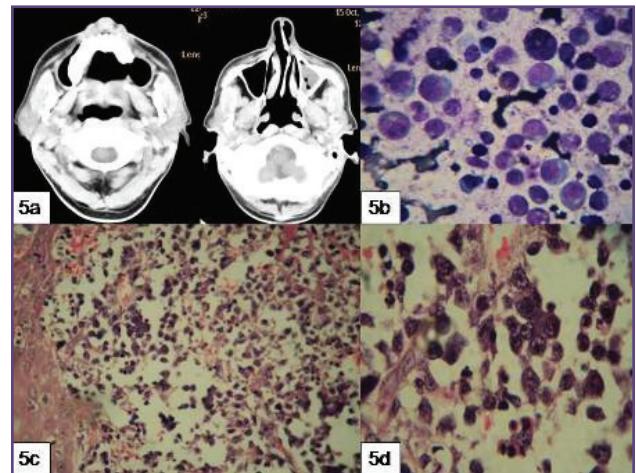
amount of cytoplasm with vacuolations. Nucleus was eccentric with open chromatin and prominent nucleoli. Cytologic features suggested diagnosis of Non Hodgkin's Lymphoma with plasmablastic morphology. Biopsy from oral lesion showed sheets of large cells with eccentrically placed nuclei and prominent nucleolus. Immunohistochemistry revealed CD 20, CD 138, CD 38 positivity confirming diagnosis of plasmablastic lymphoma. [Fig 4] Bone marrow showed eight percent immature plasmablastic cell. With ART and chemotherapy patient improved and his buccal swelling decreased.



**Fig. 4:** (4a) Clinical photograph showing ulcerative, irregular growth over right buccal mucosa and swelling over cheek. (4b) Computed Tomography of oral cavity showing mildly enhancing polypoidal mass involving right buccal mucosa. (4c) (Pap stain 100X)FNAC from growth showing singly scattered cells with moderate amount of cytoplasm, eccentric nucleus with open chromatin and prominent nucleoli. (4d) (HE stain 40X) Biopsy from oral lesion showing sheets of round cells with prominent nuclei.

**Case 5** - A fifty four years old HIV seropositive male, on ART since one year presented with left gingival growth. CD4 counts were 200. There was mildly heterogeneously enhancing polypoidal soft tissue noted involving left maxillary sinus causing its partial opacification without any expansion. It was causing permissive destruction of inferior & lateral wall of sinus to extend and involve the left buccal space & left maxilla with intraoral extension along inferior surface of hard palate without its bony destruction. FNAC from oral lesion showed scattered population of large round cells with open chromatin, prominent nucleolus and moderate amount of cytoplasm. Scattered mature plasma cells were also seen. Histopathology sections showed stratified squamous epithelium. Deeper tissue showed tumor mass composed of discrete cells

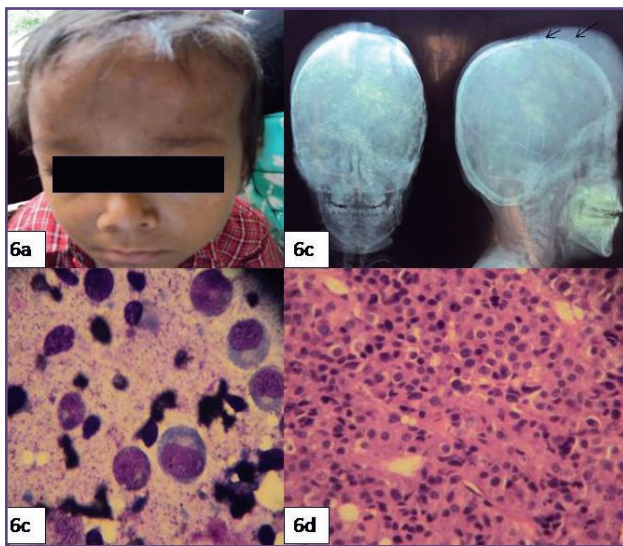
separated by fibrocollagenous stroma. Cells were round, oval to polygonal with scanty eosinophilic cytoplasm and large hyperchromatic, pleomorphic nuclei with prominent nucleoli. Mitotic figures and tumor giant cells were seen. Many cells showed plasmacytoid features. Tumor cells expressed MUM -1, CD 138(focal), CD 38(focal) and were immunoreactive for CD20, Pax-5, CD-79a, CD3, Cytokeratin, S-100 protein and HMB-45. In situ hybridization for EBV RNA was positive. There was predominance of lambda expressing cells over kappa expressing cells. Diagnosis was offered as Non Hodgkins lymphoma, Plasmablastic type. [Fig 5] Bone marrow aspirate showed 6-7 % plasma cells and few atypical cells. With ART and chemotherapy patient improved and his maxillary sinus opacity cleared to some extent and is improving.



**Fig. 5:** (5a) Computed Tomography showing mildly heterogeneously enhancing polypoidal soft tissue mass in left maxillary sinus causing its partial opacification and permissive destruction of inferior & lateral wall of sinus involving the left buccal space & left maxilla with intraoral extension. (5b) (MGG stain 40x) FNAC from oral lesion showing discrete large cells with bluish cytoplasm and large nuclei with nucleoli (5c) (HE stain 10X) Histopathology sections showing stratified squamous epithelium with tumor mass composed of discrete cells. Cells are round to polygonal with scanty eosinophilic cytoplasm and large hyperchromatic, pleomorphic nuclei with prominent nucleoli better seen in high power (5d).

**Case No 6-** A seven years old HIV positive child presented with multiple swellings over head and failure to thrive. Both his parents died of AIDS. His hemoglobin electrophoresis showed 'AA' pattern. Peripheral smear

showed rouleaux formation of red cells and few atypical plasmacytoid cells. TLC and DLC were within normal limits. X ray showed multiple lytic and sclerotic lesions involving whole of the cranial vault with break in outer table. CD 4 count was 210. ART was not yet started. Serum electrophoresis showed negative M protein. FNAC of the skull swelling revealed scattered population of large cells with eccentric single or multiple nuclei, prominent nucleoli and moderate amount of cytoplasm with perinuclear hof in many cells. Bone marrow aspiration showed 50% mature and immature plasma cells. Biopsy revealed similar cells in sheets and other marrow elements were depleted. Immunohistochemistry showed CD 138 positivity, CD 38 positivity, LCA negative and CD 56 negative. EBV RNA was negative. Thus diagnosis was offered as plasmablastic myeloma. [Fig 6] He died after one month of ART and was not put on chemotherapy



**Fig. 6:** (6a) Clinical photograph showing frontal swelling. (6b) X ray showing multiple lytic and sclerotic lesions involving whole of the cranial vault with break in outer table (arrows) and soft tissue swelling. (6c) (MGG stain 100X) FNAC from frontal swelling showing large cells with eccentric large nuclei and perinuclear hof. (6d) (HE stain 10X) Bone marrow biopsy showing sheets of large plasmablastic cells.

## Discussion

Highly active antiretroviral therapy (HAART) has significantly improved the outcome and survival of human immunodeficiency virus (HIV)-infected patients. Subsequently, long-term morbidities including cancer have become of major public health and clinical interest for this patient population. Plasma cell disorders occur at higher incidence in HIV-infected patients. [5] The etiology

of HIV related plasma cell neoplasm appears to be chronic antigenic stimulation. However, additional studies are required to elucidate the exact pathology of these plasma cell disorders. Plasma cell disorders in HIV-infected patients range from polyclonal hypergammaglobulinemia, to monoclonal gammopathy, to malignant plasma cell neoplasms such as multiple myeloma (MM), plasmablastic myeloma and plasma cell leukemia.

MM in HIV/AIDS patients has several unique characteristics. 1) In the general population, MM is a disease for older adults: the median age at diagnosis is 66 years but in HIV-infected patients, MM occurs at a much younger age 2) MM in HIV-infected patients shows an atypical clinical evolution; it tends to present as solitary bone plasmacytoma or extramedullary plasmacytoma. These patients also tend to have low level of M-protein despite the aggressiveness of the disease. Some patients may present as plasma cell leukemia. 3) The progression of MM in HIV-infected patients is very rapid and the overall survival is short. 4) MM in HIV-infected patients shows atypical histopathological findings, and some patients may present with anaplastic features. These anaplastic myeloma cells are negative for the common leukocyte antigen, lysozyme, and the cytoplasmic immunoglobulins. 5) MM in HIV-infected patients tends to occur in anal sex patients. 6) Elevated serum LDH level correlate with a poorer outcome in HIV/AIDS patients with MM. [5]

HIV infection contributes to the development of MM likely through several different mechanisms: 1) HIV infection increases the risk for somatic hypermutation; 2) HIV infection activates cell survival pathways; 3) HIV infection alters bone marrow niche microenvironment; and 4) HIV infection causes persistent antigen stimulation. [5]

We present here six cases of malignant plasma cell neoplasms. Clinical presentation, radiology, serum M protein, cytomorphology of lesion, hematological findings and bone marrow biopsy/ biopsy of the lesion was considered for diagnosis. Immunohistochemistry was done in selected cases. Our cases were seen at younger age, had unusual presentation like subcutaneous, oral mucosal and nasal presentation. Three cases had aggressive plasmablastic morphology. Serum M protein was positive in three cases and negative in three cases with plasmablastic morphology. CD4 counts were variable.

One of our patients was of plasma cell myeloma presenting as oral lesion. Very few cases of plasmacytoma of oral cavity have been presented. [2] They have recommended that patients presenting with extramedullary plasmacytoma

of the oral cavity, should undergo testing for HIV infection.<sup>[2]</sup> There are other reports of plasma cell neoplasm in HIV positive patients.<sup>[6,7]</sup>

Plasmablastic lymphoma, originally described in 1997 in a series of 16 patients,<sup>[8]</sup> is highly associated with advanced stages, and accounts for 2.6% of all HIV-related Non Hodgkins lymphoma (NHL). It is found with Epstein barr virus (EBV) (15%) and Human Herpes virus 8 (HHV8) (38%) infection. Average age of onset is much younger than would be expected for HIV-negative individuals, and commonly involves jaws, oral cavity, stomach, anorectum, nasal-paranasal areas and lungs.<sup>[9]</sup> Some HIV related plasma cell malignancies appear to exhibit anaplastic cytomorphology and may resemble plasmablastic lymphoma, a newly described HIV related NHL.<sup>[10, 11]</sup> Three of our patients presented with plasmablastic morphology. Two had oral lesions and one child had soft tissue involvement. One also had EBV positivity. According to Vega et al most cases of AIDS-related plasmablastic lymphoma have an immunophenotype and tumor suppressor gene expression profile virtually identical to plasmablastic plasma cell myeloma, and unlike diffuse large B-cell lymphoma. These results do not support the suggestion in the WHO classification that plasmablastic lymphoma is a variant of diffuse large B-cell lymphoma. The only significant difference between plasmablastic lymphoma and plasma cell myeloma were the presence of EBV-encoded RNA, which was positive in all plasmablastic lymphoma cases tested and negative in all plasma cell myelomas.<sup>[12]</sup>

Thus in patients showing cytological features of plasma cell myeloma on FNAC or on bone marrow examination, one should consider age of the patient and location of the tumor. In younger patient and tumor occurring at unusual location HIV testing should be done. Immature morphology like plasmablastic features advocates testing for HHV-8 and EBV virus testing and immunocytochemistry. AIDS-related lymphomas behave differently and should be suspected in any patient with HIV who has a sudden increase in size of the lymph node or presents with central nervous system (CNS) manifestations. These tumors have more aggressive clinical course, widespread involvement, are less responsive to chemotherapy and frequent relapse is seen.<sup>[9]</sup>

## Conclusion

Plasma cell disorders occur at an increased frequency in HIV-infected patients. They present with unusual clinical

manifestations, occur at unusual location and have aggressive behavior. The development of multiple myeloma involves diverse molecular mechanisms and pathways, and understanding these pathways has important implications in the treatment of multiple myeloma in general.

## Acknowledgements

None

## Funding

None

## Competing Interests

None

## Reference

1. Pantanowitz L, Dezube BJ. Multiple myeloma and HIV infection casual or casual coincidence? *AIDS Read* 2003;13:386-387
2. Nair RG, Sudha S, Shameena PM, Ipe VV. Plasmacytoma of the oral cavity associated with HIV infection - Causal or casual coincidence?. *J Oral Maxillofac Pathol* 2004;8:91-3
3. Miranda EG, Iravani S, Doll DC. Unusual presentations of malignancy. Case 2. Breast Plasmacytoma in a patient with human immunodeficiency virus *J Clin Oncol*, 2001;19:3290-3291.
4. Lallemand F, Fritsch L, Cywiner-Golenzner C, Rozenbaum W. Multiple myeloma in an HIV positive man presenting with primary cutaneous plasmacytomas and spinal cord compression. *J Am Acad Dermatol*, 1998;39:506-508.
5. Woodrow J Coker, Ashley Jeter, Henning Schade and Yubin Kang Plasma cell disorders in HIV-infected patients: epidemiology and molecular mechanisms. *Biomarker Research* 2013, 1:8 doi:10.1186/2050-7771-1-8
6. Gold JE, Schwam L, Castella A, Pike SB, Opfell R, Zalusky R. Malignant plasma cell tumors in human immunodeficiency virus-infected patients. *Cancer* 1990; 66: 363–368.
7. Salarieh A, Rao C, Gottesman SR, Alagha O, Todor R, Axiotis CA. Plasma cell tumors in HIV-positive patients: report of a case and review of the literature. *Leuk Lymphoma*. 2005;46:1067-74.
8. Delecluse HJ, Anagnostopoulos I, Dallenbach F, Hummel M, Marafioti T, Schneider U, et al. Plasmablastic lymphomas of the oral cavity: A new

- entity associated with the human immunodeficiency virus infection. *Blood* 1997;89:1413-20.
9. Saple DG, Shah I, Surjushe AU, Murthy A, Chudgar P, Gote PD. Lymphoma in HIV patients: Varied presentations. *Indian J Med Paediatr Oncol* 2010;31:39-42
  10. Stewart JM, Krishnamurthy S, Fine-needle aspiration cytology of a case of HIV associated anaplastic myeloma. *Diagn Cytopathol* 2002;27:218-22.
  11. Chetty R, Hlatswayo N, Muc R, Sabaratnam R, Gatter K. Plasmablastic lymphoma in HIV+ patients: an expanding spectrum. *Histopathology* 2003;42:605-609.
  12. Vega F, Chang CC, Medeiros LJ, Udden MM, Cho-Vega JH, Lau CC, Finch CJ, Vilchez RA, McGregor D, Jorgensen JL. Plasmablastic lymphomas and plasmablastic plasma cell myelomas have nearly identical immunophenotypic profiles. *Mod Pathol*. 2005;18:806-15.