

Unusual occurrence of Ewing's sarcoma/PNET with pregnancy: 2 case reports and literature review

Kumarbhargav R. Kaptan^{1*}, Vasudha M. Bhagat², Reena B. Dudhat³, Sonal L. Italiya⁴, Miteshkumar B. Shah¹

¹Toprani Advanced Lab System, Vadodara, Gujarat, India.

²GMERS Medical College and Hospital, Valsad, Gujarat, India.

³Tristar Superspeciality hospital, Surat, Gujarat, India

⁴BAPS Lab, Surat, Gujarat, India

Keywords: Ewing's sarcoma, PNET, Pregnancy, Sarcoma

Abstract

The occurrence of cancer in a pregnant woman is a relatively low-probability event. The influence of pregnancy on the initiation, promotion and development of sarcomas is yet unclear. Epidemiological data suggest that the incidence of cancer during pregnancy is 0.07% to 0.1% of all malignant tumours. To our knowledge, only few cases of Ewing's sarcoma/PNET developing during pregnancy have been described. The treatment approach is strongly influenced by the type and site of the primary tumour, its growth rate and associated symptoms, and by the need to treat the woman while minimizing foetal toxicity. Here we describe two cases of Ewing's sarcoma/PNET in a pregnant woman, in whom the diagnostic and therapeutic approaches were tailored in order to cure the patient and to avoid unnecessary toxicity to the foetus. One out of two patients underwent abortion and other successfully delivered baby before receiving treatment for underlying sarcoma.

***Corresponding author:**

Dr. Kumarbhargav R. Kaptan; 7/304, Amardeep society, B/H Ambika Denso, Maroli Bazar, Ta. Jalalpore, Dist. Navsari, Gujarat, 396436 (India)

E-mail: dr.bhargavkaptan@gmail.com

Date of Submission: April 20, 2014

Date of Acceptance: May 11, 2014

Date of Publishing: Sept 28, 2014

How to cite this paper:

Kaptan KR, Bhagat VM, Dudhat RB, Italiya SL, Shah MB. Unusual occurrence of Ewing's sarcoma/PNET with pregnancy: 2 case reports and literature review. *Annals of Pathology and Laboratory Medicine*. 2014;1(2):C5-C9.

Introduction

The occurrence of cancer in a pregnant woman is a relatively very rare event. According to recent literature, approximately 1 in 1,000 term pregnancies are complicated with cancer.^[1,2] This incidence is increasingly encountered in clinical practice with the rising trend of postponing pregnancy to later in life. The influence of pregnancy on the initiation, promotion and development of sarcomas is yet unclear. Breast cancer is the most common tumour treated during pregnancy followed by ovarian cancer, cervical cancer, leukaemia, lymphoma, and lung cancer.^[3,4] Bone and soft tissue sarcomas, being generally rare diseases, present more infrequently during pregnancy.^[1,5] To our knowledge, only few cases of Ewing's sarcoma developing during pregnancy have been described. The treatment approach is strongly influenced by the type and site of the primary tumour, its growth rate and associated symptoms, and by the need to treat the woman while minimizing foetal complications. We hereby present two cases of Ewing's sarcoma/PNET in a pregnant woman, in whom the diagnostic and therapeutic approaches were tailored in order to cure the patient and to avoid unnecessary toxicity to the foetus.

Case Report

We found 2 cases of Ewing's sarcoma/PNET associated with pregnancy at department of Pathology, Government Medical College, Surat during July 2010 to October 2012. Surgical specimens were received in histopathology department for accurate diagnosis, confirmation of malignancy and further subtyping of tumor with the aid of immunohistochemistry (IHC). After histopathological examination, relevant panel of immunohistochemical antibodies was applied using peroxidase anti-peroxidase method. The final diagnosis was achieved after correlating histopathological, immunohistochemical and other findings. Diagnosis was made according to criteria & grading of malignant soft tissue tumor. One of the sections representatives of malignancy, devoid of necrosis was selected for examining the expression of different immunohistochemistry (IHC) markers. In each staining series a known positive control section was taken. The technique used was based on PAP (peroxidase anti-peroxidase) method.

Case 1: A 35-year-female was admitted with huge soft tissue mass since 6 months at left scapular region measuring around 21 x 16 x 7cm. She was having 7 months amenorrhoea and pregnancy was confirmed on ultrasound (USG). She was having discomfort and difficulty in moving left upper limb

due to huge left scapular mass. Apart from that no other major complaints were noted. Keeping in mind about the pregnancy status biopsy of that huge scapular mass was done. We received biopsy bit measuring 1x0.5 cm. Morphologically, it was consistent with malignant round cell tumor with malignant round cells arranged in solid sheets and diffuse pattern [Figure 1]. Cells were having hyperchromatic nuclei, prominent nucleoli in few cells and scanty cytoplasm. After reviewing the morphology, relevant immuno panel was applied.

Immunohistochemistry findings: Tumor cells were immunonegative for Cytokeratin (panCK), LCA, S-100, Desmin, SMA, Chromogranin and Synaptophysin. Tumor cells expressed CD-99 marker in strong and diffuse manner [Figure 2]. So it was diagnosed as Ewing's sarcoma/PNET.

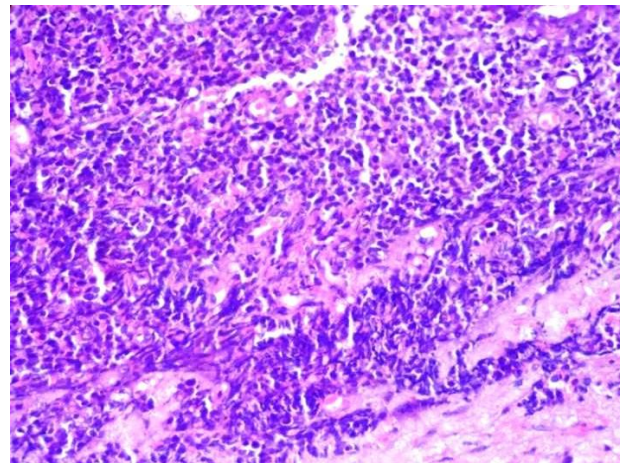


Fig 1: Diffuse monotonous proliferation of round cells & admixture of small round cells with crushed darker-staining cells in Ewing's/PNET (H&E stain, x400)

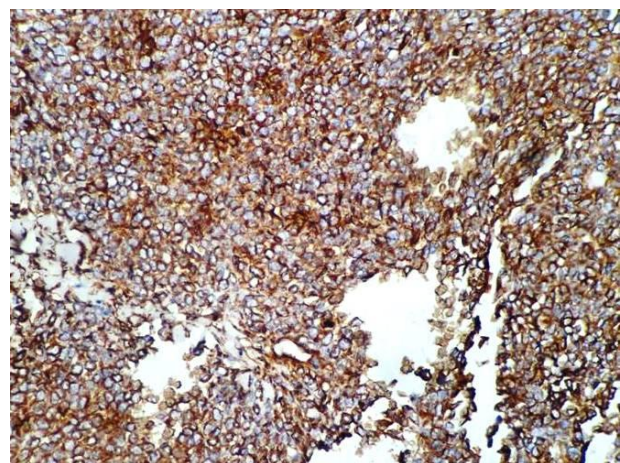


Fig 2: Diffuse and strong positivity of CD99 (CD99, DAB, x400)

We communicated to treating surgeons about the report. After confirmation and discussion with the patient, they decided not to treat before delivery

and patient underwent delivery first after completing term and then underwent further treatment for malignancy.

Case 2: Another 35-year-female was having 4 months of amenorrhoea and left sided cystic and solid thigh mass measuring 16 x 11 x 4cm. Due to such a huge mass on inner aspect of left thigh, patient was having difficulty while walking and pain as it was rubbing the other parts. Patient was confirmed pregnant by pregnancy tests and USG. Patient was referred for fine needle aspiration cytology (FNAC) of that thigh mass. On FNA, it was diagnosed as malignant small round cell tumor. Report was communicated to treating surgeons and discussion with patient and relatives were made. They finally excised that left thigh mass. We received whole skin covered excised mass measuring 16x11x4 cm. On sectioning it was having cystic and solid grayish white areas. Areas of cystic degeneration and necrosis were also present. Representative sections were examined and it was morphologically consistent with malignant round cell tumor with malignant round cells in diffuse sheets with cystic areas [Figure 3]. Relavent IHC panel was applied.

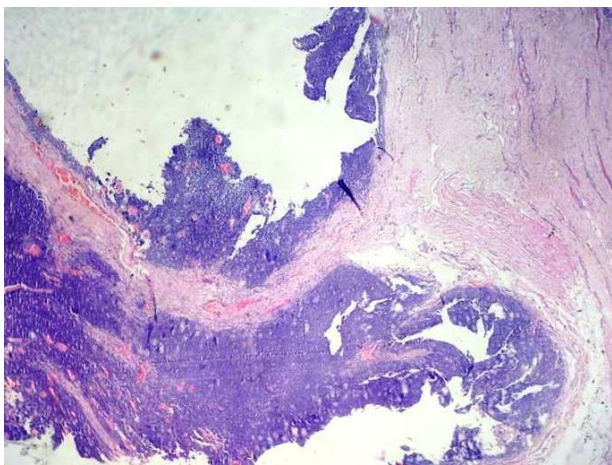


Fig 3: Cystic mass showing malignant round cells in Ewing's/PNET (H&E stain, x100).

Immunohistochemistry Findings: Tumor cells were immunonegative for Cytokeratin (panCK), EMA, LCA, S-100, HMB-45, Desmin, Chromogranin, SMA and CD-34. CD-99 came equivocal. Tumor cells were positive for Vimentin. Tumor cells also expressed CD-56 focally. Considering the morphology and rare expression of CD-56 in Ewing's sarcoma/PNET when CD-99 come equivocal,^[6] it explained the diagnosis. Diagnosis of Ewing's sarcoma/PNET was finally made. In this case after discussion with patient, pregnancy was terminated to avoid fetal toxicity

and other reasons. Further treatment for malignancy was given.

Discussion

Whenever a pregnant woman is diagnosed as having a malignant tumour, serious medical, ethical, emotional and religious dilemmas arise. Since there is very limited world-wide experience in managing cancer in pregnant women, it aggravates the uncertainty and confusion. The magnitude of this topic is becoming progressively larger among women to delay pregnancy to a more advanced age, when the risk of malignancy becomes higher.^[7] Our study points to the rare occurrence of soft tissue sarcomas, like Ewing's sarcomas/PNET in pregnant women causing variable symptoms and signs. Several types of soft tissue sarcomas, occurring anywhere in the body, have been reported in the literature in association with pregnancy. Sarcomas of the female reproductive system have also been reported in pregnant women. Lysyj et al reported the first case of Ewing's sarcoma of the pubic ramus during pregnancy in 1963.^[8] In the second case, a 21-year-old patient was diagnosed with Ewing's sarcoma of the left iliac wing at gestational age week 25.^[9] The third case was reported by Merimsky et al. describing Ewing's sarcoma of the right sacroiliac bone in a pregnant woman.^[2] Nakajima et al report 17-year-old woman with an extra-skeletal Ewing's sarcoma of the left leg who was treated with a combination of doxorubicin and ifosfamide during the 25th to 30th week of pregnancy.^[10] The 5th case report by Ateser et al describes the case of a PNET of the ovary diagnosed in the 24th week of gestation. After pregnancy, the mother was found to have metastatic disease and died due to progressive disease 13 months after the initial diagnosis.^[11] Huvos et al reported 18 pregnant women in whom osteosarcoma was diagnosed during pregnancy. Haerr et al reported a case of Ewing's sarcoma similar to ours, in a 21-year-old pregnant woman during 25th week of gestation.^[9] In every pregnant woman in whom a sarcoma is suspected, the diagnostic and therapeutic approaches have to be specifically tailored. Surgical procedures, such as open biopsy, tumour resection, and limb-sparing surgery, are regarded as relatively safe during pregnancy.^[11] Ancillary tests such as magnetic resonance imaging (MRI) and USG are also safe during pregnancy. The risk of chemotherapy during pregnancy depends on the drugs used and the gestational age of the foetus. In cases where the tumour and the foetus share the same limited space in the pelvis or abdominal cavity, premature labour might occur with a small-sized new-born. Thus, in the case of a favourable prognosis or curative situation, chemotherapy should be

given as early as possible. Despite lack of strong evidences, multi-agent chemotherapy should be instituted early in the course of malignant sarcomas since the risk of metastasis occurrence is high.

This topic leads to many questions like **whether pregnancy has any relation to the occurrence of cancer or especially the sarcoma and also the progression of growth of tumour.** According to Merimsky et al, enhancement of tumour growth was evident in the cases of osteosarcoma, anaplastic mesenchymal chondrosarcoma, high-grade synovial sarcoma, and Ewing's sarcoma.^[1] Several tumours may show growth acceleration during pregnancy. Among these are leiomyomatosis peritonealis disseminata, dermatofibrosarcoma protuberans, malignant fibrous histiocytoma, liposarcoma, malignant melanoma, meningiomas, aggressive angiofibroma.^[12,13] The true relationship between pregnancy or lactation and the development of malignant tumours in a particular woman is totally unclear and highly controversial. It has been suggested that the hormonal, physiological and the mechanical changes that are present within the body during or after pregnancy induce or promote the process of malignancy and metastasis.^[14,15] Capillary and cavernous hemangiomas, although benign, are prone to variations and fluctuation in size during pregnancy due to possible mechanism of the sensitivity of endothelial cells to hormonal changes within the body.^[6]

Whether the tumour has any relationship to the foetus? Tumours might occupy the space reserved for the foetus and uterus, as reported in patients with Ewing's sarcoma and pubic osteosarcoma in literature.^[9] Furthermore, tumours can metastasize to the placenta and foetus, although this is an infrequent occurrence.^[16]

What should be the strategy of management in such cases? Several factors may influence the medical decision regarding diagnostic and therapeutic approach. First, there is the estimated risk to the mother's life and health in continuing the pregnancy, the growth and progression of the mother's tumour, the related signs and symptoms, and the possible jeopardy to her survival contribute to the assessment of this risk. Second, there is the estimated immediate risk to the foetal life, health and expected postnatal growth, physical and mental maturation & genetic aberrations leading to future malignant transformation, in performing diagnostic procedures such as ancillary tests, biopsy and oncological treatments.^[17] Every therapeutic intervention should be clearly discussed with the patient and family but the final decision should always be made by the patient.

Conclusion

Association of malignancy especially the sarcoma in pregnancy is yet unexplained with many hypothesis but no strong supportive evidence of such an association is been explained clearly. There are no strict guidelines for the best medical decision in cases of pregnancy-associated malignancy. In each case of a pregnant woman with bone or soft tissue sarcoma, a specific approach differs by considering all the factors. The most important clue, in our opinion, is the curability of the mother's disease. In disease with a favorable prognosis, treatment should be given as early as possible

Acknowledgements

Dr. R.D.Patel (Ex. HOD of Pathology G.M.C. Surat and Presently Dean of G.M.E.R.S. Valsad) and Dr. B.M. Jha (HOD of Pathology G.M.C. Surat)

Funding

None.

Competing Interests

None declared.

References

1. Merimsky O, LeCesne A. Soft tissue and bone sarcoma in association with pregnancy. *ActaOncol* 1998; 37:721-7.
2. Merimsky O, Le Chevalier T, Missenard G, Lepechoux C, Cojean-Zelek I, Mesurolle B, et al: Management of cancer in pregnancy: a case of Ewing's sarcoma of the pelvis in the third trimester. *Ann Oncol* 1999; 10:345-50.
3. Azim H, Peccatori F, Pavlidis N. Treatment of the pregnant mother with cancer: a systematic review on the use of cytotoxic, endocrine, targeted agents and immunotherapy during pregnancy. Part I: Solid tumors. *Cancer Treat Rev* 2010;36:101-9.
4. Brewer M, Kueck A, Runowicz C. Chemotherapy in pregnancy. *ClinObstetGynecol* 2011; 54:602-18.
5. Hogendoorn PC, Athanasou N, Bielack S, De Alava E, Dei Tos AP, Ferrari S, et al. Bone sarcomas: ESMO Clinical Practice Guidelines for diagnosis, treatment and follow-up. *Ann Oncol* 2010;21:204-13.
6. Weiss &Goldblum.Enzinger and Weiss's Soft Tissue Tumors, 5th ed. St. Louis, Mosby Elsevier. 2008.
7. Doll DC, Scott Ringenberg Q, Yarbro JW. Antineoplastic agents and pregnancy. *Semin Oncol* 1989;16:337-46.

8. Lysyj A, Bergquist JR. Pregnancy complicated by sarcoma. Report of two cases. *ObstetGynecol* 1963; 21:506-9.
9. Haerr RW, Pratt AT. Multiagent chemotherapy for sarcoma diagnosed during pregnancy. *Cancer* 1985; 56:1028-33.
10. Nakajima W, Ishida A, Takashi M, Hirayama M, Washino N, Ogawa M, et al: Good outcome for infant of mother treated with chemotherapy for Ewing sarcoma at 25 to 30 week's gestation. *J PediatrHematol Oncol* 2004; 26:308-11
11. Ateser G, Yildiz O, Leblebici C, Mandel NM, Unal F, Turna H, et al: Metastatic primitive neuroectodermal tumor of the ovary in pregnancy. *IntJ Gynecol Cancer* 2007; 17:266-9.
12. Taylor HB, Helwig EB. Dermatofibrosarcoma protuberans: a study of 115 cases. *Cancer* 1962;15:717-25.
13. Goyal P, Agrawal D, Sehgal S, Ghosh S, Kumar A, Singh S. Aggressive angiomyxoma in pregnancy. *Rare Tumors* 2014;6:63-4.
14. Albrektsen G, Heuch E, Tretli S, Kvale G. Is the risk of cancer of the corpus uteri reduced by a recent pregnancy? *Int J Cancer* 1995; 61: 485-90.
15. Sahel JA, Earle JD, Albert DM. Intraocular melanoma. In: DeVita VT, Hellman S, Rosenberg SA, (eds.) *Cancer principles and practice of oncology*. Philadelphia: Lippincott, 1993: 1662-78.
16. Nieminen V, Remes N. Malignancy during pregnancy. *ActaObstetGynecolScand* 1970; 49: 315-8.
17. Merimsky O, Le Chevalier T, Missenard G, Lepechoux C, Cojean-Zelek I, Mesurolle B, et al. Management of cancer in Pregnancy: A case of Ewing's sarcoma of the pelvis in the third trimester. *Ann Oncol*. 1999;10:345-50.

