

Incidentally detected renal mass: what is your diagnosis?

Anikode Subramanian Ramaswamy*, Prashant B Mahalingashetti, Venugopal Sandeep Srinivas

Department of Pathology, PES Institute of Medical Sciences and Research, Kuppam, India

Keywords: Renal mass, Histopathology, metanephric adenoma.

Dear Sir,

A 30 year old female presented to the urology clinic with complaints of right sided flank pain. On radiological investigation, a single well circumscribed lesion measuring 1.5cm in diameter was noted in the upper pole of the right kidney. The mass was surgically excised and submitted for histopathological examination. The mass was fleshy grey white, soft and was devoid of any hemorrhagic or necrotic areas. Microscopy showed a well circumscribed, non-capsulated lesion in the kidney (Fig 1). Lesion was composed of highly cellular tumor showing tightly packed small, uniform, round acini with small lumina. The tumor cells were small, monotonous, with small uniform nuclei. The nuclei were round to oval, with fine delicate chromatin and showing occasional nuclear grooves. The nucleoli were inconspicuous. The cytoplasm of these cells was pale staining. No mitotic activity or necrosis was discernible. The stroma was inconspicuous (Fig 2). What is your diagnosis?

***Corresponding author:**

Dr. A S Ramaswamy: 52, Vignesh Nilayam, 11th Cross, T C Palya, K R Puram, Bangalore 560036 (India)
E-mail: dr_asr@rediffmail.com; Phone : +91-9493726494

Date of Submission: Aug 25, 2014 Date of Acceptance: Sept 9, 2014 Date of Publishing: Sept 28, 2014

How to cite this paper:

Ramaswamy AS, Mahalingashetti PB, Srinivas VS. Incidentally detected renal mass: what is your diagnosis? Annals of Pathology and Laboratory Medicine. 2014;1(2):I1-I4.

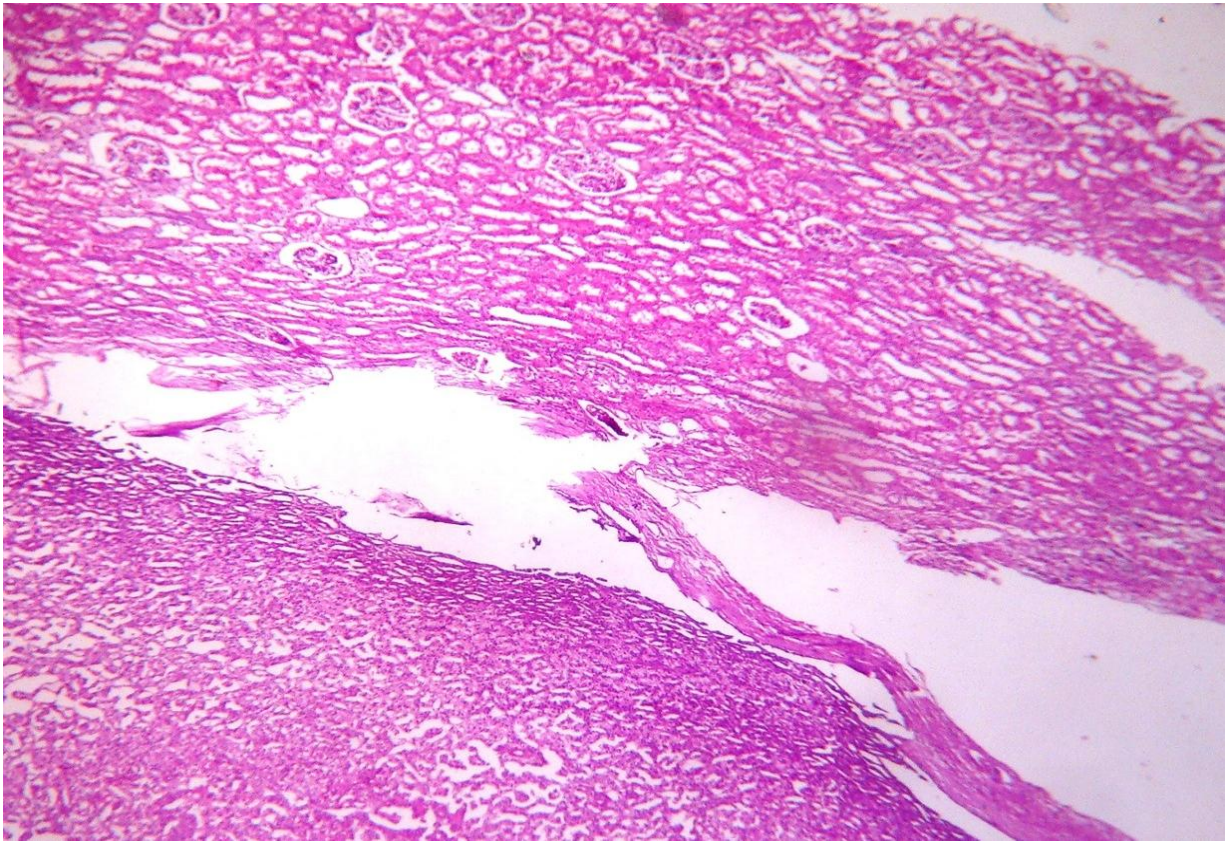


Figure 1: Well circumscribed tumor abutting the adjacent normal kidney. (H&E. 10x)

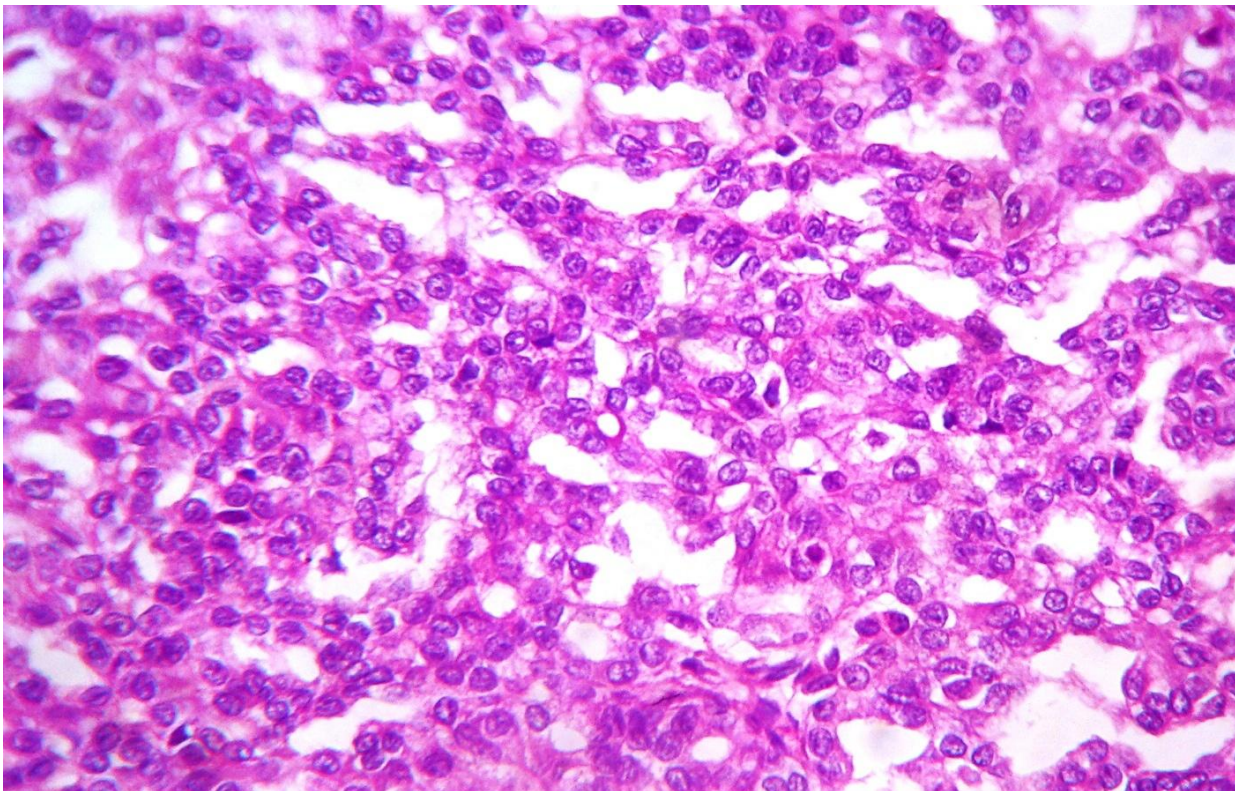


Figure 2: Tumor showing closely packed tumor cells in acinar pattern with bland nuclear features. (H&E. 40x)

What is your Diagnosis?

METANEPHRIC ADENOMA

It is a rare neoplasm. Although noted in the younger age group, this lesion is most commonly noted in the fifth and sixth decades with a 2:1 female preponderance. Most of these tumors are incidentally detected while others present with flank pain, hematuria, polycythemia etc. they range widely in size with most lesions measuring less than 1cm. They are well circumscribed; unencapsulated tumors which are grey white, soft to firm in consistency. Hemorrhage and necrosis is usually seen in larger tumors, while calcification may be seen in few cases.^[1,2]

Histological, these tumors are seen sharply abutting the kidney without an intervening capsule. They are typically composed of small epithelial cells forming small acini which are tightly packed. Glomeruloid bodies, angulated tubules and microcystic growth patterns are also observed in this tumor. The cells have scant pale staining light pink or basophilic cytoplasm. The nuclei are slightly larger than lymphocytes, uniform, round to oval with delicate chromatin. Nucleoli are inconspicuous and occasional nuclear grooves can also be seen. Mitotic activity is rare. The stroma is generally scant. At times it can be edematous, loose or myxoid. Hyalinised scar and osseous metaplasia may also be seen. Psammomatous calcification at times may be prominent. The immunohistochemical profile is variable with positive reactions noted to cytokeratin 7, vimentin, EMA, WT1 and CD57.^[1,3]

This tumor has to be distinguished from nephrogenic rests, Wilms tumor, renal cell carcinoma and metastatic cancers. Nephrogenic rests do not form mass lesions. Wilms tumor is usually multinodular. Both nephrogenic rests and Wilms tumor have blastemal component which is absent in metanephric adenoma. Cytological atypia and mitotic activity are not a feature either of metanephric adenoma. Papillary renal cell carcinomas have fibrovascular cores with macrophages and hemosiderin accumu-

lation. This is not evident in metanephric adenoma. Metastatic papillary carcinoma of lung or thyroid may pose occasional diagnostic challenge. TTF1 immunohistochemistry may be useful in such a situation.^[3,4]

Most metanephric adenomas have a favorable clinical outcome with simple enucleation or partial nephrectomy.^[1,5]

Acknowledgements

None

Funding

None.

Competing Interests

None declared.

References

1. Kuroda N, Toi M, Hiroi M, Enzan H. Review of metanephric adenoma of the kidney with focus on clinical and pathological aspects. *Histol Histopathol* 2003; 18:253-7
2. Lai Y, Chen D, Xu X, Yu Z, Ni L, Yang S et al. Metanephric adenoma: a report of two cases and review of the literature. *Molecular and Clinical Oncology* 2013; 1:1087-9
3. Algaba F. Renal adenomas: pathological differential diagnosis with malignant tumors. *Adv Urol*. 2008;2008:974848
4. Pins MR, Jones EC, Martul V, Kamat BR, Umlas J, Renshaw AA. Metanephric adenoma like tumors of the kidney. Report of 3 malignancies with discriminating features. *Arch Pathol Lab Med*. 1999;123:415-20.
5. Sharma PK, Tiwari P, Singh JP, Bera MK. Metanephric adenoma: a case report and review of the literature. *Saudi J Kidney Dis Transpl* 2013;24:1027-30.



This work is licensed under the Creative Commons Attribution International License (CC BY).