

## A Rare Case of Filariasis Presenting as An Abscess

Richa Bhartiya<sup>1\*</sup>, Nawanita Kumari<sup>2</sup>, Kumar Rajnish<sup>2</sup> and Pallavi Agrawal<sup>2</sup>

<sup>1</sup>Department of Pathology, Grant Government Medical College, Mumbai (Maharashtra) India

<sup>2</sup>Department of Pathology, Patna Medical College & Hospital (PMCH), Patna (Bihar) India

### ABSTRACT

Filariasis is a major public health problem in tropical countries including India. Filariasis is transmitted by the bite of culex mosquitoes. The diagnosis is conventionally made by demonstrating microfilaria in the peripheral blood smear. Microfilaria has been incidentally detected in FNAC smears from various sites. However, the presence of filarial worm in breast aspirate is unusual. We report a case of lactating female with breast lump presenting as tender subcutaneous nodule, clinically mimicking as a breast abscess, which on aspiration cytology revealed presence of numerous microfilaria in the background of inflammatory cells.

**Keywords:** Cytology, Malignant, Lymphatics, Endemic, Breast Abscess.

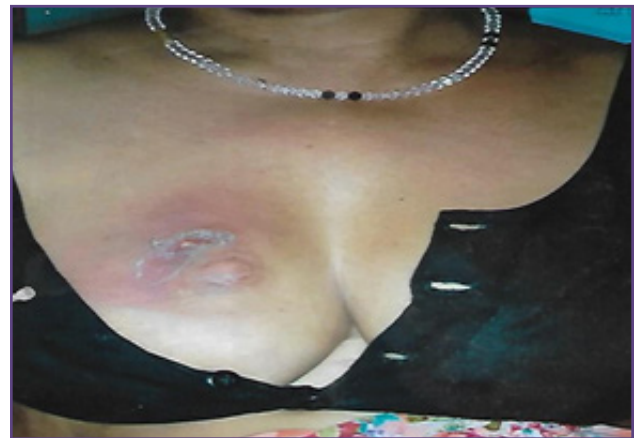### Introduction

Filariasis is a global problem. It is a major social and economic scourge in the tropics and subtropics of Africa, Asia, Western Pacific and parts of the Americas, affecting over 73 countries. More than 1.4 billion people live in areas where there is a risk of infection, of whom 120 million are infected and in need of treatment, including 40 million people with overt disease. The disease is endemic all over India with heavily infected areas are found in UP, Bihar, Jharkhand, Andhra Pradesh, Odisha, Tamilnadu, Kerala & Gujarat.<sup>[1]</sup> An estimated 600 million people are at a risk of lymphatic filariasis in India. Filariasis in India is caused by two closely related nematode worms namely *Wuchereria bancrofti* and *B. malayi*. About 90% of cases of lymphatic filariasis are caused by infection with *W. bancrofti* and rest by *B. malayi* in Southeast Asia.<sup>[2]</sup>

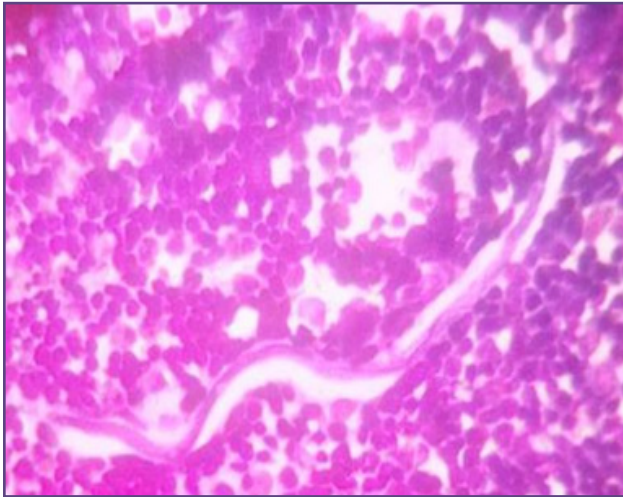
### Case Report

A 25-year old lactating female presented with a painful subcutaneous nodule in her right breast since 8 days for which she stopped breast-feeding. The swelling was slowly growing in size & there was history of fever with malaise. There was no history of cough, weight loss, trauma or nipple discharge. There was no family history of breast carcinoma. On examination, there was a firm, discrete, tender 2x2 cm nodule in the upper and inner quadrant of right breast. Overlying skin was erythematous. There was no axillary lymphadenopathy on either side. The opposite breast was normal. On laboratory work-up, routine examination of blood revealed haemogram with Haemoglobin 10.5 gm%, increased total leucocyte count. The ESR was within normal limits. With this impression, the clinical diagnosis of breast abscess or Galactocele was made & FNAC was advised. Patient consent was taken & FNAC

was performed by using 23 gauge needle & 10 ml syringe under aseptic conditions. Aspirate yielded pus, air-dried and wet-fixed smears were prepared. Smears were stained with Giemsa and Ziehl-Neelsen (Z-N) Stain for acid-fast bacilli. The smears revealed microfilaria surrounded by dense inflammatory cell-infiltrate comprising of neutrophil, eosinophil, lymphocyte, etc. The microfilaria was identified as those of *Wuchereria bancrofti* by the presence of a hyaline sheath, the length of the cephalic space, and the presence of somatic cells (nuclei). The somatic cells appeared as granules that extended from the head to the tail, the tail tip was free of nuclei (Fig 1 & 2). A diagnosis of Filarial abscess of breast was made. Z-N stain smears revealed no Acid-fast bacilli. Subsequently, night samples of peripheral blood smear were obtained which was negative for microfilaria. The patient received combination therapy of diethyl carbamazine citrate (DEC), amoxicillin clavulanic acid, albendazole and responded well.



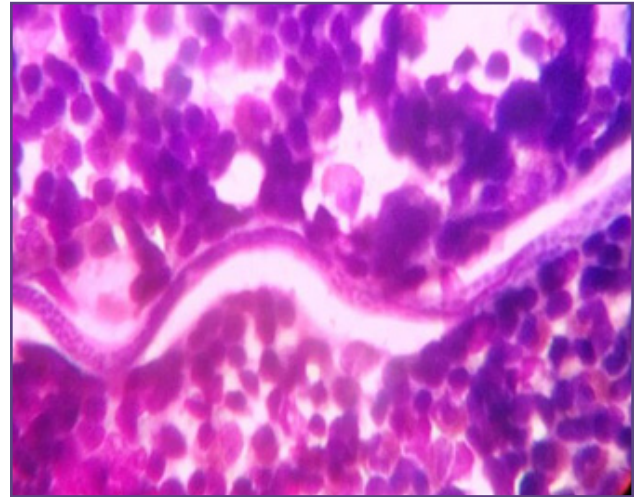
**Fig. 1:** Clinical image showing breast swelling with overlying erythematous skin.



**Fig. 2:** FNAC smear showing microfilaria in the background of degenerated inflammatory cells (Giemsa, x10).

### Discussion

Medical literature documents filariasis back to 600 BC by Sustruta who recognized the clinical manifestation of elephantiasis and referred it as elephantiasis arabicum.<sup>[3]</sup> Historically, the larval forms of the parasite were first found by Demarquay in 1863 in the hydrocele fluid of man. Later, in 1866, Waucheria found them in the Chylous urine and in 1872, Lewis found them in the human blood. In 1876, Bancrofti found the adult females, hence specific name was given after the discoverer. *Waucheria bancrofti* passes its life-cycle in two hosts, man & mosquito. In the lymphatic system of the man, the definitive host adult worms are harboured. *Microfilaria* are discharged which find their way into blood stream. There are eight species of *microfilaria* of which *W. bancrofti*, *B. Malayi* and *B. timori* are responsible for lymphatic filariasis. Of these, the first two are common in India *Microfilaria* in India display a nocturnal periodicity i.e. they appear in large numbers in night and retreat from bloodstream during the day. It is difficult to find *microfilaria* in blood and FNAC aspirate despite the high incidence of it in the endemic area. A majority of infected individuals in filarial endemic communities are asymptomatic. The disease manifestations range from none to both acute and chronic manifestations such as lymphangitis, lymphadenitis, elephantiasis of genitals, legs and arms. Diagnosis of filariasis is usually made by demonstration of *microfilaria* in peripheral blood or skin and detection of filarial antigen and antibody.<sup>[2]</sup> Adult worms can be detected in lymphatics, subcutaneous tissue, peritoneal & pleural cavities, heart, brain, scrotum and breast. There are various reports stating the presence of *microfilaria* using aspiration cytology in various sites like spermatic cord, epididymis, testis and retroperitoneum.



**Fig. 3:** FNAC smear showing microfilaria in the background of degenerated inflammatory cells (Giemsa, x40).

Despite high incidence of filariasis, *microfilaria* in fine needle aspiration cytology of breast lump is not a common finding. Moreover, female breast is an unusual site for occurrence of filarial nodule, especially in lactating one and only few such cases on FNAC, have been reported. The patient usually presents with solitary, non-tender, painless and unilateral breast lump, whereas in our case patient presented with tender painful breast-nodule.<sup>[4,5,6]</sup> The upper and outer quadrant is the most common site<sup>[6,7]</sup> but central or periareolar nodules can also occur.<sup>[8]</sup> Sometimes, skin over the nodule may be hyperemic with changes of paeu d'orange and the axillary nodes may be enlarged.<sup>[9]</sup> Some other parasite infections like cysticercosis, schistosomiasis may also be present as lumps in the breast and are often clinically thought to be malignant.<sup>[10]</sup> In case of filariasis, the host tissue immune response is variable ranging from only minimal reaction to dense inflammatory cell infiltration comprising especially of eosinophils.<sup>[8]</sup> In our case, there was dense inflammatory reactions in smears comprising of neutrophils & eosinophils. Severe inflammatory reaction may be induced due to the restricted movement of adult worm in the form of eosinophilia, eosinophilic abscess, neutrophilic abscess, necrosis and epitheloid cell granuloma.<sup>[11]</sup> Cell adherence to *microfilaria* is explained by the presence of filarial antibodies [IgE] in the sera of the patient. Thus diagnosis of breast filariasis is solely made on the demonstration of adult worm and *microfilaria*.<sup>[12]</sup> In our case, *microfilaria* was found in cytology aspirate of breast lump of a lactating female presenting as abscess whereas it was not detected in peripheral blood smear and patient responded well to the DEC therapy. Lymphatic filariasis is targeted for elimination in India through mass drug administration (MDA) with DEC combines with

albendazole (ABZ). It has been hypothesized that intestinal helminthes could play a role in the survival and persistence of lymphatic-dwelling filarial parasite. The response of adult worms to DEC is variable in different patients and even in the same patient different adult worms show varying response.

### Conclusion

Demonstration and identification of the parasite in cytological smears plays a significant role in the prompt recognition of disease and institution of specific treatment. In countries like ours, where lymphatic filariasis is endemic, it should be considered in the differential diagnosis. This highlights the importance of screening of the smears for parasites even in the cases with absence of clinical indications.

### Reference

1. Park K. epidemiology of communicable diseases. In: Textbook of Preventive and Social Medicine. 23rd ed Jabalpur: Banarasidas Bhanot Publishers, 2015, 270-276.
2. Patrikar A, Maimoon S, Mahore S. Filarial granuloma in breast. *Indian J Pathol Microbiol* 2008, 51:85-6.
3. Faust EC, Russell PF, Jung Rc. Plasmid Nematode, Parasites of Man. Filariodea. In: Craig and Faust's Clinical Parasitology. 8th ed. Philedelphia, PA: Lea and Febiger, 1970:361-404.
4. Rukmangandha N, Shanthi V, Kiran CM, Nalini PK, Sarella JB. Breast filariasis diagnosed by fine needle aspiration cytology – a case report. *Indian J Pathol Microbiol* 2006; 49:243-4.
5. Kapila K and Verma K. Gravid adult female worms of *Wuchereria bancrofti* in fine needle aspirates of soft tissue swellings. Report of three cases. *Acta Cytol* 1989; 33:390-2.
6. Hippargi SB, Kittur SK, Yelikar BR. Filariasis of the breast, diagnosed on fine needle aspiration cytology. *J Cytol* 2007; 24:103-4.
7. Upadhyaya V, Upadhyaya DN, Sarkar S. An interesting case of breast filariasis. *Indian J Radiol Imaging* 2006; 16:915-7.
8. Pant I, Singh PN, Singh SN. Filariasis of breast – a report of two cases, an unusual site to be involved. *J Cytol.* 2003; 20:206-7.
9. Lahiri VL. Microfilariae in nipple secretion. *Acta Cytol* 1975;19:154-5.
10. Sahai K, Kapila K, Verma K. Parasites in fine needle breast aspirates – assessment of host tissue response. *Postgrad Med J* 2002; 78:165-7.
11. Haleem A, Al Juboury M, Al Hussein H. Filariasis: A report of three cases. *Ann Saudi Med.* 2002;22:77–9
12. Chakrabarti I, Das V, Halder B, Giri A. Adult filarial worm in aspirate from a breast lump mimicking fibroadenosis. *Trop Parasito* 2011; 1:129-31.

#### \*Corresponding author:

**Dr. Richa Bhartiya**, C/o Shri Vinay Kumar Shrivastava, Flat No. B-23, Badhwar Park Railway Officers' Residences, Captain Prakash Pethe Marg, Colaba, Mumbai – 400008 (Maharashtra) India  
**Email:** richabhartiya1972@gmail.com

**Financial or other Competing Interests:** None.