

Gastrointestinal Lipoma Presenting as Colonic Intussuception: Report of Two Cases

Pranita Medhi¹, Mahak Sharma¹, Manjusha Biswas²

¹Department of Pathology, Assam Medical College and Hospital, Dibrugarh, Assam

²Department of Pathology, Nightingale Hospital, Kolkatta

Keywords: Lipoma, Gastrointestinal, Benign, Obstruction.

ABSTRACT

Lipomas are benign mesenchymal tumors of adipose tissue, though common at other sites, are rare in GIT. Most gastrointestinal lipomas are located in the colon, ileum and jejunum, are rarely responsible for clinical symptoms and are usually detected incidentally at colonoscopy. We present two such cases of large colonic lipomas. One is a 38-years old female presenting with complaint of loose stool and sessile mass in transverse colon on colonoscopy, suspected to be a malignant lesion. The other is a 40 years old female presenting with acute abdomen, colonoscopy revealed a submucosal mass in descending colon. Both underwent resection of mass, and histologically were revealed to be lipomas of colon. Colonic lipomas, although unusual, continue to present difficulties in the preoperative differentiation between malignant and benign colonic neoplasm. Two cases of colonic lipomas are reported.

***Corresponding author:**

Dr. Pranita Medhi, Assam Medical College campus, Flat No. 7, M Lane, Dibrugarh, Assam, India

Phone: +91-9435131011

E-mail: pranita_medhi@yahoo.co.in



Introduction

Lipomas are benign mesenchymal tumors derived from mature adipocytes. They are known to occur throughout the gastro intestinal tract, with colon having the highest incidence. The reported incidence of colonic lipomas ranges from 0.2% to 4.4%^[1] with most of them presenting in the sixth decade.^[2] Lipomas of the large intestine are most commonly seen (in order of decreasing frequency) in the caecum, ascending colon and sigmoid colon. Approximately 90% of colonic lipomas are submucosal in location.^[2] Colonic lipomas are generally asymptomatic and incidentally found but occasionally may present with intermittent crampy abdominal pain secondary to intussusception of a pedunculated lipoma or with intermittent fresh rectal bleeding.^[3] Symptoms correlate with the size of the tumor, with giant ones (>4cm) often being symptomatic.^[4] They may vary in size from several millimeters to 30 cm and are usually well-delineated, soft, ovoid, yellowish masses. They can occur as solitary lesion or sometimes may be found in groups, and they can be sessile or pedunculated.^[5,6] Multiple intestinal lipomas (lipomatous polyposis) are quite rare. The diagnosis is usually made by colonoscopy associated with biopsies and Abdominal CT scan for the assesment of the tumoral extension. Recently endoscopic ultrasound has shown high pre-operative diagnostic accuracy for gastrointestinal lipomas (93.8%).^[7] Microscopically, they contain mature adipose tissue and usually have a thick capsule surrounding the tumour. Secondary cellular changes can include nuclear hypertrophy, hyperchromasia and pleomorphism and fat necrosis. These changes if extensive can mimic a liposarcoma; however, frank liposarcoma of the colon is extremely rare and requires the presence of lipoblasts.^[8] The treatment depends essentially on the clinical picture, on the size and location of the lipoma and involves endoscopic or surgical excision.

Case Reports

We report two cases of large colonic lipomas coming to the Department of Pathology, Assam Medical College and Hospital.

Case one: A 38 year old female presented with pain lower abdomen and passage of loose stools on and off. Colonoscopic examination showed a sessile mass in the transverse colon which was suspicious of malignancy. Intraoperatively, she was found to have intussusception of the ascending colon into the transverse colon. Intussusception was reduced followed by wide excision of the mass with surrounding colon, resection anastomosis was done and sent for histopathological examination.

Case two: A 40 year old female presented with acute pain abdomen in emergency, without any prior significant

history of bowel disturbances. Colonoscopy revealed a protruding submucosal mass in the lumen of descending colon along with intussusception. Patient underwent emergency surgery with resection-anastomosis and the specimen was sent for histopathological examination.

Grossly, both cases showed presence of very well circumscribed, round, 4x5 cm [figure1] and 4x4.5cm, soft, homogeneous mass obstructing the whole of the colonic lumen. Surrounding mucosal tissue did not reveal any significant macroscopic pathology. On histopathological examination, both cases were diagnosed as submucosal lipoma [figure 2] consisting of well differentiated adipose tissue with fibrous capsule. Surrounding colonic tissue showed mucosal glandular hyperplasia, but no evidence of malignancy was noted in both the cases. Both the cases had uneventful post-operative recovery and patients are doing well on follow-up.

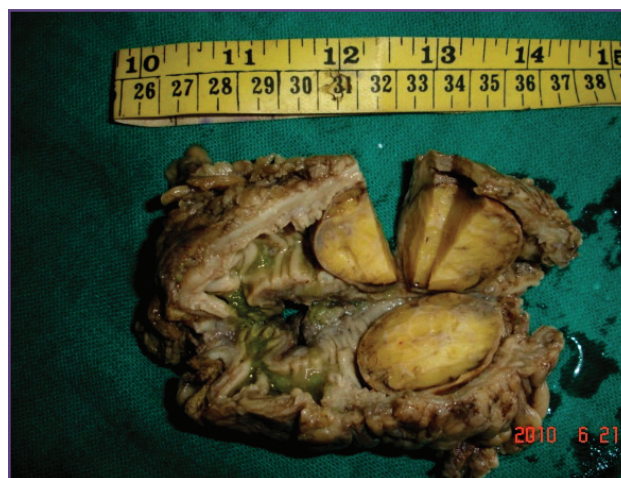

Fig. 1: Gross morphology (case 1), showing well circumscribed intraluminal mass.

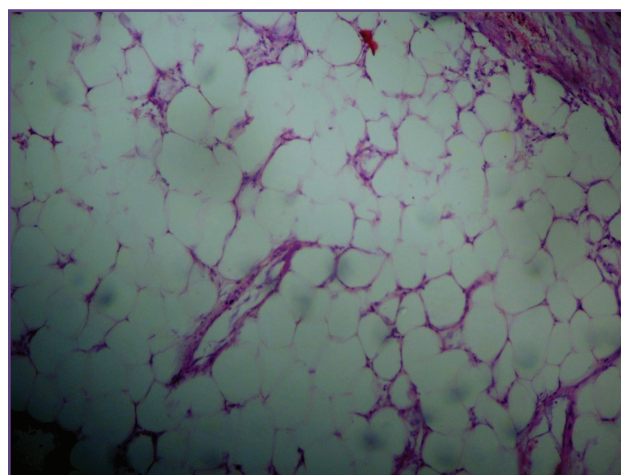


Fig. 2: photomicrograph of gastrointestinal submucosal lipoma

Discussion

Lipomas of the gastrointestinal tract are benign tumours and were first reported by Bauer in 1757.^[9] Although colonic lipomas are the most common type of mesenchymal neoplasm of the gastrointestinal tract, they are rare benign tumors.^[6] The rarity of these tumors and lack of specific symptoms and signs often poses a diagnostic challenge. To further complicate the issue, similarity in age of presentation and symptoms of colonic lipomas often make them close mimics of malignancy.

Among the preoperative investigations, barium enema may demonstrate a filling defect, with a lobulated appearance, which is however a nonspecific finding.^[9] In colonoscopy, three signs may contribute to the diagnosis: the “cushion sign” (probing the polyp with a closed biopsy forceps will often yield a pillow-like indentation), the “tenting effect” (grasping the overlying mucosa with biopsy forceps presents a tent-like appearance), and the “naked fat sign” (biopsies may result in an extrusion of yellowish fat).^[10] Thus, colonoscopy and other diagnostic modalities often fail to give a confirmative diagnosis and suspicion of malignancy always remains. Mucosal biopsies are most often superficial and thus unhelpful. Biopsy by colonoscopy is not recommended in patients suspected of having a lipoma because the lesion is beneath the normal mucosa and because a biopsy often cannot promote a diagnosis or completely exclude the possibility of malignancy. The exact diagnosis still mainly relies on an intra or postoperative pathology examination. A patient with an asymptomatic colonic lipoma with a size smaller than 2cm needs regular follow-up, but a resection is unnecessary. A symptomatic lipoma or asymptomatic lipoma larger than 2cm in size should be considered for resection by endoscopic removal or surgical resection.^[11]

The present cases revealed that large colonic lipomas and malignant tumors may be difficult to differentiate prior to resection if only endoscopic observations are used.

Both our cases also showed intussusception, however colonic intussusceptions is an uncommon complication of colonic lipoma.^[12]

Thereby, endoscopists, radiologists and pathologists need to be aware of this entity. Careful discussion and review of the investigations may permit a preoperative diagnosis.

Conclusion

Lipomas of the colon are rare but clinically important conditions that require suitable evaluation for guiding appropriate therapy. Difficulties in preoperative differentiation between benign and malignant tumour may arise due to obstructive symptoms and irregular rectal bleeding often leading to radical surgery. To rule out malignant lesion and avoid extensive surgical procedures, adequate biopsy or intraoperative frozen section is necessary.

Acknowledgements

Acknowledging the roles of various technical staff who helped in preparing the histopathological slides in the Department of Pathology and also Dr. Gunabhi Das, the surgeon who operated the case.

Funding

None

Competing Interests

None Declared

Reference

1. Vecchio R, Ferrara M, Mosca F, Ignoto A, Latteri F. Lipomas of the large bowel. *Eur J Surg*. 1996;162:915-9.
2. Geetha Nallamotheu, Douglas G. Adler. Large Colonic Lipomas. *Gastroenterology & Hepatology* 2011;7:490-2.
3. Marra B. Intestinal occlusion due to a colonic lipoma. Apropos 2 cases. *Minerva Chir*. 1993; 48:1035-9.
4. Bahadursingh AM, Robbins PL, Longo WE. Giant submucosal sigmoid colon lipoma. *Am J Surg*. 2003;186:81-82.
5. Zhang H, Cong JC, Chen CS, Qiao L, Liu EQ. Submucous colon lipoma: a case report and review of the literature. *World J Gastroenterol*. 2005;11:3167-9.
6. Bardají M, Roset F, Camps R, Sant F, Fernández-Layos MJ. Symptomatic colonic lipoma: differential diagnosis of large bowel tumors. *Int J Colorectal Dis*. 1998;13:1-2
7. Zhang YQ, Yao LQ, Qin XY, Zhou PH, Xu MD, Hou YY. Diagnosis and treatment of gastrointestinal lipoma. *Zhonghua Wei Chang Wai Ke Za Zhi*. 2007;10:512-4.
8. Coyne PE, Teemul T, Dent B, Henderson D, Crabbe R, Garud T. *JSCR*. 2011 2:4

9. Ryan J, Martin JE, Pollock DJ. Fatty tumours of the large intestine: a clinicopathological review of 13 cases. *Br J Surg.* 1989;76:793–796.
10. De Beer RA, Shinya H. Colonic lipomas: an endoscopic analysis. *Gastrointest Endosc.* 1975;22:90–91.
11. Seung-Jin Kwag, Sang-Kyung Choi, Eun-Jung Jung, Chi-Young Jung, Sang-Ho Jung, Tae-Jin Park, and Young-Tae Ju. Surgical Strategy for Colonic Intussusception Caused by a Giant Colonic Lipoma: A Report of Two Cases and a Review of the Literature. *Ann Coloproctol.* Jun 2014; 30: 147-50.
12. Zhou XC, Hu KQ, Jiang Y. A 4-cm lipoma of the transverse colon causing colonic intussusception: A case report and literature review. [Oncol Lett.](#) 2014;8:1090-2.