

## Progressive Transformation of Germinal Centers: A Mimicker of Lymphoma

Sumaya, Meena N Jadhav\*, Rashmi K Patil and Shreekant K Kittur

Dept. of Pathology, Belagavi Institute of Medical Sciences, Belagavi, India

### ABSTRACT

Progressive transformation of germinal centers. Reactive follicular hyperplasia. PTGC is a clinically asymptomatic condition characterised by persistent lymphadenopathy. PTGC may occur before, concurrently with or after the onset of nodular lymphocyte predominant Hodgkin's lymphoma (NLPHL). It may also be confused for follicular lymphoma and mantle zone lymphoma. We report an interesting case of PTGC in a 23year female with swelling in the left side of neck of one year duration. Histology revealed PTGC, which was confirmed by immunohistochemistry which showed CD3+, CD20+ in appropriate B and T cell region and negative for CD15, CD30 and bcl-2. As PTGC mimics lymphoma, it should be followed up carefully.

**Keywords:** Follicular Lymphoma, Hodgkin's Lymphoma, Lymph Node, Progressive Transformation of Germinal Centers.

### Introduction

Progressive transformation of germinal centers (PTGC) is an uncommon variant of non-specific reactive follicular hyperplasia in which some follicles undergo marked enlargement which are predominantly composed of small lymphocytes. Most commonly it is an isolated, self limiting reactive process.<sup>[1]</sup> PTGC may occur before, concurrently with or after the onset of nodular lymphocyte predominant Hodgkin's lymphoma (NLPHL). It may also be confused for follicular lymphoma and mantle zone lymphoma.<sup>[1-7]</sup>

### Case History

A 23 year old female presented with history of swelling in the left side of neck of one year duration. There was no history of pain in the swelling. There was no history of fever, weight loss and loss of appetite. On examination the swelling was present in the left side of the neck below the mandible measuring 6 x 4cm, spherical, nontender, mobile and soft in consistency. Skin over swelling was normal. Per abdominal examination revealed hepatomegaly. There was no splenomegaly. Respiratory and cardiovascular systems were unremarkable.

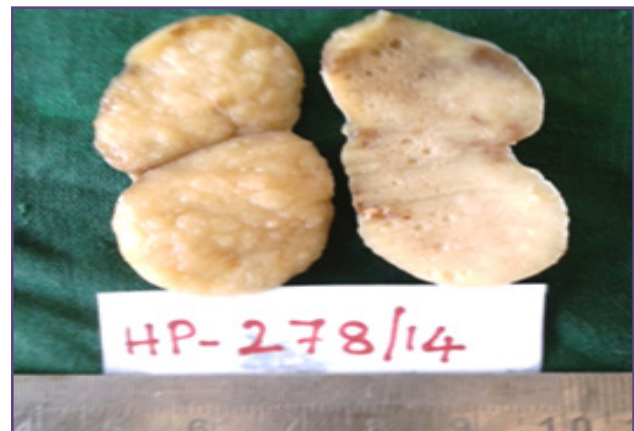
All the haematological parameters were unremarkable. Serological tests for HIV I&II antibodies and HbsAg were negative. FNAC of the swelling revealed features of reactive hyperplasia. She was advised for lymph node excision.

Excision of lymph node biopsy was done and sent for histopathological examination. The excised specimen of lymph node measured 6x2.5x2cm with solid, pale yellow, nodular cut surface (Figure:1).

Microscopy showed lymph node with intact capsule with underlying lymphoid follicles of varying sizes with

prominent germinal centers. At places these follicles were markedly enlarged and partially replaced the lymph node architecture. These follicles were infiltrated by round, regular small lymphocytes blurring mantle zone margins. Interfollicular areas showed congestion. There were no granulomas, Reed Sternberg cells, tingible body macrophages or atypical mitosis seen (Figure:2A,2B &2C). Ziehl-Neelsen stain for acid fast bacilli was negative. Reticulin stain showed normal reticulin meshwork around the large nodules (Figure:2D)

Figure 2: Microphotograph showing large, dark staining nodules in a background of reactive follicular hyperplasia (H & E X 4, Fig 2A ) and nodules with blurred mantle zone margin (H & E X 100, Fig 2B). Nodule composed of round, regular small lymphocytes (H & E X 400, Fig 2C) Reticulin stain showing normal reticulin meshwork around large nodules (X100, Fig 2D)



**Fig. 1:** Gross photograph of lymph node showing solid, pale yellow, nodular cut surface.

It was confirmed by immunohistochemistry, which showed CD3+, CD20+ in appropriate B and T cell region(Figure: 3A&3B) and negative for CD30, CD15 and bcl-2(Figure:3C,3D & 3E ). She is under follow up and to date doing well.

### Discussion:

PTGC, a rare benign reaction pattern in lymph nodes was first described by Muller-Hermelink and Lennert in 1975.<sup>[1,4,5]</sup> The disease occurs in 3.5%-10% of reactive lymph node with chronic non-specific lymphadenitis.<sup>[1-2]</sup>

PTGC occurs, particularly in young males in their second to third decade of life, characterized by persistent or recurrent asymptomatic lymphadenopathy. It commonly involves cervical lymph node followed by axillary and inguinal lymph node.<sup>[1, 3-6]</sup> PTGC is also seen in children in 20% of cases and rare in patients with HIV infection. Persistent or recurring PTGC can occur in paediatric cases, usually located in same lymph node.<sup>[1,4,6]</sup>

Pathologically it is associated with follicular hyperplasia and characterized by loss of defined border between germinal center and lymphocytes of mantle zone, which expand and replace germinal center. Here lymph node architecture is preserved in contrast to Hodgkin's disease.<sup>[11]</sup>

The etiology and pathogenesis of PTGC remains unknown. There are various theories to explain its pathogenesis. It is proposed to be a pre-neoplastic stage of nodular lymphocyte predominant lymphoma (NLPHL) and premature arrest at an early transition stage between primary and secondary follicles because of incomplete blastic transformation of B cells.<sup>[4]</sup>

According to few studies PTGC is thought to result from antigenic stimulation during immunologic conditions.<sup>[5,11]</sup> In view of Rosai PTGC is the morphological expression of distinct type of follicular hyperplasia, seen in conjunction with Hodgkin's disease.<sup>[7]</sup>

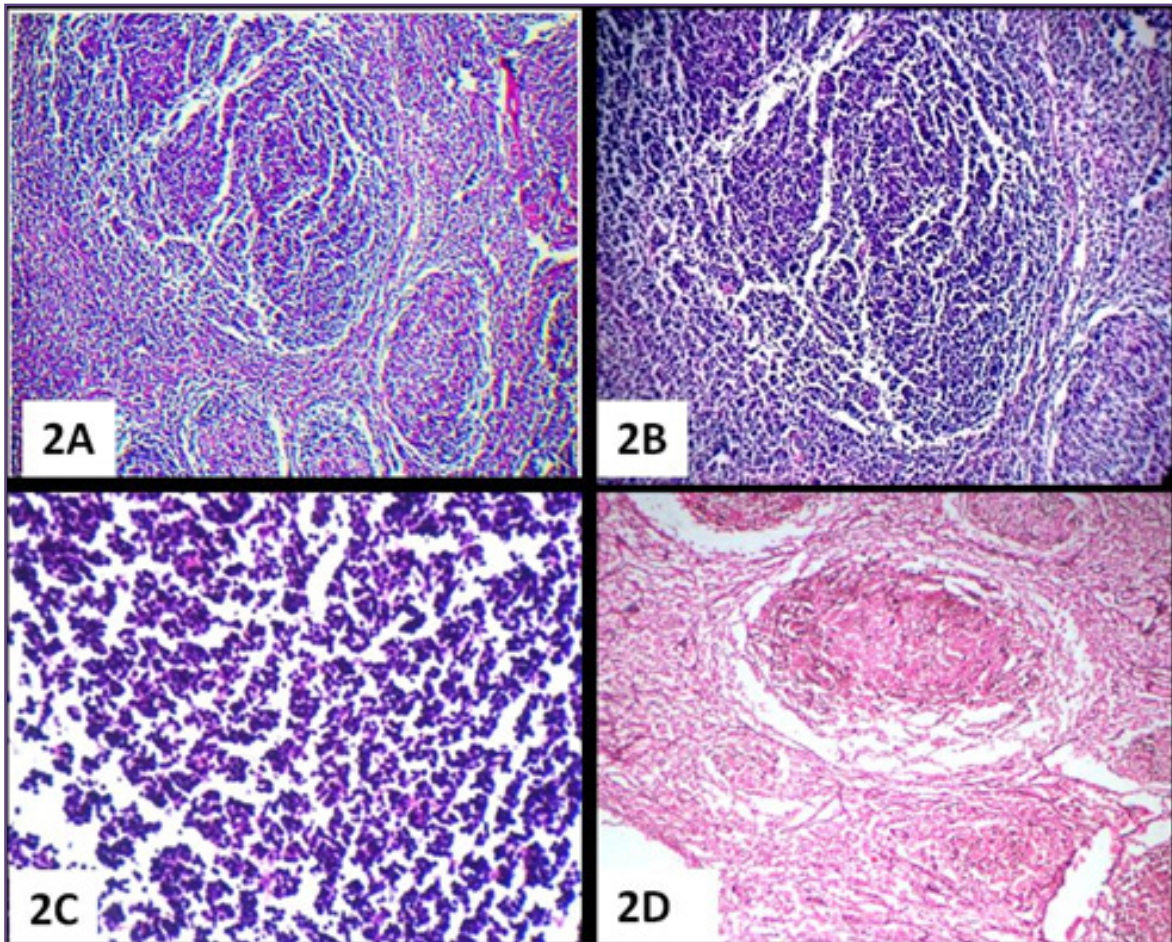
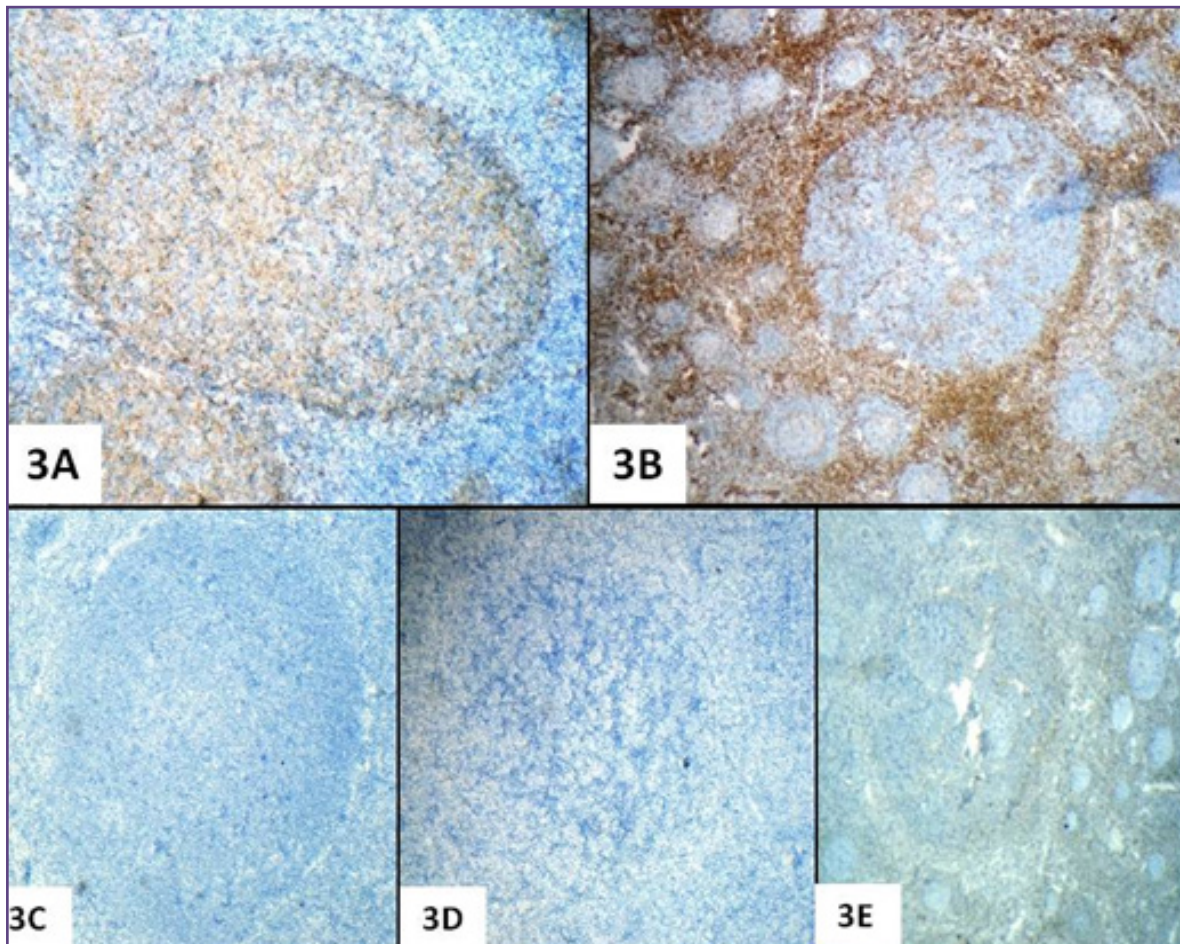


Fig. 2: Microphotograph showing large, dark staining nodules in a background of reactive follicular hyperplasia (H & E X 4, Fig 2A ) and nodules with blurred mantle zone margin( H & E X 100, Fig 2B). Nodule composed of round, regular small lymphocytes(H & E X 400, Fig 2C)Reticulium stain showing normal reticulium meshwork around large nodules (X100, Fig 2D).



**Fig. 3: Microphotograph showing the lymphoid cells positive for CD20 & CD3 in appropriate B & T cell region ( IHC X 100, Fig 3A & 3B ) and negative for CD15, CD30 & bcl-2 ( IHC X 100 Fig 3C, 3D & 3E).**

About 35% of patients with PTGC will have history of NLPHL which may coexist or precede or follow with diagnosis of PTGC and only 2% with nodular sclerosis or mixed cellularity Hodgkin's disease.<sup>[4,5]</sup> The relationship between NLPHL and PTGC seems to be logical as both lesions develop in B-zone of lymph node where as mixed cellularity and nodular sclerosis type of Hodgkin's disease arise from T-cell region of lymph node.<sup>[5]</sup>

PTGC is morphologically and immunologically similar to NLPHL except L & H cell, Hodgkin's cell and Reed-Sternberg cells which occurs in NLPHL. So, diagnosis between the PTGC and NLPHL is at times difficult. However NLPHL shows less well circumscribed nodules and broken-up pattern and greater number of T cell aggregates around L & H cells.<sup>[2]</sup> NLPHL also shows chromosome aberration, dissemination and transformation into high grade lymphoma.<sup>[5]</sup>

PTGC mimics floral variant of follicular lymphoma in 5% of cases. The distinction between floral variant of

follicular lymphoma and PTGC is based on pattern and cytologic characteristics. In follicular lymphomas, there are no normal reactive germinal centers where as in PTGC reactive germinal centers are present.<sup>[8]</sup> In the floral variant more than half of neoplastic follicles were surrounded by mantle zones that irregularly invaginates the follicle centers giving the appearance of PTGC. Here there will be condensation of reticulin fibers at the periphery of the follicle.<sup>[1,4,8,9]</sup>

Various low grade B cell lymphoma like nodal marginal zone B-cell lymphoma, small lymphocytic lymphoma and mantle cell lymphoma should also be considered as differential diagnosis to PTGC. These lymphomas arises from interfollicular area, surrounds the follicle completely by producing marginal zone pattern.<sup>[9]</sup>

IHC is of great value in differential diagnosis. Immunostain for CD3, CD20 are positive in PTGC in appropriate B and T cell regions and are negative for CD15, CD30, EMA which are positive in nodular lymphocyte predominant

Hodgkin's lymphoma. It is also negative for bcl-2 which is positive in follicular lymphoma.<sup>[10]</sup>

In case of PTGC lymph node may remain stable for many years or may transform into Hodgkin's lymphoma (2.5%) or regress spontaneously.<sup>[11]</sup>

In the present case, patient presented with chronic lymphadenopathy for the first time and complete excision was done. Microscopy showed PTGC without any concurrent NLPHL, which was confirmed on IHC and till date there is no evidence of recurrence.

### Conclusion

Watch and wait approach should remain the standard of care for patients with PTGC with a high level of awareness of the association with lymphomas. Persistent lymphadenopathy requires imaging and tissue diagnosis. So close follow up of the patient is mandatory to rule out Hodgkin's disease.

### Reference

1. Chang CC, Osipov V, Wheatson S, Tripp S, Perkins SL. Follicular hyperplasia, follicular lysis, and progressive transformation of germinal centers. A sequential spectrum of morphologic evolution in lymphoid hyperplasia. *Am J Clin Pathol.* 2003 Sep; 120(3):322-6.
2. Brauning A, Yang W, Wacker HH, Rajewsky K, Kuppers R, Hansmann ML. B-cell development in progressive transformed germinal centers: similarities and differences compared with classical germinal centers and lymphocytic-predominant Hodgkin disease. *Blood.* 2001 Feb 1; 97(3):714-9.
3. Sweetenham JW, Polliack A. Progressive transformation of germinal centers and Hodgkin lymphoma: more insights but may be more confusion? *Leukemia & Lymphoma* 2011; 52: 2041-2.
4. Ioachim HI, Medeiros LJ. *Ioachim's Lymph node pathology.* 4th eds Philadelphia: Lippincott Williams and Wilkins; 2009:186-9.
5. Hansmann ML, Fellbaum C, Hui PK, Moubayed P. Progressive transformation of germinal centers with or without association to Hodgkin's disease. *Am J Clin Pathol.* 1990;93:219-226.
6. Roca B, Roca M, Zaragoza M, Martinez T, Diaz D. A case of progressive transformation of germinal centers in an HIV- infected patient. *Austin journal of Microbiology;* 2015(2): 1-2.
7. Rosai J. *Rosai and Ackerman's Surgical Pathology.* 10th edition, St. Louis: Elsevier; 2015: 1888-9.
8. Barbara M, Osborne MD, Butler JJ. Follicular lymphoma mimicking Progressive transformation of germinal centers. *Am J Clin Pathol.* 1987;88(3):264-269.
9. Kojima M, Nakamura S, Motoori T, Itoh H, Shimizu K, Yamane N et al. Progressive transformation of germinal centers: A clinicopathological study of 42 Japanese patients. *International journal of surgical pathology.* 2003;11(2):101-107.
10. Smith LB. Nodular Lymphocyte Predominant Hodgkin Lymphoma Diagnostic pearls and pitfalls. *Arch Pathol Lab Med.* 2010;134:1434-1439.
11. Brown JR, Skarin AT. Clinical Mimics of Lymphoma. *The Oncologist* 2004;9:406-416.

#### \*Corresponding author:

**Dr. Meena N Jadhav**, CTS No 4842/A-6, Sadashiv Residency, Flat No S-04 11th cross Near Shivalaya temple Sadashiv Nagar, Belagavi-590001, India  
**Email:** Shubhamj2003@yahoo.co.in

**Financial or other Competing Interests:** None.