

A Clinicopathological Study of Immunobullous Diseases

Annu Elizabeth Prakash^{1*}, Jessy Mangalathu Mathai², Thundi Parampil Thankappan² and Gopalan Sulochana²

¹Sree Narayana Institute of Medical Sciences, India

²Pushpagiri Institute of Medical Sciences, India

ABSTRACT

Background: Immunobullous disorders are a group of disorders involving the formation of a fluid filled cavity within or beneath the epidermis, due to the presence of autoantibodies against adhesion molecules in epidermis and dermis. The clinical presentation and the microscopic features of different diseases belonging to this group vary greatly. This study was undertaken to describe the clinical features and the histopathological patterns of immunobullous diseases.

Method: 30 cases of immunobullous disorders who attended Dermatology Outpatient Department were included in the study. Relevant clinical details of these cases were collected and punch biopsies were taken from the site of lesion which were used for routine histopathology.

Results: Among the 30 cases included in our study, males were found to be more commonly affected than females. The most common immunobullous lesions encountered were Pemphigus Vulgaris(13/30) and Bullous Pemphigoid (10/30). In pemphigus group of diseases, patients presented with small cutaneous and oral vesicles. Pemphigus foliaceus patients showed cutaneous lesions only. Intraepidermal vesicles containing acantholytic cells and inflammatory cells were characteristic histological features of the Pemphigus group. Bullous pemphigoid lesions were large bullae on the limbs and within the oral cavity. Most of the cases of Bullous Pemphigoid showed the formation of subepidermal bullae predominantly containing eosinophils.

Conclusion: Both the clinical findings and the histological features are invaluable in arriving at a definite diagnosis in immunobullous diseases.

Keywords: Immunobullous Lesions, Pemphigus, Bullous Pemphigoid.

Introduction

Immunobullous disorders are dermatological disorders involving the formation of fluid filled skin blisters as a result of an immunological reaction against different epidermal antigens. Commonly prevalent immunobullous diseases belong to two broad categories- the pemphigus group and the bullous pemphigoid group. These diseases affect a wide age group though predominantly seen in the elderly. The lesions of the different diseases under this category vary in their clinical appearance and distribution. Histopathological examination, taken in conjunction with detailed clinical history, is sufficient to reach a definite diagnosis in majority of the cases. ^[1]

Immunobullous diseases can be categorised into intraepidermal and subepidermal based on the plane of epidermis in which the blister is present. Apart from the blister plane, the histopathological features essential in reaching a diagnosis include the nature of the inflammatory cell population and the mechanisms of blister formation.

The inflammatory cell population within the blister may vary with the type of lesion and its duration. The epidermal

keratinocytes are analysed for changes including acantholysis, spongiosis, cytolysis, reticular degeneration and basement membrane zone disruption by which blisters can be formed in the epidermis. Acantholytic keratinocytes are rounded in shape whereas spongiotic keratinocytes appear stellate. Ballooning degeneration leading to rupture and death of keratinocytes can cause reticular degeneration. Cellular and humoral mediated immune damage may result in basement membrane disruption.

This study was undertaken to study the clinical spectrum and histopathological characteristics of various immunobullous diseases.

Materials and Methods

The study protocol was cleared by the Scientific Review committee, following which it was approved by the Institutional Ethics Committee.

The patients were detailed about the purpose of the study and were included in it after obtaining an informed consent. Clinical history of the patient was collected in detail and clinical examination was done. The details collected included the following parameters- age and gender of the

patient, site and size of the lesions and the total duration of the disease.

Punch biopsy of 3-4 mm size was taken from the perilesional area. The biopsy specimen was fixed using 10% formalin and processed by passing it through ascending grades of alcohol, xylene and paraffin wax. Sections of 5 to 7 micron thickness were cut using a microtome, Haematoxylin & Eosin staining was done and the slides were examined under microscope. Various histopathological parameters including blister plane and the nature of inflammatory cells were noted.

Results

The study sample is constituted of 30 patients diagnosed clinically as cases of immunobullous disease attending the Dermatology Out Patient Department in the time period of one year. Clinical details were collected from these patients and the histopathological slides from the skin biopsies taken were studied.

More than half of the cases in the study (17/30), belonged to the pemphigus group of diseases. Pemphigus vulgaris is the most prevalent among these (13/17). The other diseases included in this group are pemphigus foliaceus and pemphigus erythematosus. Bullous pemphigoid accounted for 33.3% of the cases (10/30). Other bullous diseases included Bullous Lupus Erythematosus (Table 1).

The mean age of the patients included in our study is 57.7 years. The age range of Pemphigus vulgaris cases varied from 30 to 69 years, with a mean age of 52.7 years. Mean age among males was 52.3 years and among females it was 53.4 years. The age range of Pemphigus foliaceus cases was from 51 to 71 years with a mean of 58.6 years. The age range of Bullous pemphigoid cases was 38 to 97 years with a mean of 66.1 years.

According to our study, immunobullous diseases were more common in males rather than females. (M:F=3:2) Pemphigus group of diseases showed almost equal distribution between males and females but bullous pemphigoid showed greater prevalence in males. Bullous SLE cases were limited to females.

All the cases of pemphigus vulgaris show cutaneous involvement whereas 38.46% of the cases show oral involvement. The commonest site of cutaneous lesions were found to be the trunk (52.9%) followed by head and neck region (29.4%). Our study also included cases of pemphigus foliaceus manifesting cutaneous lesions only, all showing predominantly truncal involvement. The case of pemphigus erythematosus under study showed lesions involving extremities and neck.

Lesions of Bullous pemphigoid were predominantly on arms (90%) and legs (70%). Only 20% of the cases showed oral lesions.

The case of bullous Lupus Erythematosus showed blisters over the extensor aspect of upper limbs, upper back and ears. A case which showed multiple blisters over fingers, toes and in the perioral region was diagnosed as showing regenerative bullae.

Histopathological examination of Pemphigus vulgaris cases showed the formation of intraepidermal vesicles. Vesicle formation was brought about by acantholysis (94%) and some amount of cytolysis (82.3%). The lower layer of keratinocytes appeared to be firmly attached to the basement membrane in 82.2% cases giving rise to the characteristic 'row of tombstones' appearance. The inflammatory infiltrate within the blister was noted to be predominantly lymphocytic, with some of the cases showing neutrophilic and eosinophilic components.

The lesions in Pemphigus foliaceus were situated in the upper layers of epidermis with one case showing lesions in subcorneal location. These superficial vesicles were found to contain a few acantholytic cells and inflammatory cells including lymphocytes, neutrophils and eosinophils. Epidermal changes noted include acantholysis in all of the cases and spongiosis in two cases.

The only case of Pemphigus erythematosus encountered in our study showed a superficial blister similar to the lesion in pemphigus foliaceus with erosion of the roof of the blister. Only cytolysis was noted as epidermal change. A few lymphocytes were noted within the blister.

Bullous pemphigoid cases showed bullae in subepidermal location, all of them showing predominantly eosinophilic infiltrate. Lymphocytes and neutrophils were seen accompanying eosinophils in a few cases. The most predominant epidermal change was spongiosis, seen in 60% of cases. Basement membrane zone destruction (30%) and cytolysis (10%) were less commonly noted.

The cases of bullous SLE showed acantholysis only and no spongiosis, cytolysis, basement membrane destruction and reticular degeneration. The subepidermal bullae in these cases yielded neutrophils predominantly.

A single case showing intraepidermal vesicles over limbs in an elderly female with no marked epidermal changes could not be placed under either category.

Discussion

Immunobullous disorders are caused by the action of various antibodies to antigens present in the epidermis.

Table 1: Distribution of diseases.

Type of Disease		Number of Cases	Percentage
Pemphigus group	Pemphigus vulgaris	13	43.3%
	Pemphigus foliaceus	3	10%
	Pemphigus erythematosus	1	3.3%
Bullous pemphigoid		10	33.3%
Bullous SLE		2	6.7%
Others		1	3.3%

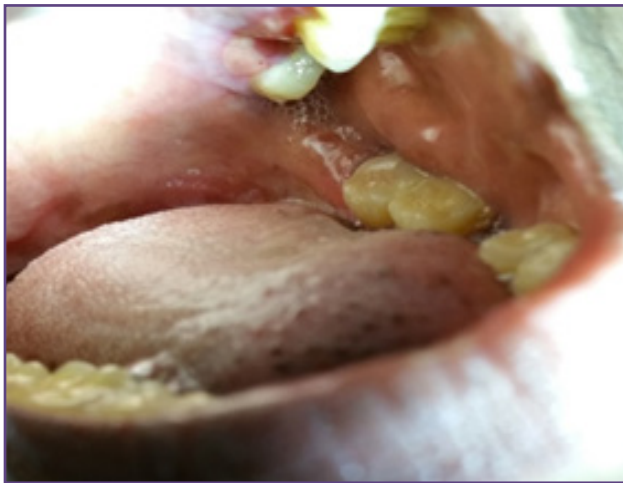

Fig. 1: Oral lesions in Pemphigus Vulgaris- A vesicle can be noted on the mucosa over the inner surface of the cheek.

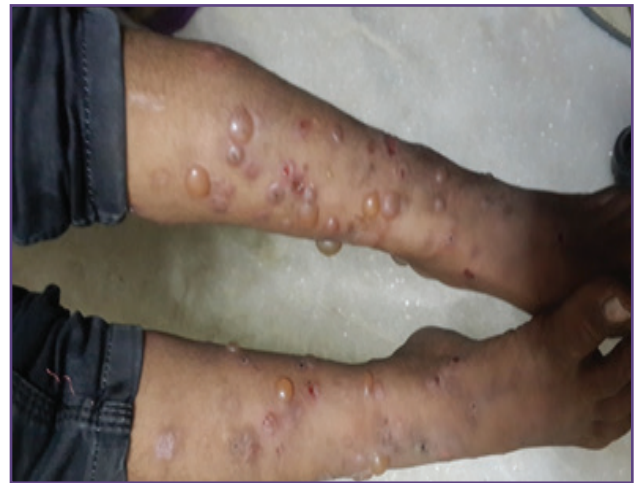

Fig. 2: Lesions in Bullous Pemphigoid - Large bullae on the lower limbs bilaterally in a patient with Bullous Pemphigoid.

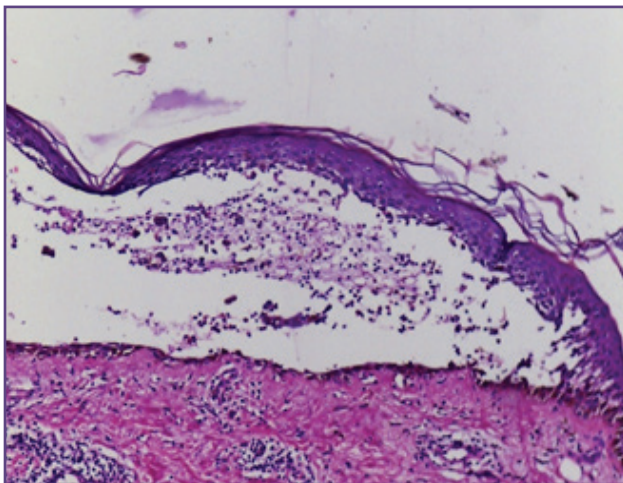


Fig. 3: Vesicle in Pemphigus Vulgaris (H&E stain, 10X)- Intraepidermal vesicle showing inflammatory cells and acantholytic cells.

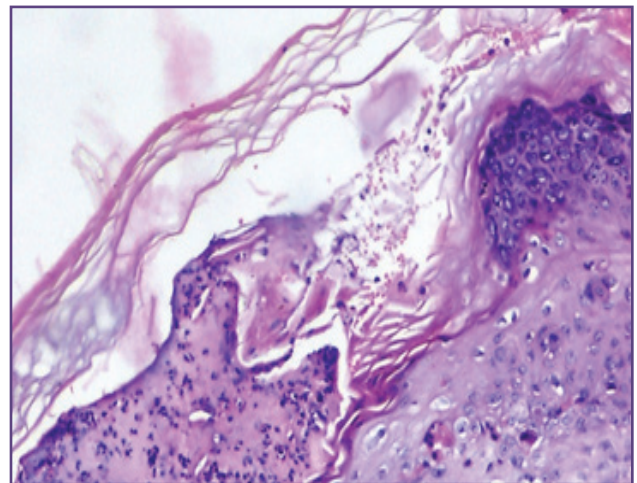


Fig. 4: Blister in Pemphigus Foliaceus (H&E stain, 40 X) - Vesicle is formed in the upper layers of epidermis.

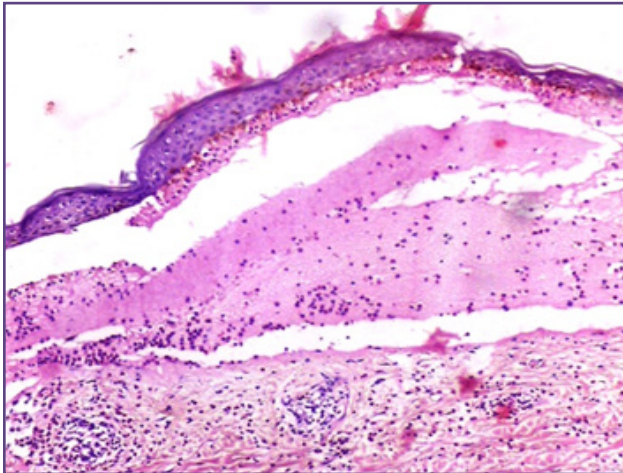


Fig 5: Blister in Bullous Pemphigoid (H&E stain, 10 X)-Subepidermal bullae showing eosinophilis predominantly.

They are manifested as fluid filled cavities termed as vesicles or bullae based on their size.

Light microscopy with Hematoxylin & Eosin (H&E) staining is the simplest method for the diagnosis and classification of Immunobullous diseases.

Pemphigus vulgaris is a disease affecting a wide age range. In our study, the age of patients with pemphigus group of diseases varied from 30 years to 83 years with a mean age of 55.53 years.

Most of our patients belonged to fifth and sixth decade, which is in concordance with a study by Kambi et al, which showed maximum incidence of pemphigus in the fifth decade.^[2] Langan et al also showed higher incidence in older age groups, predominantly in women.^[3] Another study by Rizvi et al from Pakistan showed maximum number of cases in the age group of more than 60 years.^[4] Ajithkumar et al, in a study carried out in Kerala, gave the average age of Pemphigus Vulgaris patients as 58 in males and 37 in females.^[5]

The other cases belonging to the pemphigus group included Pemphigus foliaceus and Pemphigus erythematosus. The mean age of pemphigus foliaceus obtained in our study is 58.67 years. This is slightly higher than the usual age group of pemphigus foliaceus as seen in similar studies⁽⁵⁾ by Ajithkumar et al. Non endemic Pemphigus foliaceus is given a wide range of 40 to 60 years by James et al⁽⁶⁾. Pemphigus erythematosus was seen in an 83 year old male in contrast to the cases noted in fourth and fifth decades by other authors.^[1,5]

Cases of bullous pemphigoid also showed a wide age range varying from 38 to 79 years. Langan et al gives a range of 23 to 102 years with a median age of 80 years.^[3]

The blisters formed on skin and mucus membrane are classified according to their size as vesicles and bullae.

Patients with pemphigus vulgaris mostly presented with flaccid vesicles with surrounding areas showing denuded areas caused by rupture and erosion. Chandrasekhar et al describes most (90.9%) of the pemphigus vulgaris lesions under study as flaccid blisters situated on a non-erythematous base⁽¹⁾. Leroy et al reported a clinical variant termed Pemphigus vegetans which presented as vegetating lesions appearing in the flexures⁽⁷⁾. The other two subtypes of pemphigus also showed large vesicles as primary lesions. However, large erosions are more commonly noted at the time of clinical presentation.^[6]

All cases of bullous pemphigoid presented with characteristic large tense bullae placed on urticarial erythematous base or non-erythematous skin. Vesicular pemphigoid is a variant entity which is clinically similar to Dermatitis herpetiformis with smaller blisters but can be differentiated from it on the basis of widely varying histology⁽⁸⁾. Dermatitis herpetiformis shows a subepidermal infiltrate of neutrophils with papillary microabscesses whereas bullous pemphigoid has a characteristic histology of eosinophilic papillary abscesses and inflammatory infiltrate rich in eosinophils. No such variants were noted in the present study.

Pemphigus vulgaris cases in our study manifested cutaneous involvement alone in 61.54% cases and combined cutaneous and mucus membrane involvement in 38.46% cases. Trunk and the head and neck region were the most common location for cutaneous lesions in our study. Arya et al in a study of 70 cases, reported mucous membrane lesions in 72.1% cases, generalized skin and mucosal involvement in 37.2% cases, trunk and extremities being the most common sites for cutaneous lesions⁽⁹⁾. Lesions involving both the skin and mucus membranes predominated in most of the cases (66.87%) in a similar study⁽¹⁰⁾ by Patel Prashanth et al.

Both Dsg 1 and Dsg 3 antibodies appear to be involved in the blister forming mechanism in pemphigus. Dsg 3 predominates in oral mucosa whereas both Dsg 1 and 3 are present in skin. The major antibody involved in Pemphigus vulgaris is thought to be Dsg 3, which results in vesicle formation in the skin as well as in mucous membranes. Mahoney et al suggests that antibodies to Dsg 3 alone are formed in case of early stages of the disease and hence causing predominantly mucosal lesions⁽¹¹⁾. In later stages antibodies develop to both Dsg 3 and Dsg 1. These lead to blister formation in skin as well as mucous membranes in patients with long duration of disease.

Pemphigus foliaceus lesions were found in a generalized distribution by Arya et al, with facial involvement predominating (9). Oral lesions are not usually seen in Pemphigus Foliaceus. According to James et al, the cases of Pemphigus foliaceus are purely cutaneous, with initial lesions commonly found in the truncal region (6), which is true in all our cases. Our cases showed generalised involvement of scalp, chest, trunk and arms. Based on various experimental studies conducted in mouse models, Mahoney et al hypothesizes that, blisters are formed in superficial epidermis only as this is the only area in which Dsg 1 is present without co expression of Dsg3.^[11]

Pemphigus Erythematosus is characteristically distributed in a pattern resembling Systemic Lupus Erythematosus. In our case of Pemphigus Erythematosus, lesions were noted over the neck and extremities.

The lesions of bullous pemphigoid in our study were predominantly distributed over extremities (66.7%) and trunk (33.3%). Few of the cases (33.3%) showed lesions in the oral cavity as well. Lesions of bullous pemphigoid described by Chandrasekhar et al, were also situated mainly in the extremities (1) in 62.5% and in the chest in 50% cases. Kambil et al proposed that all cases of bullous pemphigoid showed involvement of extremities and most of them showed truncal involvement (80%) also.^[12]

Bullous lesions in sun exposed areas of head, trunk and extremities in a young female with systemic lupus erythematosus have been reported by Aswani et al.^[13]

All cases of Pemphigus vulgaris in our study except one showed the presence of suprabasal bulla which is similar to those seen in other studies. (1) Absence of bulla in the remaining case could be due to the erosion of epidermis in long standing lesion. Ultrastructural studies by Liu et al postulate that the suprabasal blistering in pemphigus is due to the binding of antibodies to desmoglein 3 which blocks its adhesive function.^[14]

Most of the cases show mixed inflammatory cell infiltrate within the bulla composed of neutrophils, lymphocytes and eosinophils. Similar histopathological studies by Kundu et al also showed mixed inflammatory cell infiltrate within suprabasal bulla in pemphigus vulgaris with lymphocytes predominating (15). Lever mentions the presence of mixed inflammatory cell infiltrate as a change seen in long standing lesions.

The presence of acantholytic cells in the epidermis as well as in the bulla is a characteristic feature seen in all of the cases in our study. Arundhati et al in a cross sectional study of 36 patients also mentions the presence of acantholysis in 97% of cases (16). Liu et al explains acantholysis by ultrastructural studies (14). On the attachment of

antibodies, the desmosomes were found to be split into two, which leads to weakening of the adhesion between keratinocytes. As the attachment of basal keratinocytes to the basement membrane is not affected, the 'row of tombstones' appearance is noted in 41.8% of cases which is also regarded a hallmark of the disease. In our study this feature was seen in 8/9 (88.9%) of cases.

Eosinophilic spongiosis in the lower epidermis is considered an early change in case of pemphigus vulgaris which has been noted in few of the cases under study. Emmerson et al gives an account of 7 cases of pemphigus in which eosinophilic spongiosis has been described and states it to be a typical finding in early stages.^[17]

Some of the lesions (11.1%) show changes due to long duration of the lesion such as erosion and ulceration of roof of blister, downward proliferation of epidermal strands, forming villi like structures.

The initial histopathological feature of pemphigus foliaceus is the formation of small lacunae in upper layers of epidermis. As the lesions progress, these lacunae coalesce to form vesicles in upper epidermis or the subcorneal layer. The cases in our study showed blisters in both these locations. Sadhu et al reported the presence of bullae in the upper epidermis or subcorneal region containing neutrophils predominantly (15). Occasionally eosinophils and acantholytic cells may be present. Blisters in pemphigus foliaceus are commonly more superficial in location as the autoantibody associated with this condition acts against Dsg 1, which is localized to the upper layers of epidermis (11). The type of inflammatory infiltrate seen depends on several factors among which the most important is the age of the lesion.

Pemphigus erythematosus is otherwise termed Senear Usher Syndrome and is regarded as a variant of pemphigus foliaceus. The disease combines clinical features similar to lupus erythematosus with acantholysis in histopathology. The characteristic vesicles are detected in the upper layers of epidermis as in pemphigus foliaceus indistinguishable from those of Pemphigus foliaceus, but the clinical distribution of the lesions provides the clue to diagnosis.

Histopathology of bullous pemphigoid shows subepidermal blister containing polymorphous exudate predominantly composed of eosinophils. Early lesions of the disease may also show mast cells and basophils (18). A specific diagnosis is rendered difficult due to the overlap in clinical features with other diseases like Epidermolysis Bullosa Acquisita and Cicatricial Pemphigoid. The inflammatory cell content in EBA as well as cicatricial pemphigoid is more likely to be mononuclear or neutrophilic rather than eosinophilic.^[19]

Cicatricial pemphigoid also show a characteristic area of lamellar fibrosis in the subepidermal region.

The other bullous lesions encountered in our study included Bullous SLE (Systemic Lupus Erythematosus). A study by Grover et al reported subepidermal split with neutrophilic papillary dermal abscesses in bullous SLE which is the most common histological pattern(20). Nischal et al has proposed a rarer pattern comprising of a predominantly perivascular neutrophilic infiltrates along with the presence of bullae which occurs in the early stages of the disease(21). The classical histological picture of lupus erythematosus, involving vacuolar degeneration of stratum basale, is also noted in some cases.

Conclusion

Among the cases under study, a definite diagnosis was made by correlating the clinical findings with histology in all but one instance. Great attention is required in taking clinical history so as not to miss subtle hints leading to a specific diagnosis. Histopathological changes in the epidermis are highly relevant in diagnosis, although the nature of the inflammatory cell contents of the blister relate more to the chronicity of the lesion. Histologically similar lesions may be distinguished by clinical history and examination findings. When the clinicians' findings and the histopathological picture put together cannot reach a satisfactory diagnosis, higher investigations like Direct Immunofluorescence can resolve the dilemma.

References

- Chandrashekar M, Leena JB, Vijaya B, Sunila R, Manjunath GV. A clinicopathological study of immunobullous lesions of the skin a 2 years study. *NJISMS*.2012;1:19–26.
- Kambi DP, Deepthi,Santosh CS,Suguna BV,Gopal MG, Abhishek V. Direct immunofluorescence study in autoimmune bullous disorders of skin. *International Journal of Biomedical and Advance Research*. 2013;4(9).610-618.
- Langan SM, Smeeth L, Hubbard R, Fleming KM, Smith CJP, West J. Bullous pemphigoid and pemphigus vulgaris--incidence and mortality in the UK: population based cohort study. *BMJ*. 2008;337:a180.
- Rizvi SR, Sadiq S. Use of direct immunofluorescent microscopy in the diagnosis of vesicubullous disorders of skin. *Pak J Med Sci*. 2010;26(2):411-415.
- Ajithkumar K. Incidence of Pemphigus in Thrissur District, South India. *Indian J Dermatol Venereol Leprol*. 2008;74:349-351.
- James K, Culton D, Diaz L. Diagnosis & Clinical Features of Pemphigus Foliaceus. *Dermatol Clin*. 2011;29(3):405–12.
- Leroy D, Lebrun J, Maillard V, Mandard JC, Deschamps P. Pemphigus vegetant , a clinical type of chronic pustular dermatitis of Hallopeau. *Ann Dermatol Venereol* 1982;109:549-555.
- Neff AG, Turner M, Mutasim DF. Treatment strategies in mucous membrane pemphigoid. *Ther Clin Risk Manag*. 2008;4(3):617–626.
- Arya SR, Valand AG, Krishna K. A clinic-pathological study of 70 cases of Pemphigus. *Indian J Dermatol Venereol Leprol* 1999;65:168-71.
- Patel PR, Kapuria DP, Chiplonkar SG. A Clinico-Pathological Study of 22 Cases of Pemphigus National Journal of Medical Research. 2012;2(3):269–271.
- Mahoney MG, Wang Z, Rothenberger K, Koch PJ, Amagai M, Stanley JR. Explanations for the clinical and microscopic localization of lesions in pemphigus foliaceus and vulgaris. *J Clin Invest*. 1999;103(4):461–468.
- Kambil SM, Madavamurthy P. Immunobullous disorders: Clinical histopathological and immunofluorescence study of thirty-six cases. *Muller J Med Sci Res* 2014;5:134-138.
- Aswani V, Vaz B, Shah S, Malkani RH. Bullous Systemic Lupus Erythematosus. *Indian J Dermatol Venereol Leprol* 1993;59:97-100
- Liu Z, Li N, Diaz L a. Immunopathological mechanisms of acantholysis in pemphigus vulgaris: An explanation by ultrastructural observations. *J Invest Dermatol*. 2004;122(5):xiii-xiv
- Kundu B ,Sadhu A, Meyur R, Kundu S, De A, Sarkar S. Original article : Comparative microanatomy of the normal skin with that of immunobullous condition. *Indian Journal of Basic and Applied Medical Research* 2013;2(8):1146–1152.
- Arundhathi S, Raghunatha S, Mahadeva KC. A Cross-sectional Study of Clinical, Histopathological and Direct Immunofluorescence Spectrum of Vesicubullous Disorders. *J Clin Diagnostic Res [Internet]*. 2013;7(12):2788–2792.
- Emmerson RW, Wilson-Jones E. Eosinophilic spongiosis in pemphigus. A report of unusual histological change in pemphigus. *Arch Dermatol*. 1968;97:252-257.
- Khandpur S, Verma P. Bullous pemphigoid. *Indian J Dermatol Venereol Leprol*. 2011;77(4):450.
- Chen M, Kim GH, Prakash L, Woodley DT. Epidermolysis bullosa acquisita: Autoimmunity to anchoring fibril collagen. *Autoimmunity*. 2012;45(1):91–101.
- Grover C, Khurana A, Sharma S, Singal A. Bullous Systemic Lupus Erythematosus *Indian J Dermatol*. 2013 Nov-Dec; 58(6): 492-495
- Nischal KC, Khopkar U. An approach to the diagnosis of neutrophilic dermatoses: A histopathological perspective. *Indian J Dermatol Venereol Leprol* 2007;73:22-30.

*Corresponding author:

Annu Elizabeth Prakash, Kaliyadan House, Cheriyaipilly, Kaitharam P.O., North Paravur, Ernakulam District, Kerala, India. Pin Code- 683519

Phone: +91 9497470661

Email: annelizprakash@gmail.com

Financial or other Competing Interests: None.