

Histopathological Spectrum of Nephrectomy Specimens

Madhu Kumar R¹, Meghana P^{2*}, Vidya Vasudev² and Bharathi M²

¹Department of Pathology, Sambhram Institute of Medical Sciences, India

²Department of Pathology, Mysore Medical College and Research Institute, India

ABSTRACT

Background: Kidneys are the vital organs of the body which are having multiple functions. The benign or malignant diseases of the kidney result in total organ removal. Renal tumors comprise a wide spectrum of neoplastic lesions with patterns that are distinct for children and adults. In India management of chronic kidney diseases is a great challenge as the dialysis and kidney transplantations are expensive.

Objectives: To study histopathological features of various nephrectomy specimens and to determine the age and sex distribution in various renal lesions.

Materials and Methods: The study is done in Mysore medical college and research institute. Total 50 nephrectomy cases were studied in a period of 2 years from 2015 to 2017.

Result: Total of 50 nephrectomy cases were studied out of which 27 were male and 23 were female with ratio of 1.17:1. The non-neoplastic and neoplastic cases were 36 and 14 respectively, with ratio of 1.44:1. In non-neoplastic chronic pyelonephritis is most common 21 cases (58.3%), followed by hydronephrosis - 5 (13.9%) cases, tuberculous pyelonephritis - 3 cases (8.3%), Xanthogranulomatous Pyelonephritis - 2 cases (5.6%). Simple renal cyst, Polycystic kidney disease, End stage kidney disease, RTA and Ischemic atrophy - 1 case each. In neoplastic, RCC is the most common - 10 cases, followed by SCC and Angiomyolipoma - 2 cases each. Most of the patients presented in age group of 4th to 5th decade and histologically RCC-clear cell type was the most common subtype.

Conclusion: Chronic pyelonephritis is most common non neoplastic lesion and RCC is the most common neoplastic lesion in which clear cell type is most common subtype

Keywords: Chronic Pyelonephritis, Renal Cell Carcinoma, Clear Cell Carcinoma

Introduction

Kidneys are the vital organs of the body which are having multiple functions. Their main function is not only excretion but they also maintain water and salt metabolism along with acid base balance, maintain the blood pressure through renin angiotensin mechanism and hematopoiesis by producing erythropoietin.^[1]

Like other organs in human body, kidneys also involved by many benign or malignant diseases which requiring total organ removal. Simple nephrectomy is done to remove nonfunctioning kidneys which are irreversibly damaged by different benign pathological conditions and on the other hand for different malignant conditions of the kidney radical nephrectomy is indicated.^[2]

Renal tumors comprise a wide spectrum of neoplastic lesions with patterns that are distinct for children and adults. A wide variety of benign and malignant tumors arises from the renal parenchyma.^[3]

With the extensive use of imaging techniques in the recent years, the number of nephrectomies were increased. In India management of chronic kidney diseases is a great challenge as the dialysis and kidney transplantations are expensive.^[4]

Materials and Methods

This is a cross sectional study undertaken in the department of pathology, Mysore Medical College and Research Institute for duration of 18 months from December 2015 to May 2017. A total number of 50 cases were studied. Detailed clinical history of the patients were collected while receiving the specimen and by checking the medical records.

All nephrectomy specimens were fixed in 10% formalin and then subjected to gross examination, noting the size, appearance, external surface and cut surface. The findings were recorded and the representative bits were given. The tissue was processed and stained with routine Hematoxylin and Eosin and other special stains like AFB were done wherever required.

Multiple sections were studied and clinic-pathological evaluation of nephrectomy specimens were done.

Tumors were further classified according to 2016 WHO classification.

Result

A total of 50 nephrectomy cases were studied. Out of which 36 (72%) were non-neoplastic and 14 were (28%)

were neoplastic. Table 1 shows the frequency of various lesions in nephrectomy specimens.

Most common lesions encountered is chronic pyelonephritis followed by Renal cell carcinoma and hydronephrosis. Chronic granulomatous pyelonephritis 3 cases, Xanthogranulomatous pyelonephritis, Squamous cell carcinoma and Angiomyolipoma are each two cases. Polycystic kidney, Simple renal cyst, RTA, End stage renal disease and Ischemic atrophy are each one case.

Majority of nephrectomy were performed 4th and 5th decade followed by 3rd decade. No cases at 1st and 8th decade. The oldest and youngest patient were 78 and 19 years.

Non neoplastic lesions were encountered most commonly during 5th decade followed by 3rd and 4th decade. Chronic pyelonephritis was the commonest non-neoplastic lesion (58.3%, 21/36) encountered in the present study, followed by hydronephrosis (13.9%, 5/36). Chronic pyelonephritis was commonest during 3rd and 4th decade. Hydronephrosis was commonest during 6th decade. Chronic granulomatous pyelonephritis was commonest during 5th decade.

Chronic pyelonephritis showed slight female preponderance (male: female ratio – 1:1.23). Hydronephrosis was predominantly seen in males (male: female – 1.33:1) and Tuberculous pyelonephritis was relatively more common in males (male: female – 1.77:1).

58.33% of the non-neoplastic lesions showed involvement of the right kidney and 41.7% of the non-neoplastic lesions showed involvement of left kidney.

Renal cell carcinoma was equally distributed in both sex (male: female ratio- 1:1). Two cases of squamous cell carcinoma was seen in male. Two cases of Angiomyolipoma was seen in female.

The most frequent finding was the presence of hemorrhagic and necrotic areas. Cystic degeneration was present in 50% of the cases.

Table 2 illustrates the frequency of the various histological variants of renal cell carcinoma. The most common subtype encountered was clear cell type comprising of 5 out of 10 cases of RCC followed by papillary variant which comprises of 4 cases. Chromophobe variant was seen in 1 case.

Table 3 shows the microscopic features of Renal cell carcinoma. In clear cell RCC out of 5 cases 3 cases exhibited Furhman nuclear grade 3 and 2 cases shows Furhman nuclear grade 2. Chromophobe RCC exhibits Furhman nuclear grade 2. In Papillary RCC out of 4 cases 3 exhibits Furhman nuclear grade 4 and 1 case exhibits Furhman nuclear grade 3. One case of papillary RCC showed lymphatic infiltration.

Squamous Cell Carcinoma: Two case of SCC were seen. Grossly both are enlarged, tumor proper seen which is involving almost entire kidney, areas of haemorrhage and necrosis is seen. Microscopically squamoid cells with increased N:C ratio, prominent nucleoli and moderate amount of cytoplasm. Also seen are areas of necrosis.

Angiomyolipoma: One case of classical and one case of epitheloid Angiomyolipoma. Grossly both were enlarged, cut section shows multiple yellowish areas. Microscopically fatty tissue, blood vessels and muscle component seen in both the cases. Epitheloid cells are seen in epitheloid variant of angiomyolipoma.

Majority of the RCC presented in Stage I (50%, 5/10), followed by Stage II (40%, 4/10) and 1 case in stage III. 2 cases of SCC is in stage II.

RCC: All cases presented with pain abdomen and haematuria. 8 cases were with mass per abdomen

SCC: There was 2 cases of SCC who presented with pain abdomen, mass per abdomen and hematuria.

Angiomyolipoma: There were 2 cases both the cases presented in pain abdomen and 1 case presented with mass per abdomen and haematuria.

TABLE 1: FREQUENCY OF LESIONS ENCOUNTERED IN NEPHRECTOMY SPECIMENS

Non-Neoplastic Lesions	No. of cases	Percentage
Chronic pyelonephritis	21	42%
Tuberculous pyelonephritis	3	6%
Hydronephrosis	5	10%
Polycystic kidney	1	2%
Simple renal cyst	1	2%
Xantho granulomatous pyelonephritis	2	4%
RTA	1	2%
End stage renal disease	1	2%
Ischemic atrophy	1	2%
Neoplastic lesions	No. of cases	Percentage

Non-Neoplastic Lesions	No. of cases	Percentage
Renal cell carcinoma	10	20%
Squamous cell carcinoma	2	4%
Angiomyolipoma	2	4%
Total	50	100%

TABLE-2: FREQUENCY OF THE VARIOUS HISTOLOGICAL VARIANTS OF RENAL CELL CARCINOMA.

Histological variants	No. of Cases	Percentage(%)
Clear cell RCC	5	50%
Chromophobe RCC	1	10%
Papillary RCC	4	40%
Total	10	100

TABLE-3: MICROSCOPIC FEATURES OF RENAL CELL CARCINOMA.

	Clear cell carcinoma	Chromophobe carcinoma	Papillary carcinoma
Clear cells	05		
Granular cells	05		
Papillary areas	01		4
Raisinoid nucleus		1	
Furhman nuclear grade			
1			
2	02		
3	03	01	01
4			03
Areas of haemorrhage and necrosis	05	01	04
Evidence of capsular infiltration	00	00	00
Evidence of Renal vein infiltration	00	00	00
Evidence of lymphatic infiltration	00	00	01
Evidence of adrenal involvement	00	00	00



Fig. 1a: Gross specimen of Chromophobe RCC, cut section shows grey white illdefined growth involving entire kidney.

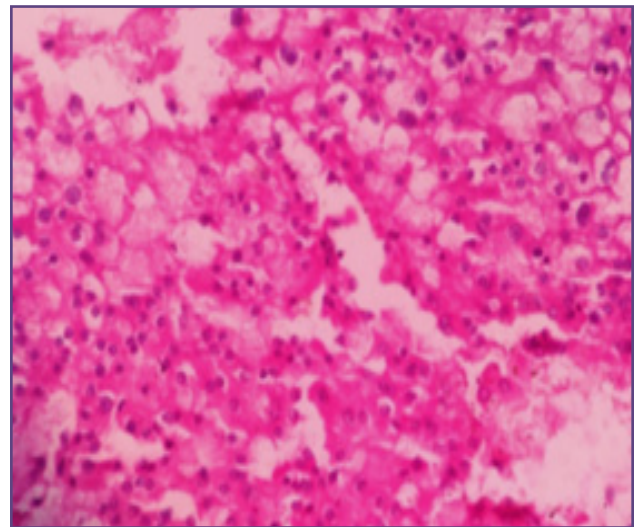


Fig. 1b: Microscopy: Section shows groups of tumor cells acinar growth pattern with individual cells showing clear to eosinophilic flocculent cytoplasm and few of them have perinuclear halos (H & E, 40X).

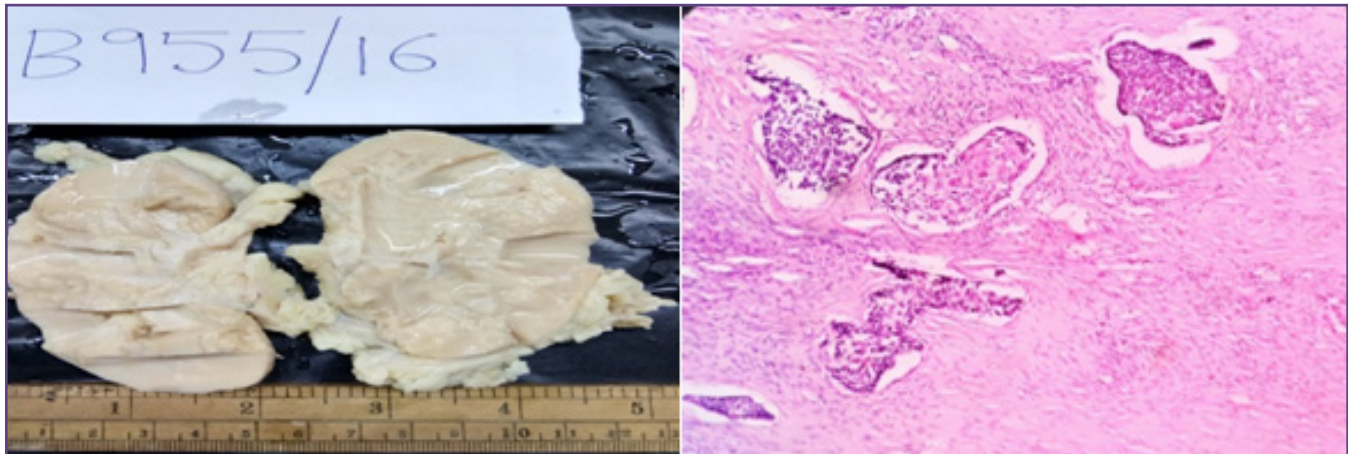


Fig. 2a: Gross specimen of Squamous cell carcinoma with cut surface showing grey white.

Fig. 2b: Microscopy of SCC shows pleomorphic squamoid cells. (H & E, 10X).

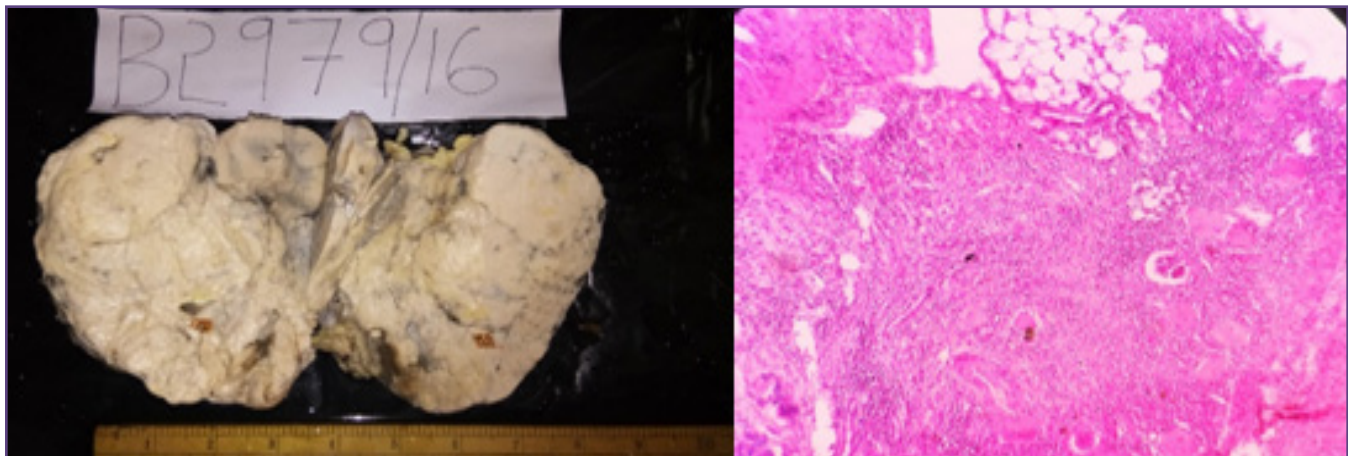


Fig. 3a: Gross specimen of Angiomyolipoma showing enlarged with cut surface showing grey white and yellowish areas.

Fig. 3b: Microscopy of Angiomyolipoma shows all three component i.e., adipose tissue, blood vessels and spindle cells. (H & E 10X).

Discussion

Histopathology is an important and useful learning tool in the hands of pathologists to study the histopathological spectrum of diseases. Radical nephrectomy (RN) was first described by Robson in 1963, it has been described as the standard surgical treatment of kidney cancer.^[5]

In this study it was observed out of total 50 cases, 26 i.e., 52% were male and 24, i.e., 48% were female, which is similar to study of Aiffa Aiman et al.^[6]

Comparison of sex distribution of cases with other studies

SI.NO.	Authors	No. of cases	Male	Female
1	Aiffa Aiman et al ^[6]	140	51.4%	48.5%
2	El Malik et al ^[7]	85	61%	39%
3	Ghalayini IF ^[8]	423	46.3%	47.7%
4	Present study	50	52%	48%

In this study it was observed out of total 50 cases, 36 i.e., 72% were non neoplastic and 14, i.e., 28% were neoplastic which is similar to study of Divyasree B.N. et al.^[3]

Comparison of distribution of non neoplastic and neoplastic lesion with other studies

SI. NO.	Authors	NO. of cases	Non neoplastic	Neoplastic
1	Ngairangbam S et al ^[8]	49	85.71%	14.29%
2	Shaila et al ^[1]	82	77.66%	24.64%
3	Divyasree B.N. et al ^[3]	116	72.41%	27.59%
4	Present study	50	72%	28%

Comparison of different lesions in nephrectomy specimen with other studies.

Lesions	Shaila et al ^[1]	Aiman A et al ^[6]	Ngairangbam S et al ^[8]	Present study
Chronic pyelonephritis	60.3%	62.8%	73.46%	42%
Tuberculous pyelonephritis	11.32%	-	-	6%
Hydronephrosis	1.89%	-	2.04%	10%
Polycystic kidney	0.94%	-	-	2%
Simple renal cyst	-	1.4%	-	2%
Xantho granulomatous pyelonephritis	1.89%	5.7%	10.20%	4%
RTA	0.94%	-	-	2%
End stage renal disease	-	-	-	2%
Ischemic atrophy	-	-	-	2%
Renal cell carcinoma	11.32%	25%	10.20%	20%
Squamous cell carcinoma	-	0.7%	-	4%
Angiomyolipoma	1.89%	0.7%	2.04%	4%

The difference in most common lesions in these studies may be due to differences in study sample size, pattern of study and age group of cases studied. Chronic pyelonephritis was the commonest non-neoplastic lesion encountered followed by

hydronephrosis and Renal cell carcinoma is commonest neoplastic lesion, which is similar to other studies.

Conclusion

Renal cell carcinoma was the commonest renal tumor encountered, followed by SCC and Angiomyolipoma, 2 cases each. The most common presenting feature of Renal cell carcinoma was pain abdomen and hematuria followed by mass per abdomen. Most commonly affected males were in age group of 4-5th decade.

References

1. Shaila, Nityananda B. S, Tamil A. Spectrum of Lesions in Nephrectomy Specimens in Tertiary Care Hospital. *Journal of Evolution of Medical and Dental Sciences* 2015;Sep 10; 4(73): 12714-26.
2. Datta B, Moitra T, Chaudhury DN, Halder B. Analysis of 88 nephrectomies in a rural tertiary care center of India. *Saudi J Kidney Dis Transpl* 2012;23:409-413.
3. Bashir N, Bashir N, Shah P, Bhat N, Salim O, Nuzhat et al. Histopathological study of renal tumors in resected nephrectomy specimens – an experience from tertiary care centre. *National journal of medical research*.2015; Mar;5(1):26-9.
4. Siddappa S, Kowsalya R, Mythri KM. Benign Nephrectomies and its Variables along with Vascular Changes in the Renal Artery: A Study from Tertiary Care Centre from South India. *Journal of Nephrology and Urology Research*. 2014;2; 14-8.
5. Najar MS, Bhat MA, Wani IA, Banday KA, Reshi AR, Daga BA et al. Profile of renal tuberculosis in 63 patients. *Indian J Nephrol* 2003;13:104-7.
6. Aiman A, Singh K, Yasir M. Histopathological spectrum of lesions in nephrectomy specimens: A five year Experience in a tertiary care hospital. *J Sci Soc* 2013;40:148-54.
7. El Malik EM, Memon SR, Ibrahim AL, Al Gizawi A, Ghali AM. Nephrectomy in Adults: Asir Hospital Experience. *Saudi J Kidney Dis Transpl* 1997;8:423-7.
8. Ngairangbam S, Konjengbam R. Histopathological spectrum of non-neoplastic & neoplastic lesions in nephrectomy specimens. *J. Evid. Based Med. Healthc*. 2016; 3(16): 627-9.

*Corresponding author:

Dr. Meghana P, Department of Pathology, Mysore Medical College and Research Institute, Irwin road, Mysore, Karnataka, India. 570001

Phone: +91 9591402851

Email: megghanap.mp@gmail.com

Financial or other Competing Interests: None.