



Tranexemic Acid Induced Bilateral Acute Renal Cortical Necrosis: An Autopsy Case Report

Mangesh Machindra Londhe*, Nitin M Gadgil, Anitha Padmanabhan and Leena Pravin Naik

Dept of Pathology, LTMMC & LTMGH, Sion, Mumbai, India

ABSTRACT

Acute renal cortical necrosis (RCN) most commonly occurs from obstetric complications. However other rare cause includes medications like antifibrinolytics like tranexamic acid, which is used for acute bleeding. We report a case of 17 years female, operated for left cheek arteriovenous malformation and managed post-operatively by intravenous fluids, diuretics, antibiotics and antifibrinolytics (tranexemic acid). Postoperatively she started complaining of severe abdominal pain, breathlessness, weakness and loss of orientation with increasing levels of serum creatinine and blood urea nitrogen (BUN). Patient succumbed to death on day 6 post operative and complete autopsy was performed. All organs were unremarkable except bilateral lungs showed pulmonary edema and bilateral kidneys showed features of diffuse pattern of cortical necrosis both on gross and histopathological examination. As patient had no obstetric or other related history the cause of RCN was attributed to tranexemic acid. Thus patients on antifibrinolytics must be screened for RCN to avoid its fatal complication.

Keywords: Renal Cortical Necrosis, Acute, Bilateral, Tranexemic Acid

Introduction

A rare presentation of acute renal failure is acute RCN which in majority of cases causes irreversible loss of renal function.[1] Drug induced acute RCN is rare and antifibrinolytic drugs causing it is even rarer having only 4 cases reported in English literature.[2]

Case Report

We report a case of 17 years female who was operated for left cheek arteriovenous malformation (AVM). Post-operatively she was managed with intravenous fluids, diuretics, antibiotics and anti – fibrinolytics (tranexemic acid- 500mg 3 times a day). Since post-operative day 2 she started complaining of severe abdominal pain, breathlessness, weakness and loss of orientation. Complete haemogram revealed hemoglobin of 8mg/dl, total leukocyte count of 22,000/cumm and platelet count of 59,000/cumm. Renal function tests were abnormal with serum creatinine being 5.6mg/dl and serum BUN- 67mg/dl. Coagulation profile was normal. Ultrasonography of abdomen showed bilateral renal cortex with increased echogenicity. Patient eventually died on day 6 post-operative and complete autopsy was performed to find exact cause of death. Gross examination revealed that all organs were unremarkable except bilateral lungs showing pulmonary edema and bilateral kidneys being large, swollen with pale, yellow-white cortex and preserved medulla indicating diffuse pattern of cortical necrosis (figure 1). Histopathological examination of both kidneys showed normal medulla with cortex showing tubular necrosis (figure 2&3), arterioles being dilated and showing fibrin thrombi (figure 4). Few

intraglomerular capillaries also showed fibrin thrombi (figure 5). However renal artery didn't show thrombus. After thorough clinical correlation and literature search the cause of RCN was attributed to use of tranexemic acid.

Discussion

Acute bilateral RCN has a poor prognosis and accounts for approximately 2% of all cases of acute renal failure in developed countries while in developing countries it is between 6%-7% [2]. The most common cause of RCN is from obstetric complications, however its overall incidence has decreased from 20%-30% to 5% in the last two decades in developing countries. The other causes of RCN include sepsis with disseminated intravascular coagulation, hypotension, microangiopathic hemolytic anemia and drugs.[2] Drugs causing RCN is very rare accounting to about 4% of total causes and antifibrinolytics like tranexemic acid being one of them is even more rare[3]. Tranexamic acid reversibly binds plasminogen and interferes its binding fibrin thus inhibiting fibrinolysis, exerting antifibrinolytic effects and promoting thrombus formation with hemostasis, thus used for control of bleeding.[2] Ours is the first report of acute RCN in which tranexamic acid (500mg three times a day) was administered for control of bleeding after surgery for AVM and eventually led to death. The most sensitive imaging modality for RCN is contrast-enhanced CT scans which show bilateral enhancement of the renal medulla and renal subcapsular area with no enhancement of the renal cortex. However plain film shows hallmark thin cortical






Fig. 1: enlarged bilateral kidneys, swollen with cut surface showing pale, yellow-white cortex and preserved medulla indicating diffuse pattern of cortical necrosis.

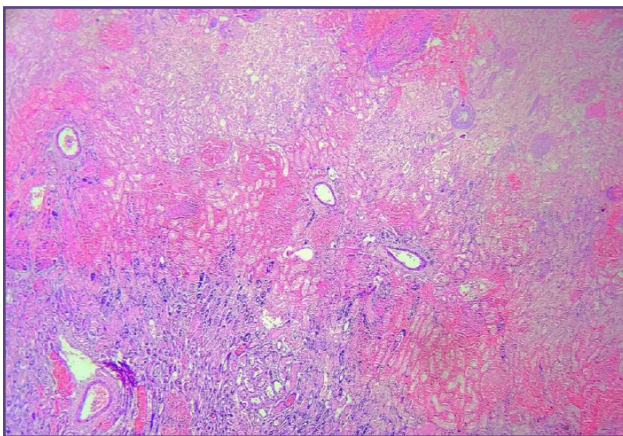


Fig. 2: (H&E 10X) cortex showing tubular necrosis.

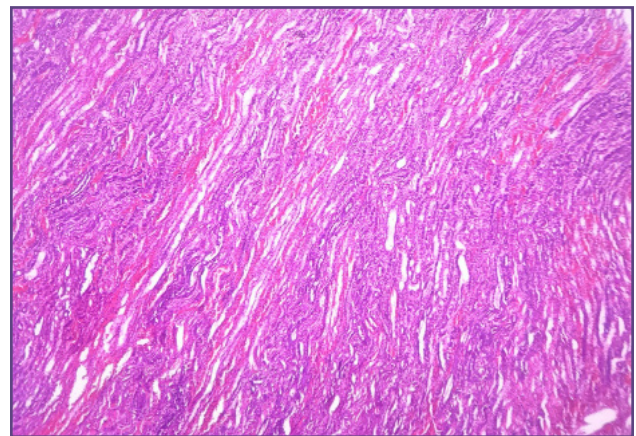


Fig. 3: (H&E 10X) Medulla is preserved.

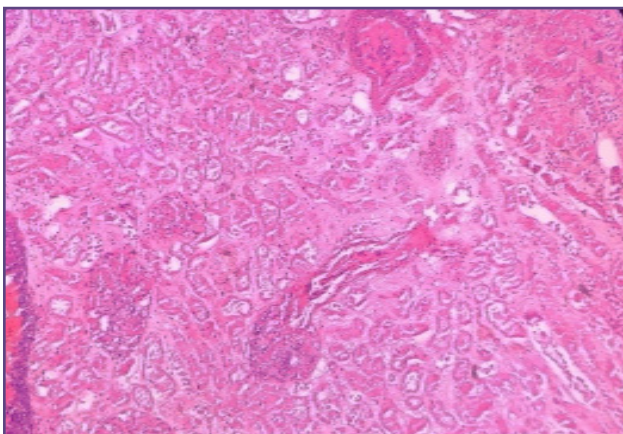


Fig. 4: (H&E 20X) arterioles are dilated and show fibrin thrombi.

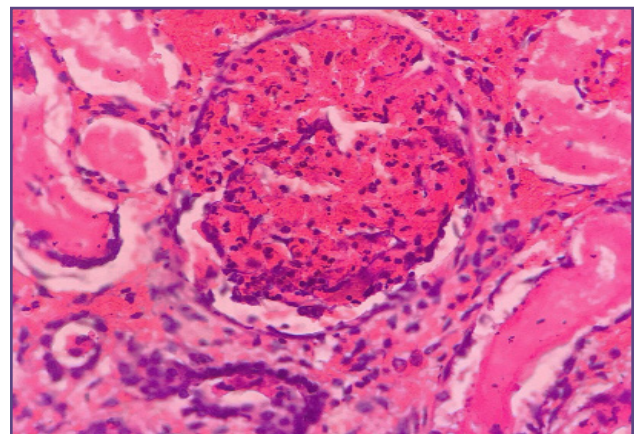


Fig. 5: (H&E 40X) intraglomerular capillaries showed fibrin thrombi.

lines caused by calcification and ultrasonography shows characteristic finding of hypoechoic circumferential band in the renal subcapsular area. The diagnosis of RCN often requires a kidney biopsy, and the histology typically shows tubular cell necrosis with leukocyte infiltration.[2] The glomeruli may be necrotic with intraglomerular capillaries and arterioles showing fibrin thrombi with medullary preservation as was seen in our case[1,2]. Management of acute RCN includes hemodialysis, as in other forms of acute renal failure.

Conclusion

RCN has a poor prognosis, mortality rate being 55%–86% prior to 1980 but decreased to 36% after 1980 with improvements in hemodialysis.[2]As shown in this rare case of tranexamic acid-induced acute RCN used for post-operative bleeding control, led to acute renal failure and eventually death. Hence the clinicians should be aware of the possibility of this potentially fatal complication of tranexemic acid.

Reference

1. Koo JR, Lee YK, Kim YS, Cho WY, Kim HK, Won NH. Acute renal cortical necrosis caused by an antifibrinolytic drug (tranexamic acid). *Nephrol Dial Transplant* 1999; 4:750-752.
2. Ko DH, Kim TH, Kim JW, Gu JJ, Yoon BH, Oh JH et al. Tranexamic Acid-Induced Acute Renal Cortical Necrosis in Post-Endoscopic Papillectomy Bleeding. *Clinical Endoscopy*. 2017; 50(6):609-613.
3. Prakash J, Singh VP. Changing picture of renal cortical necrosis in acute kidney injury in developing country. *World J Nephrol* 2015; 4:480-486.
4. Odabaş AR, Cetinkaya R, Selçuk Y, Kaya H, Coşkun U. Tranexamic-acid-induced acute renal cortical necrosis in a patient with haemophilia A. *Nephrol Dial Transplant* 2001;16:189-190.
5. Sahay M, Swarnalata, Swain M, Padua M. Renal cortical necrosis in tropics. *Saudi J Kidney Dis Transpl* 2013; 24:725-730.
6. Park JH, Kang MK, Na WT, Song IG, Jung JH, Yoon, SH et al. A case of bilateral acute renal cortical necrosis complicated by tranexamic acid administration. *Korean J Med* 2011; 80:723-728.

***Corresponding author:**

Dr. Mangesh M. Londhe, Plot no. 3, Sainathnagar, Nigdi, Pune, India

Phone: +91 9850960153

Email: m.londhe03@gmail.com

Financial or other Competing Interests: None.