

Acquired Coagulopathies Secondary to Plasma Cell Dyscrasias: A Report of Two Cases and Review of Literature.

Hitha Diljith, Ambika Lokababu Pagadalu, Sree Rekha Jinkala*, Rakhee Kar, Sajini Elizabeth Jacob and Debdatta Basu

Department of Medicine, Jawaharlal Institute of Postgraduate Medical Education and Research (JIPMER), Puducherry-605006

ABSTRACT

We report hemostatic dysfunction in two postmenopausal women presenting with mucosal bleeds secondary to plasma cell dyscrasias. The two postmenopausal women presented with complaints of mucosal bleeds like gum bleed and epistaxis. Peripheral smear examination showed rouleaux formation. After detailed haematological and coagulation work up, one patient was diagnosed as Waldenstro"m macroglobulinemia (WM) with acquired vWD and impaired platelet function. The second patient was diagnosed as Multiple myeloma (MM) with acquired coagulopathy. Evaluation of elderly patients with bleeding manifestations should also include work up ruling out an acquired coagulation abnormality secondary to plasma cell dyscrasia.

Keywords: Bleeding, Dysfunction, Hemostatic, Paraproteinemias, Plasma Cell Dyscrasias

Introduction

Plasma cell dyscrasias are known to be associated with hemostatic abnormalities and venous thromboembolic events. This is due to the complex interaction between plasma paraproteins, platelets, coagulation factors and the inflammatory and hemostatic pathways. Evidence of bleeding, often confined to purpura, epistaxis, or hematuria, manifests in less than 10% of patients with Monoclonal gammopathy of undetermined significance (MGUS), multiple myeloma (MM), Waldenstro"m macroglobulinemia (WM), and primary AL amyloidosis. [1] Bleeding manifestations at presentation are more common with WM (17%), AL amyloidosis (15-41%) followed by MM (7%). [2,3] In this report we discuss two post menopausal ladies who presented with mucocutaneous bleed; the clinicohematological details of these two patients subsequently diagnosed as WM and MM and the hemostatic dysfunctions in them is discussed.

Case Reports

Case 1: A 64 year old post menopausal lady was referred from dental department to the general medicine department with complaints of bleeding gums for the past one month. Dental evaluation was normal. Clinical examination showed pallor and few bleeding points in the gingiva. Systemic examination was normal. The details of the peripheral blood, Bone marrow and coagulation workup is detailed in table 1 and figure 1.

Case 2: A 54 year old post menopausal lady was referred from ENT department to the general medicine department with complaints of epistaxis and nasal block since six months and fatigue since four months. Profuse bleeding after nasal endoscopy was documented. Clinical examination showed pallor, mucosal thickening, crust & bleeding in nasal cavity. Systemic examination was normal. The details of the peripheral blood, Bone marrow and coagulation workup is detailed in table 1.

Table 1: Clinical and laboratory profile of patients.

Parameter	Patient 1	Patient 2
Age/Sex	64/F	54/F
Chief complaints	Bleeding from gums since one month	Epistaxis since 6 months
Clinical examination	Local - few bleeding spots on oral mucosa Systemic examination - normal	Local - Crust and bleeding nasal cavity Systemic examination - normal
Hemogram	Hb-7.5 gm; TLC - 6200/cu.mm; Platelet count - 2.3 lakhs/cumm	Hb- 7.2gm; TLC - 2250/cu.mm; Platelet count - 39000/cu.mm
Peripheral smear	NCNC anemia, Rouleaux + No atypical cells	NCNC anemia, Rouleaux + No atypical cells

Parameter	Patient 1	Patient 2
RFT and LFT	Within normal limits	Within normal limits
Serum Calcium	10.4gm/dl	7.0gm/dl
Bone marrow	Sheets of atypical lymphoid cells. On IHC cells are CD20+ IgM+	Sheets of plasma cells. On IHC, positive for Kappa IgG+
Serum Protein Electrophoresis & Immunofixation	M band – IgM Kappa	M band – IgG Kappa
Coagulation work up	PT – N; APTT – Prolonged and corrected on mixing; FVIII assay – 24%; vWF : Ag assay – 58.36 ng/ml; vWF RiCoF activity – 0%. Decreased aggregation with ADP, ristocetin, epinephrine and collagen	PT and APTT – Mildly prolonged and corrected on mixing No aggregation with collagen and epinephrine. Some aggregation with ADP and ristocetin
Final diagnosis	Waldenstrom macroglobulinemia with acquired vWD and impaired platelet function	Multiple myeloma with acquired coagulopathy

TLC- Total leucocyte count; NCNC – Normocytic normochromic; IHC- Immunohistochemistry; PT- Prothrombin time; APTT- Activated partial thromboplastin time; vWF: Ag – von willebrand factor assay; vWF RiCoF - von willebrand factor ristocetin cofactor activity.

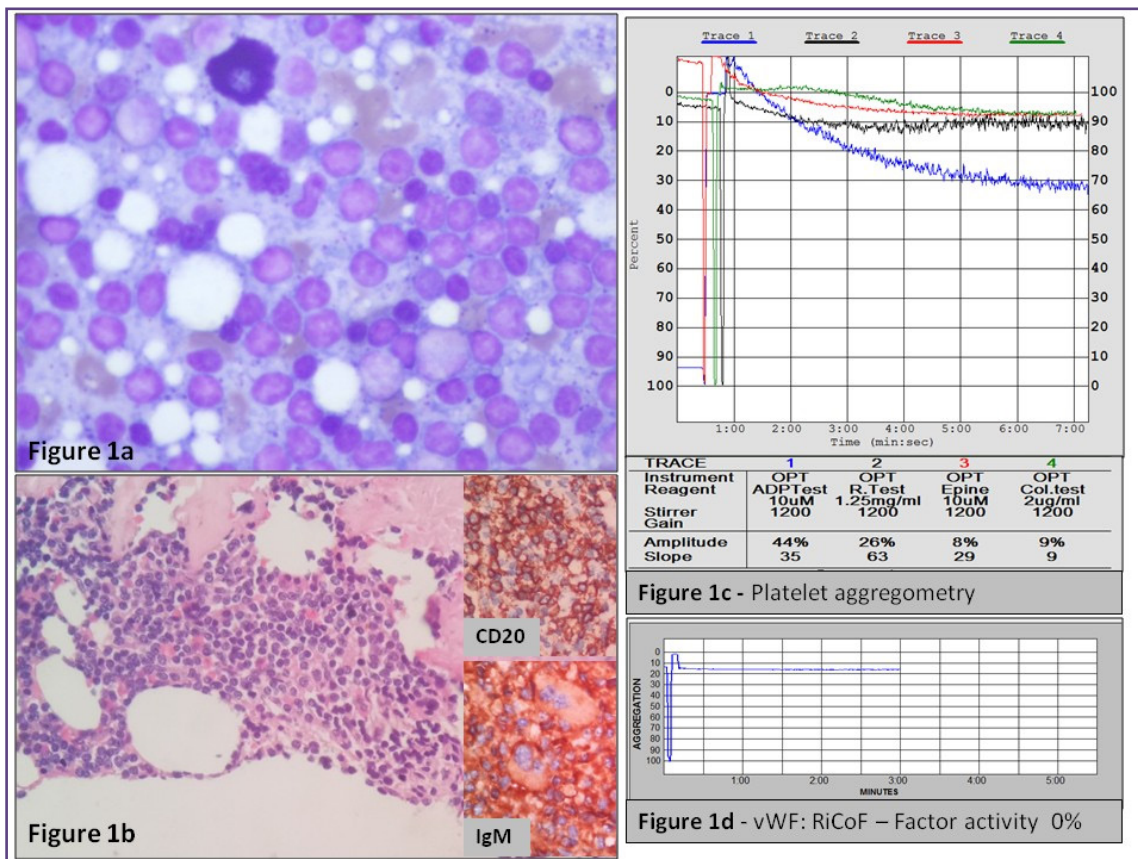


Fig. 1: 1a – BM imprint showing prominence of Atypical lymphoid cells. 1b- BM biopsy showing lymphoid cells positive for CD20 and IgM restricted (400X); 1c – Platelet aggregometry showing reduced aggregation with ADP, ristocetin, epinephrine and collagen. 1d- vWF: RiCoF assay showing absent factor activity.

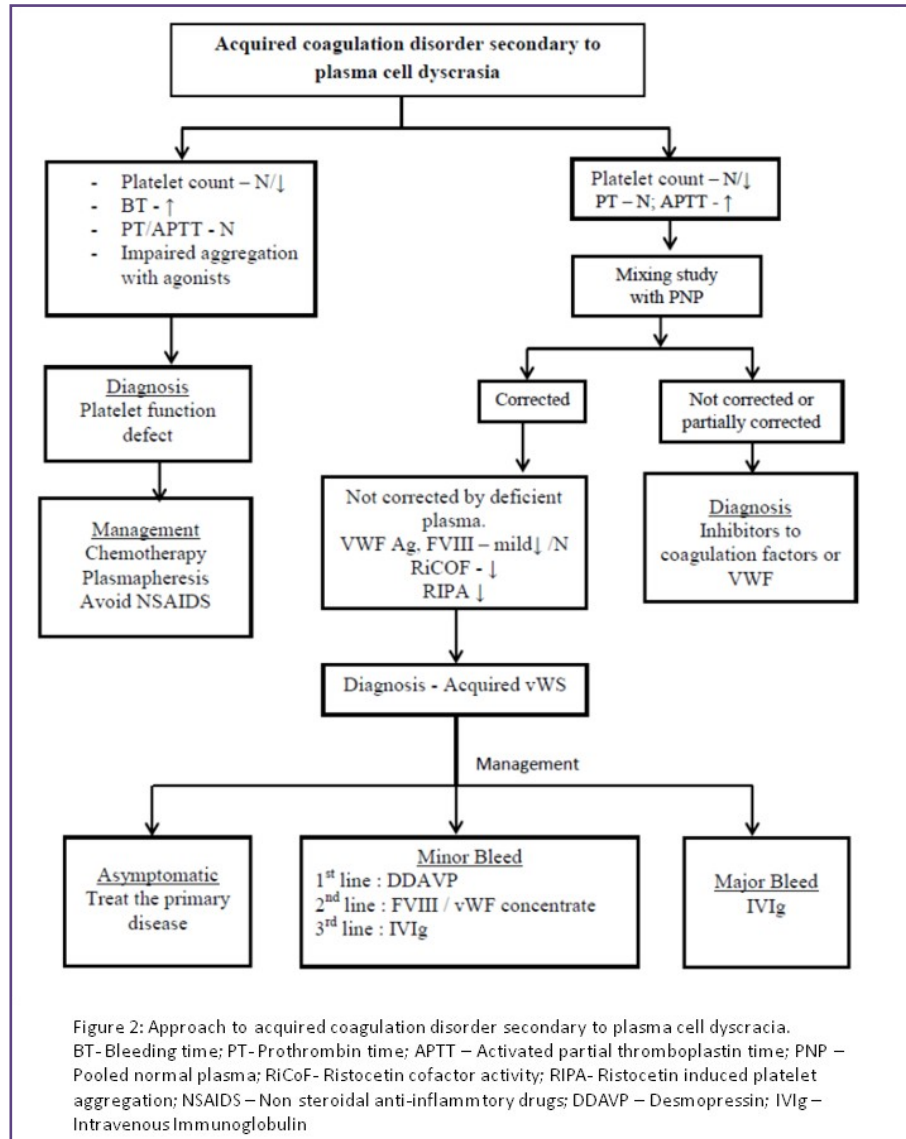


Fig. 2: Approach to acquired coagulation disorder secondary to plasma cell dyscrasias.

Discussion

The haemostatic abnormalities in paraproteinemias occur due abnormalities of primary or secondary haemostasis. Various mechanisms described include - thrombocytopenia, paraprotein-induced platelet function defects, acquired von Willebrand syndrome (AVWS), acquired coagulation factor deficiency, inhibitors to coagulation factors or von Willebrand factor, circulating anticoagulants, abnormalities of the function of fibrin, hyperviscosity, and vascular fragility associated with amyloidosis. Multiple mechanisms may interact to cause the hemostatic defect. [4]

Even if laboratory evidence of a hemostatic defect exists, clinically manifest bleeding complications are uncommon in para proteinemias, and occur in less than 10% cases. [1]

Hemorrhagic symptoms, in particular retinal hemorrhages, epistaxis, and gingival bleeding, are characteristic of the hyperviscosity syndrome, frequently observed in WM and less commonly in MM. [5] Bleeding rates associated with different paraproteinemias are Ig G myeloma (13%), Ig A myeloma (33%), and Ig M WM (36%). [6] Bleeding was not reported as the presenting symptom in many reviews on MM, while a Mayo clinic series of 869 patients spanning 11 years reported an incidence of 7%. [7] Compared to MM, bleeding manifestations at presentation are more common with WM (17%) and AL amyloidosis (15-41%). [2,3]

Mild thrombocytopenia (PLC <100,000/μl) is known to occur in 2.6% cases of MGUS and 5-13% cases of MM, where it is regarded as a risk factor for shorter survival.

^[8,9] Rarely M-proteins can cause pseudo thrombocytopenia. Impaired platelet function, causing clinically significant bleed, prolonged bleeding time or abnormal platelet aggregation studies, can occur associated with elevated serum paraproteins, particularly IgM. This is due to non-specific coating of platelets by paraproteins which interfere with platelet aggregation and rarely due to specific binding of M protein to platelet glycoprotein IIIa and Ib. This mechanism probably enacted in our patient with WM, as evidenced by the decreased aggregation to all the agonists. The most effective management of this situation is initiation of chemotherapy, other option being plasmapheresis. Aspirin and non-steroidal anti-inflammatory drugs (NSAIDS) should be avoided.

Acquired von Willebrand syndrome (AVWS) is known to occur associated with plasma cell dyscrasias. According to the ISTH registry, lymphoproliferative disorders (48%) are the most common cause of AVWS followed by cardiovascular (21%), myeloproliferative (15%), other neoplastic (5%), and autoimmune disorders (2%) disorders. ^[10] Among the lymphoproliferative neoplasms, MGUS is particularly associated with AVWS. Patient may present with muco-cutaneous bleeding, post invasive procedure bleed or may be asymptomatic. There are several mechanisms proposed for the development of AVWS in plasma cell disorders. ^[11]

- (1) Formation of VWF-autoantibody immune complexes that neutralize VWF activity or enhanced vWF clearance by reticuloendothelial cells is the primary mechanism.
- (2) Absorption of vWF onto the surface of lymphoid cells or plasma cells aberrantly expressing vWF receptors for eg; Gp1b receptor.
- (3) Abnormal platelet adhesion due to paraprotein binding to vWF glycoprotein 1b binding domain and
- (4) Paraprotein interference with vWF binding to collagen due to autoantibody activity of M protein to the collagen binding site.

The typical laboratory findings of AVWS are similar to type 2A von Willebrand disease: abnormal bleeding time, markedly reduced VWF activity (ristocetin cofactor or collagen-binding assays), decreased VWF activity-antigen ratio (VWF:RCo/VWF:Ag and VWF CB/VWF:Ag Ratios) absence of large multimers, decreased RIPA (ristocetin induced platelet aggregation), and normal plasma concentrations of VWF propeptide. Factor VIII (FVIII) activity and vWF : Ag concentration may be mild to moderately reduced or normal. *In-vitro* mixing studies, can detect VWF inhibitory antibodies, in a minority of

patients; ELISA based assays detect VWF antibodies in most cases. ^[12] Screening for VWF autoantibodies is recommended, but methods for detection of VWF inhibitor activity or serological evidence of VWF autoantibodies are not standardized. ^[12] Our patient with WM had markedly reduced RiCoF (0%) activity (figure 1d), reduced vWF:Ag concentration and low VWF:RCo/VWF:Ag suggestive of AVWS. Figure 2 explains the laboratory approach to acquired coagulation disorder secondary to plasma cell dyscrasias.

Acquired coagulation defects in plasma cell dyscrasias may be also due to the interference with the function of fibrin. Monoclonal proteins interfere with fibrin monomer polymerization causing abnormal fibrin clot structure and decreased clot retraction. ^[13] Paraproteins with specificity and autoantibody activity for thrombin and factor VIII have been identified in cases of multiple myeloma associated with severe bleeding. Most common coagulation abnormality in plasma cell dyscrasias is asymptomatic prolongation of screening coagulation tests. Asymptomatic prolongations of prothrombin time (PT), activated partial Thromboplastin time (APTT), and thrombin time (TT) were noted in 37-59%, 14-18%, and 71% patients in different case series of multiple myeloma. ^[13] TT and Reptilase time were more frequently found to be prolonged.

A rare cause of bleeding in patients with plasma cell dyscrasias is circulating heparin-like anticoagulants like heparan sulphate and chondroitin sulphate. ^[1,14] Spontaneous or post-procedure bleeding along with prolonged APTT, partially corrected by mixing with normal plasma, prolonged TT, with partial or complete correction with protamine, normal reptilase time, and measurable heparin activity with commercial assays clinches the diagnosis. Another mechanism of mucocutaneous bleeding in plasma cell disorders is the direct injury to vascular walls and perivascular tissues caused by immunoglobulin molecules derived from monoclonal plasma cells. Hyperviscosity syndrome can cause microvascular haemorrhages from oral, gastrointestinal, genitourinary mucosal surfaces, and retinal veins. Symptomatic hyperviscosity occurs in 10–30% of WM patients and 2–6% of MM patients. Apart from the causes discussed above, uraemia, coagulopathies secondary to liver dysfunction, sepsis or drugs should be considered as alternative causes of bleeding. ^[14]

Conclusion

Elderly patients presenting with a bleeding manifestation either of platelet abnormality like or coagulation factor like, has to be thoroughly evaluated to rule out an underlying plasma cell dyscrasia.

Acknowledgements

The authors would like to acknowledge the clinical colleagues and technical staff in the Hematology laboratory at JIPMER.

Funding

No funding is involved as this report deals with documentation of a rare clinical situation

Competing interests

The authors declare no competing interests.

References

1. Zangari M, Elice F, Fink L, Tricot G. Hemostatic Dysfunction in Paraproteinemias and Amyloidosis. *Semin Thromb Hemost.* 2007;33:339-349
2. Kyrtsolis M, Vassilakopoulos T, Angelopoulou M, Siakantaris M, Pangalis G. Waldenstrom's macroglobulinemia: clinical course and prognostic factors in 60 patients. *Annals of Hematology.* 2001; 80: 722-727
3. Mumford A, O'Donnell J, Gillmore J, Manning R, Hawkins P, Laffan M. Bleeding symptoms and coagulation abnormalities in 337 patients with AL-amyloidosis. *Br J Haematol.* 2000;110: 454-460
4. Glaspy JA. Hemostatic abnormalities in multiple myeloma and related disorders. *Hematol Oncol Clin North Am.* 1992; 6:1301-14
5. Gertz MA, Fonseca R, Rajkumar SV. Waldenstrom's macroglobulinemia. *Oncologist.* 2000;5:63-67
6. Perkins H, MacKenzie M, Fudenberg H. Hemostatic defects in dysproteinemias. *Blood.* 1970; 35:695-707.
7. Kyle R. Multiple myeloma - Review of 869 cases. *Mayo Clinic Proceedings* 1975; 50: 29-39.
8. Kyle R, Gertz M, Witzig T, Lust J, Lacy M, Greipp P. Review of 1027 patients with newly diagnosed multiple myeloma. *Mayo Clinic Proceedings* 2003; 78: 21-33.
9. Rossi D, De Paoli L, Franceschetti S, Capello D, Vendramin C, Lunghi M, Conconi A, Magnani C, Gaidano G. Prevalence and clinical characteristics of immune thrombocytopenic purpura in a cohort of monoclonal gammopathy of uncertain significance. *Br J Haematol.* 2006; 138: 249-252.
10. Federici AB, Rand JH, Bucciarelli P, Budde U, van Genderen PJ, Mohri H et al. Acquired von Willebrand syndrome: data from an international registry. *Thromb Haemost.* 2000;84:345-349
11. Franchini M, Lippi G. Acquired von Willebrand syndrome: an update. *Am J Hematol.* 2007;82:368-375.
12. Siaka C, Caron R, Goudemand J. A new ELISA assay for diagnosis of acquired von Willebrand Syndrome. *Haemophilia.* 2003;9:303-308.
13. Eby C. Bleeding and Thrombosis Risks in Plasma Cell Dyscrasias. *Hematology* 2007: 158-164
14. Eby C, Blinder M. Hemostatic complications associated with paraproteinemias. *Current Hematology Reports.* 2003;2:388-394.

*Corresponding author:

J. Sree Rekha MBBS, MD (Pathology), Associate Professor, Department of Pathology, Jawaharlal Institute of Postgraduate Medical Education and Research (JIPMER), Puducherry-605006 INDIA

Phone: +91 8903306817

Email: sree.path177@gmail.com

Financial or other Competing Interests: None.