

# Peripheral Blood Hypereosinophilia Masquerading A Case of Acute Lymphoblastic Leukemia

Suganya Kuppovi-Reddy<sup>1</sup>, Pritinanda Mishra<sup>1</sup>, Maya G<sup>2</sup>, Sajini Elizabeth Jacob<sup>1</sup>, Jyoti W<sup>2</sup>, Abdoul Hamide<sup>2</sup>, Debdatta Basu<sup>1</sup>, Biswajit Dubashi<sup>3</sup>

<sup>1</sup>Department of Pathology, Jawaharlal Institute of Postgraduate Medical Education and Research (JIPMER), Puducherry

<sup>2</sup>Department of Medicine, Jawaharlal Institute of Postgraduate Medical Education and Research (JIPMER), Puducherry

<sup>3</sup>Department of Medical Oncology, Jawaharlal Institute of Postgraduate Medical Education and Research (JIPMER), Puducherry

**Keywords:** *Hypereosinophilia, Acute Lymphoblastic Leukemia*

### ABSTRACT

**Background:** Acute lymphoblastic leukemia (ALL) usually presents with fever, pallor, lymphadenopathy, hepatosplenomegaly and presence of lymphoblasts in the peripheral blood and bone marrow. ALL presenting as peripheral blood hypereosinophilia is a rare entity with less than 50 cases reported since 1973. It is a distinct clinicopathologic entity with specific cytogenetic abnormalities. It is important for clinicians and the pathologists to be aware of the specific manifestation of ALL with eosinophilia. We report a case of ALL with peripheral blood eosinophilia.

**Case Presentation:** A 39 year male presented with fever, cough with expectoration and dyspnoea. There was no past history of allergies, skin rash or parasitic infection. On examination there was hepatosplenomegaly with no lymphadenopathy. Chest X ray showed diffuse reticular pattern throughout the lungs.

Peripheral smear examination revealed high leucocyte count (52,900/mm<sup>3</sup>) with eosinophils constituting 89% (AEC- 47740/mm<sup>3</sup>). No atypical cells or hemoparasites were seen. Stool examination for parasites and filarial serology were negative.

Bone marrow examination, however, showed blasts constituting 90%. Blasts were positive for TdT, CD20, CD10 by immunocytochemistry and a diagnosis of precursor B cell ALL was made. The patient was started on treatment. Cytogenetic analysis was also done.

**Conclusion:** Hypereosinophilia can mask many underlying pathologies, of which ALL is a rare condition. As this condition usually presents with absence of blasts in the peripheral blood, there may be delay in diagnosis. So, in patients with persistent hypereosinophilia where there are no contributory causes, a bone marrow examination is a must for an accurate diagnosis.

**\*Corresponding author:**

Dr. Debdatta Basu, M.D. Professor, Department of Pathology, JIPMER, Puducherry, 605006, India

Phone: +91- 9843158620

E-mail: ddbasu@gmail.com



## Introduction

Severe eosinophilia, defined as eosinophil count  $> 5000/\mu\text{l}$ , can be seen in helminthic infections, allergic disorders, lymphoproliferative disorders, chronic myeloid leukemia, and chronic eosinophilic leukaemia. Lymphoblastic leukaemia of both B and T cell origin may be associated with eosinophilia. Precursor B acute lymphoblastic leukemia with exaggerated eosinophilia is a rare subset with less than 50 cases reported since 1973, when it was first described by Spitzer and Garson.<sup>[1]</sup> Most cases of ALL with eosinophilia are characterised by presence of increased number of circulating eosinophils, in the absence of blasts in peripheral smear. Thus the paucity of blasts in the peripheral blood may lead to misdiagnosis of this entity. The most common cytogenetic abnormality encountered in acute lymphoblastic leukemia with eosinophilia is  $t(5;14)$ , and is characterized by overproduction of IL-3.<sup>[2]</sup> This entity is now included in WHO 2008 as 'B lymphoblastic leukemia/lymphoma with  $t(5;14)$ ; IL3-IGH'.<sup>[3]</sup> ALL with eosinophilia is more refractory to treatment than standard leukaemia.<sup>[4][5]</sup> So, timely diagnosis of this rare entity is important as this is associated with poor prognosis.

In the following case report, diagnosis and management of an adult male is discussed who suffered from precursor B acute lymphoblastic leukemia with severe eosinophilia.

## Case Presentation

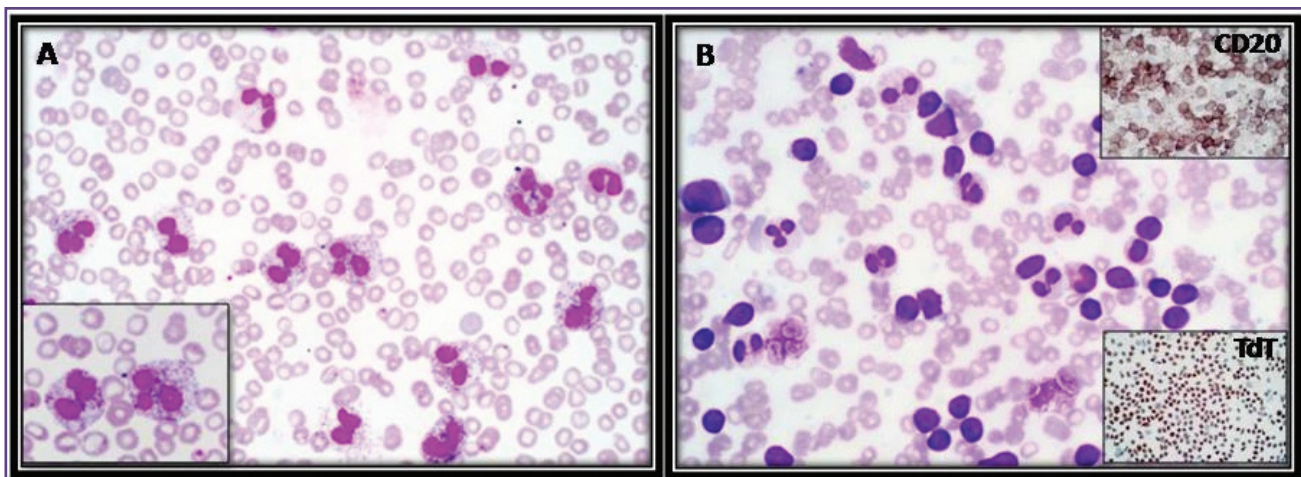
A 39 year male who was an agricultural worker by occupation presented with fever, cough with expectoration and dyspnoea for 20 days. He also suffered from abdominal

pain, myalgia, easy fatigability for 4 days. There was no past history of allergies, skin rash or parasitic infections. There was no history of any drug intake.

On physical examination, the patient had laboured breathing with respiratory rate of 56/min and a blood pressure of 130/90 mm of Hg. No purpuric rashes were noted. On palpation of the abdomen there was no hepatosplenomegaly. No significant lymph nodes were detected. Cardiovascular and central nervous system examination were found to be within normal limits.

Chest X ray done showed a diffuse reticular pattern throughout the lungs, which was maximum at the bases. Ultrasonography revealed mild hepatosplenomegaly. Echo cardiogram was done which showed normal valves and chambers, left ventricular function was normal with an ejection fraction of 60%. Stool examination and filarial serology were negative. Blood culture, Widal test, test for typhus fever, HBs Ag, HIV test was negative. Total protein was 6.6 g/dl, albumin 3.4 g/dl. Serum electrolytes and liver function test were within normal limits.

Peripheral smear findings: Full blood examination on admission revealed a haemoglobin of 8.9g/dl, white cell count of  $52,900/\text{mm}^3$  with a differential of 89% eosinophils (AEC-  $47,740/\text{mm}^3$ ), 02% neutrophils, 09% lymphocytes and a platelet count of  $64,000/\text{mm}^3$ . Some of the eosinophils had trilobed and multilobed nucleus with variation in the staining of the granules. Few eosinophils also showed cytoplasmic vacuolations. (Fig 1)



**Fig. 1 A:** Peripheral smear: Hypereosinophilia with an AEC of  $47740/\text{mm}^3$  (Leishman stain  $\times 400$ ) Lower left insert - Morphological variation in eosinophils - varied staining of the granules with cytoplasmic vacuoles, eosinophils with trilobed nucleus (Leishman stain,  $\times 1000$ )  
**B:** Hypercellular marrow particles with 90% blasts and few eosinophils (Giemsa  $\times 400$ ) Blasts showing positivity for TdT (lower right) and CD20 (upper right) (IHC  $\times 400$ )

Bone marrow findings: Bone marrow aspirate was done and, to our surprise, it showed a hypercellular marrow constituting mainly of blasts with few mature eosinophils. These blasts showed a high nuclear cytoplasmic ratio, irregular nuclear membrane, 1-2 prominent nucleoli and agranular cytoplasm. There was suppression of trilineage hematopoiesis with marrow differential count of 90% blasts, 5% eosinophils, 1% neutrophils, 2% metamyelocyte, 1% erythroid, 1% mast cell. Cytochemistry was performed & the blasts were negative for Sudan Black B. Immunocytochemistry was done and the blasts were positive for TdT, CD 10, CD 20 and negative for CD 3. Based on the bone marrow examination findings a diagnosis of ALL with peripheral eosinophilia was made.

Karyotyping: Cytogenetic analysis revealed 47,XY,+X,del(5)(q13q33),der(14)t(?;14)(?;q32) or add(14)(q32)[3]/46,XY[17]

Three of the 20 metaphases are abnormal and show moderate hyperdiploidy (chromosome number 47) due to gain of an X chromosome as well as a partial deletion of the long (q) arm of chromosome 5. There was also an abnormal chromosome 14q either derived from a translocation with an unknown partner chromosome or due to addition of material of uncertain origin to band q32.

Treatment: The height and weight of the patient was 195 cm and 84 kg, respectively, and the body surface area was 2.13 m<sup>2</sup>. He was started on induction therapy based on GMALL protocol consisting of four drugs regimen, which included Inj Vincristine 1.5 mg/m<sup>2</sup> IV on day 1, 8, 15 and 22; Inj Daunorubicin 25 mg/m<sup>2</sup> IV on day 1, 8, 15 and 22; Tab Prednisolone 60 mg/m<sup>2</sup>/day × 28 days and Inj Asparaginase 5000 units/m<sup>2</sup> IM on days 2, 4, 6, 8, 10, 12 and 14.

Follow up: Haematological profile during the course of treatment is summarised in table 1. Post induction bone

marrow was in remission and showed only erythroid hyperplasia with absence of blasts and eosinophils. During the course of treatment the patient developed L-asparaginase induced left femoro- popliteal deep vein thrombosis which subsided on treatment. After 6 months of therapy, he developed CNS involvement and succumbed to death.

## Discussion

The eosinophil count in a normal adult ranges from 0.02–0.5 × 10<sup>9</sup>/l (20–500/μl).<sup>[6]</sup> Eosinophilia is classified as mild (0.5–1.5 × 10<sup>9</sup>/l), moderate (1.5–5 × 10<sup>9</sup>/l) and severe when the eosinophil count is more than 5 × 10<sup>9</sup>/l. Our patient had severe eosinophilia.

Patients with hypereosinophilia usually presents with signs and symptoms of organ involvement due to eosinophilic organ infiltration. Organs involved are most commonly the heart, lungs, central nervous system, skin, liver, and spleen. Our patient presented with respiratory distress. There was no evidence of other organ involvement, as shown by normal echocardiography. No neurological deficits or skin rash were seen. Different causes of eosinophilia were excluded based on various clinical and laboratory investigations. His complete blood count revealed hypereosinophilia in the absence of blasts. However a bone marrow was advised considering the severe eosinophilia, abnormalities in the morphology and granules of eosinophils and thrombocytopenia. Bone marrow showed 90 % blasts.

Chronic myeloid leukemia, acute myeloid leukemia with inv (16) or t(16;16), chronic eosinophilic leukemia, myeloid & lymphoid neoplasms with eosinophilia and PDGFRA, PDGFRB and FGFR1 can present with eosinophilia but they usually have blasts in the peripheral blood.

Acute lymphoblastic leukemia can present with peripheral hypereosinophilia with paucity of blasts and it can be associated with cytogenetic abnormalities like t (5;14)

**Table 1: Haematological findings at admission and during the course of treatment**

	Parameters	At admission	1 week	2 weeks	28th day
<b>Peripheral smear</b>	Hemoglobin (g%)	8.9	8.7	8.4	6.9
	Total WBC (/mm <sup>3</sup> )	52900	6700	1600	2900
	Platelet (/mm <sup>3</sup> )	64,000	60,000	23,000	1,68,000
	Eosinophils (%)	89	47	Nil	Nil
	AEC (/mm <sup>3</sup> )	47,740	3240	Nil	Nil
	Blasts	Nil	Nil	Nil	Nil
<b>Bone marrow</b>	Cellularity	Hypercellular	-	-	Normocellular
	Blasts	90%	-	-	Nil
	Hematopoiesis	Trilineage suppression	-	-	Erythroid hyperplasia

(q31;q32);<sup>[2]</sup> 45,XY,t(7;12)(q22;p13),-9;<sup>[7]</sup> hyperdiploidy with 5q deletion<sup>[8]</sup> or normal karyotype.<sup>[9]</sup> The common cytogenetic abnormality associated with B lymphoblastic leukemia with eosinophilia is t(5;14);IL3-IGH. In this translocation, eosinophilia is secondary to overproduction of interleukin-3 by the blasts, due to activation of interleukin-3 gene on chromosome 5 after its translocation adjacent to the immunoglobulin heavy chain gene on chromosome 14. Another possible mechanism explained by Hamilton Fairley for eosinophilia in these patients is cell-mediated response to the “tumor-specific antigen.”<sup>[1]</sup>

Eosinophilia in these patients are considered to be reactive and not leukemic. This is suggested by the cytogenetic finding in the study done by Gary Spitzer and O. Margaret Garson. They showed that cytogenetically these eosinophils had normal chromosomal constitution in contrast to the blasts that possessed an abnormal aneuploid karyotype. Eosinophilia usually disappears during remission and their reappearance in the peripheral blood may suggest relapse.

Our patient showed moderate hyperdiploidy due to gain of an X chromosome as well as a partial deletion of the long (q) arm of chromosome 5. 5q deletion with hyperdiploid blast population was described in a study by Wynn et al<sup>[8]</sup> in a 5 year old girl with ALL and peripheral hypereosinophilia.

During the course of treatment our patient developed L- asparaginase induced right popliteal and left femoro popliteal deep vein thrombosis which recovered following treatment. L-asparaginase should be used cautiously in chemotherapy regimen of ALL with eosinophilia because of the risk of thromboembolic events. These are triggered by synergistic procoagulant effect of this drug and eosinophilia.<sup>[10],[11]</sup>

## Conclusion

Hypereosinophilia can mask many underlying pathologies, of which ALL is rare condition. As this condition usually presents with absence of blasts in the peripheral blood, there may be delay in diagnosis. So, in patients with persistent hypereosinophilia where there are no contributory causes, a bone marrow examination is a must for an accurate diagnosis.

## Acknowledgment

We thank the cytogenetics unit, Christian Medical College Vellore who provided us, the cytogenetic analysis of the patient.

## References

1. Spitzer G, Garson OM. Lymphoblastic leukemia with marked eosinophilia: a report of two cases. *Blood*. 1973;42:377–84.
2. Grimaldi JC, Meeker TC. The t(5;14) chromosomal translocation in a case of acute lymphocytic leukemia joins the interleukin-3 gene to the immunoglobulin heavy chain gene. *Blood*. 1989;73(8):2081–5.
3. Vardiman JW, Thiele J, Arber DA, Brunning RD, Borowitz MJ, Porwit A, et al. The 2008 revision of the World Health Organization (WHO) classification of myeloid neoplasms and acute leukemia: rationale and important changes. *Blood*. 2009;114(5):937–51.
4. Gharabaghi MA, Aghajanzadeh P, Zahedi G, Borji R, Derakhskan L, Sattarzadeh R, et al. Cardiac disease in a case of precursor B acute lymphoblastic leukaemia with eosinophilia(ALL/Eo). *BMJ Case Rep*. 2012;2012.
5. Rezamand A, Ghorashi Z, Ghorashi S, Nezami N. Eosinophilic presentation of acute lymphoblastic leukemia. *Am J Case Rep*. 2013;14:143–6.
6. Lewis M: Reference ranges and normal values. In *Dacie and Lewis Practical Haematology* 10th edition. Edited by: Lewis SM, Bain BJ, Bates I. Churchill Livingstone; 2006:11-24.
7. Bhatti FA, Hussain I, Ali MZ. Adult B lymphoblastic leukaemia/lymphoma with hypodiploidy (-9) and a novel chromosomal translocation t(7;12)(q22;p13) presenting with severe eosinophilia - case report and review of literature. *J Hematol Oncol*. 2009;2:26.
8. Wynn TT, Heerema NA, Hammond S, Ranalli M, Kahwash SB. Acute lymphoblastic leukemia with hypereosinophilia: report of a case with 5q deletion and review of the literature. *Pediatr Dev Pathol*. 2003;6(6):558–63.
9. Jain P, Kumar R, Gujral S, Kumar A, Singh A, Jain Y, et al. Granular acute lymphoblastic leukemia with hypereosinophilic syndrome. *Ann Hematol*. 2000;79(5):272–4.
10. Williams E, Smart SC, Go RS. Catastrophic thromboembolism in a patient with acute lymphoblastic leukemia and hypereosinophilia. *Haematologica*. 2004;89(4):EIM01.
11. Gharabaghi MA, Aghajanzadeh P, Zahedi G, Borji R, Derakhskan L, Sattarzadeh R, et al. Cardiac disease in a case of precursor B acute lymphoblastic leukaemia with eosinophilia(ALL/Eo). *BMJ Case Rep*. 2012;2012.