

## Lipoma of Parotid Gland : A Rare Case

Sonia Verma\*, Alekh Saxena, Mansi Faujdar and Shubha Gupta

Santokba Durlabhji Memorial Hospital, Jaipur, India

### ABSTRACT

Lipoma is a common benign tumour which is mesenchymal in origin and arises in every location where fat is normally present. Their occurrence in the head and neck is rare in the first place, even more at the level of parotid region where they may occur adjacent to the parotid capsule, inside the capsule or within the substance of the gland. The clinical diagnosis is generally difficult probably due to low index of clinical suspicion. The preoperative imaging plays a crucial role to correctly diagnose the nature of the lesions as well as to exclude extra parotid subcutaneous lesions but histopathology makes the final diagnosis. The present case is of a 57 year old male who presented to the surgical outpatient department with a painless swelling in left parotid region.

**Keywords:** Salivary Gland, Lipoma, Salivary Gland Lipoma, Benign Salivary Gland Tumour, Parotid Lipoma

### Introduction

Lipoma is a common benign tumour which is mesenchymal in origin and arises in every location where fat is normally present, 13% of these occur in the head and neck region. Rarely, Lipoma can arise in the oral cavity, pharynx, larynx and parotid gland.<sup>1</sup> Their occurrence in the head and neck is rare in the first place, even more at the level of the parotid region where they may occur adjacent to the parotid capsule, inside the capsule, or within the substance of the gland.<sup>2</sup> The incidence of lipoma among parotid tumours ranges from 0.6% to 4.4%, with most series reporting an incidence of 1%.<sup>3</sup> Over a period of two decades, only two cases of parotid lipoma were reported from India<sup>4</sup> and one from Pakistan.<sup>5</sup> Concerning the age of onset, lipoma are most common from the fifth to the sixth decades of life. Those in deep lobe have been reported to be highest in fourth decade.<sup>4</sup> Recently, improved preoperative evaluation techniques, including the use of computed tomography (CT), magnetic resonance imaging (MRI), and fine-needle aspiration (FNA), have enabled a more accurate assessment of these tumors and a rational approach to their management.<sup>6</sup> Surgical excision of these tumors is always necessary for definitive diagnosis<sup>7</sup>, but it is challenging because of the facial nerve which courses throughout the parotid gland and could be damaged during surgery if not performed traditionally and by experienced hands.

### Case Report

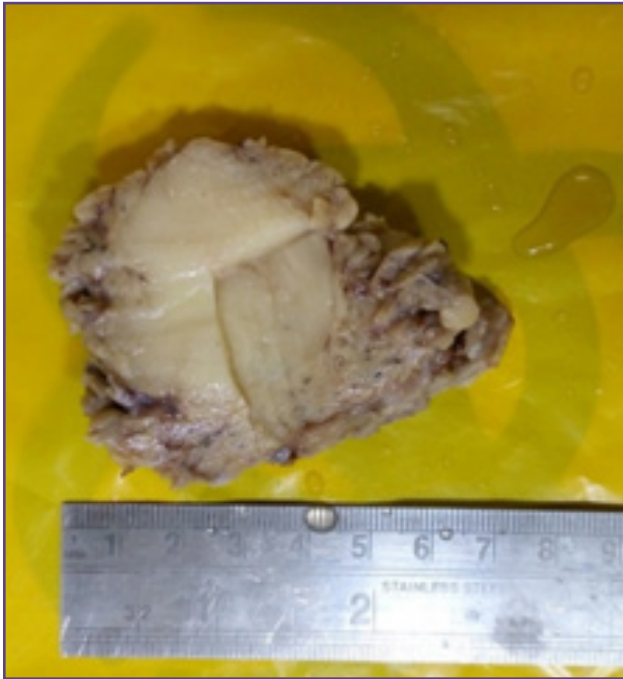
We present the case of a 57 year old male, who presented to the surgical outpatient department of Santokba Durlabhji Memorial Hospital with a painless swelling in the left parotid region. He observed an increase in size of the swelling over the years. On physical examination, swelling

was soft, non-tender, and relatively mobile located over the region of the left parotid gland. The overlying skin was normal without any sign of discoloration or ulceration. The examination of either the neck or the facial nerve function was unremarkable. The contrast enhanced high resolution CT scan showed a homogenous lobulated low-density mass in the superficial left parotid gland. The mass depicted the same density as fatty tissue. On MRI, T1- and T2-weighted images (MRIs) showed a well-defined lesion in the superficial lobe of the right parotid gland. This was bright on both T1- and T2-weighted sequences. The lesion was well circumscribed did not appear to extend from the superficial to the deep lobe of the parotid gland. Therefore, a clinical diagnosis of lipoma was made and a superficial parotidectomy was done. The sample was sent to the department of pathology with the relevant clinical details for histopathological examination.

On gross examination of the sample (Fig. 1), the specimen consists of single soft tissue mass measuring 6x5x4cms. Mass was exposed on all surfaces except at one surface covered with fibro fatty tissue. On sectioning, a well circumscribed fibro fatty nodule was identified measuring 5x4 cm in diameter. Cut surface of nodule was fibro fatty to greyish yellow. Normal looking Parotid parenchyma was identified at periphery. On microscopic examination, the nodule was composed of mature fat cells only. No evidence of malignancy or granuloma was found. The nodule was completely surrounded by salivary gland tissue (Fig. 2 & 3). Therefore, the histopathological examination confirmed the clinical diagnosis of lipoma.

### Discussion

Lipoma is the most common benign mesenchymal encapsulated tumours, histologically similar to mature



**Fig. 1: Specimen of superficial parotidectomy exhibiting a well-defined fibrofatty nodule.**

adipose tissue. Rarely, they can arise from the parotid gland; the reported incidence varies from 0.6% to 4.4%, with most series reporting an incidence of 1%.<sup>1-3</sup> Lipoma is rare in the first two decades of life, usually developing in the fifth and sixth decades when fat begins to accumulate in inactive, under exercised individuals. In general, the tumour is more common in obese people and can increase in size during a period of rapid weight gain; however, after the initial growth period most lipoma increase little in size. Conversely, in cachectic patients or during periods of starvation, the size of the lipoma is rarely affected, which suggests that the fat in these lesions is largely unavailable for the general metabolism.<sup>8</sup>

The highest reported incidence of lipoma in the parotid gland is 4.4%, with males most frequently affected with a sex ratio of 5:1.<sup>9,10</sup> Though in the current patient, lipoma in the parotid gland presented as a single lesion without any predisposing factor, in few cases trauma and lipoma are found to be most frequently correlated on clinical history. Trauma to soft tissue has been hypothesized to result in haematoma, with subsequent lymphatic effusion, fat necrosis and lipoma formation located in the subcutaneous plane.<sup>9</sup> Usually intraparotid lipoma occur in the superficial lobe in 75% of cases as in our case, while in the deep lobe extending to the parapharyngeal space in 8.5% of cases and both in the deep and superficial lobe on the inferior part of the gland in 16.5% of cases.<sup>10</sup> They progress

asymptotically until reaching a large size. Clinically, the parotid lipoma appears as soft, slow growing, painless, well delineated asymptomatic mass.<sup>11</sup> The clinical diagnosis is generally difficult, probably due to low index of clinical suspicion.<sup>11</sup>

Nowadays, the preoperative imaging plays a crucial role to correctly diagnose the nature of lesions. Its main function is to eliminate extra-parotid subcutaneous lesions, and secondly to confirm the diagnosis of lipoma.<sup>10</sup> Like in the current case a correct clinical and instrumental evaluation of parotid gland mass was done using both CT scan and MRI, and lead to a successful pre-operative diagnosis of lipoma. These two methods are well-established imaging procedures and are helpful in giving information about pathological features of the tumour, to evaluate the location of the tumour and to program the correct surgical approach. CT shows a hypodense and homogeneous mass with few septations and less than water density.<sup>9</sup> However, CT scan does not help much in differentiation of lipoma from surrounding adipose tissue. Therefore, to procure this information MRI scan was ordered, which clearly delineated the lipomatous nodule from the parotid parenchyma and from the adjoining adipose tissue thus proved the ideal radiological investigation for this tumour.<sup>11</sup> The normal parotid gland has a high fat content and is easily visualized on both CT and MRI, and therefore both techniques can demonstrate whether a mass in that region is intra glandular or extra glandular.<sup>12</sup>

Macroscopically, these are well-circumscribed yellowish tumours. Occasionally, an intra-capsular lipoma may be associated with intra-capsular degeneration of the gland. Salivary gland lipoma is similar to other lipoma and may have an incomplete rim of atrophic salivary gland parenchyma. Variants of ordinary lipoma (e.g. spindle cell lipoma, angio lipoma, and pleomorphic lipoma) are extremely rare.<sup>13</sup> Microscopically, these lesions can demonstrate a range of non-oncocyctic to oncocyctic features.<sup>13</sup> They contain lobules of parotid parenchyma with evenly interspersed adipose tissue and occasionally focal sebaceous differentiation.<sup>14</sup> The differential diagnoses include other salivary gland tumours with lipomatous metaplasia (e.g. pleomorphic adenoma and myoepithelioma) and atrophic salivary gland parenchyma<sup>13,14</sup>. All cases are cured by excision with no reported recurrences.

## Conclusion

The clinical diagnosis is generally difficult due to rare occurrence and low index of clinical suspicion. In such a situation, imaging and histopathological examination seems to be useful. Therefore surgical excision is always necessary for definitive diagnosis with rare chances of recurrences.

## Reference

1. Som PM, Scherl MP, Rao VM, Biller HF. Rare presentations of ordinary lipomas of the head and neck: a review. *AmJNeuroradiol*1986;7:657-64.
2. Payne RT. A case of lipoma of the parotid gland. *Br Med J* 1952;2:865-6.
3. Korentager R, Noyec AM, Chapnik JS, Steinhard M, Luk SC, Cooter N. Lipoma and liposarcoma of the parotid gland: high resolution preoperative imaging diagnosis. *Laryngoscope* 1988;98:967-71.
4. Nanavati SD. Lipoma of the parotid gland. A case report. *J Indian Dent Assoc*1983;55:441-3.
5. Muzaffar S, Kavani N, Hasan SH. Parotid gland lipoma—a rare entity. *J Pak Med Assoc*1996;46:262-3.
6. Ulku, C.U. and Uyar, Y. (2004) Parapharyngeal Lipoma Extending to Skull Base: A Case Report and Review of the Literature. *Skull Base*, 14, 121-5.
7. Som PM, Scherl MP, Rao VM, Biller HF. Rare presentations of ordinary lipomas of the head and neck: A review. *J LaryngolOtol*2006;120:47-55.
8. Barnes L. *Surgical pathology of the head and neck*, Vol. 1. New York: Dekker, 1985:747-58
9. Dispenza, F., De Stefano, A., Romano, G. and Mazzoni, A. (2008) Post-Traumatic Lipoma of the Parotid Gland: Case Report. *Acta Otorhinolaryngologica Italic*, 28, 87-8.
10. Fakhry N et al. Is Surgical Excision of Lipomas Arising from the Parotid Gland Systematically Required? *European Archives of Oto-Rhino-Laryngology* 2012.269, 1839-44.
11. Chakravarti, A., Dhawan, R., Shashidhar, T.B., Shakuntala and Sahni, J.K. (2008) Lipoma of the Deep Lobe of ParotidGland—A Case Report and Review of Literature. *Indian Journal of Otolaryngology and Head Neck Surgery*, 60, 194-6.
12. Cummings, C.W. *Cummings Otolaryngology: Head & Neck Surgery*. Vol. 2, Chapter 60: Benign Neoplasms of the Salivary Glands. 2005. 4th Edition, Elsevier Mosby.
13. Agaimy A Fat-containing salivary gland tumors: a review. *Head Neck Pathol*.2013. 7 Suppl1:S90-6.
14. Jang YW, Kim SG, Pai H, Park JW, Lee YC, Rotaru H. Sialolipoma: case report and review of 27 cases. *Oral Maxillofac Surg*.2009. 13:109-13.

**\*Corresponding author:**

**Dr. Sonia Verma**, B-16, Muraria Bhawan, Bajaj Nagar, Jaipur, Rajasthan – 302015, INDIA

**Phone:** +91 , 918239345304 / 919549249552

**Email:** sonamuraria111@gmail.com

**Financial or other Competing Interests:** None.