

## Colorectal Carcinoma in A 12Year Old Child- A Case Report

Gunjan Bhatia\*, Namita Goyal and Sunita Bhargava

Dept of Pathology, RNT Medical College, Udaipur, INDIA

### ABSTRACT

Colorectal carcinoma is a rarely seen malignancy among children. The prognosis of colorectal carcinoma is poorer among children as compared to adults due to lack of awareness among treating pediatricians and surgeons regarding this entity. A 12 year old female child presented with complaints of recurrent abdominal pain, fullness of abdomen, poor appetite since last 2 years. Abdominal ultrasound was suggestive of a mass arising from the right hypochondrium. Colonoscopy and biopsy confirmed the diagnosis of adenocarcinoma. The possibility of colorectal carcinoma as a differential diagnosis should always be considered in a child who presents with signs and symptoms of intestinal obstruction, intractable abdominal pain, altered bowel habits, long standing abdominal distension and gastrointestinal bleeding. Colorectal carcinoma should not be excluded as a possibility only based on patient's age.

**Keywords:** *Colorectal Carcinoma.*

### Introduction

Colorectal carcinoma is a common visceral malignancy in adults, the incidence being higher in Northwest America and Europe while its incidence is low in African and Asian nations. The incidence of colorectal adenocarcinoma in children is less than 1 case per million individuals.<sup>[1]</sup> It carries a poorer prognosis in children as compared to adults because of lack of awareness among treating pediatricians and surgeons regarding this entity in children and also because of the advanced stage at presentation. In contrast to adult patients in whom a predisposing history of familial polyposis, ulcerative colitis or a family history of colorectal cancer in a relative can be found, most pediatric colonic adenocarcinoma develops in a previously normal colon. We report a case of mucinous adenocarcinoma in a 12 year old child.

### Case report

A 12 year old female child presented with complaints of loss of appetite, recurrent abdominal pain, abdominal fullness and altered bowel habits since last two years however there was no complaints of vomiting. There was no past history or family history pertaining to gastrointestinal complaints. The patient had taken multiple OPD treatments for recurrent abdominal pain and constipation. General examination of the patient revealed pallor, weight loss and glossitis. There was no evidence of icterus, lymphadenopathy, edema and clubbing. Systemic examination revealed a mass 8cm \* 8cm present in right hypochondrium extending to right lumbar region showing normal overlying skin with no redness or local increase of temperature. The mass was

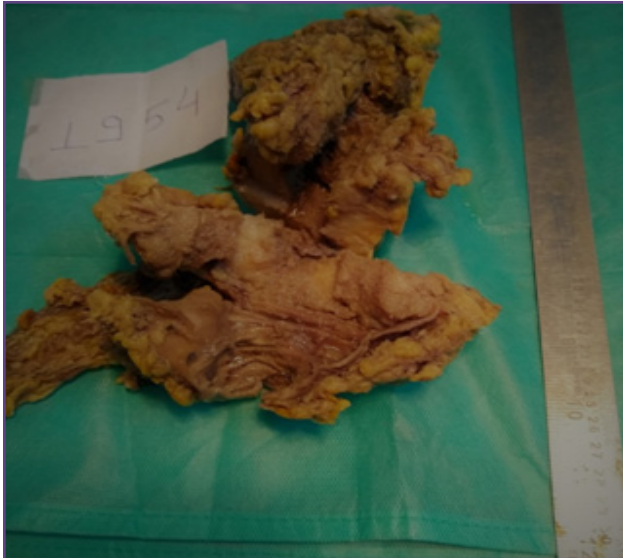firm in consistency, with regular margins, non-tender, non-pulsating. Investigations were Hb of 9.4gm%, TLC, platelet count were normal. Renal function tests, liver function tests, urine examination were normal. Stool examination revealed microscopic RBC. X-Ray chest, ECG was normal. Abdominal USG revealed a solid mass of 7.5\*7.5 cm, extending from the right hypochondrium to the right renal region. CT abdomen revealed segmental circumferential homogeneously enhancing mucosal wall thickness involving the distal ascending colon, hepatic flexure and proximal transverse colon with adjacent mesenteric fat streaming suggestive of neoplastic bowel wall thickening.

On colonoscopy the ascending colon showed a large ulcerated polypoidal mass just below the hepatic flexure which was obliterating the lumen almost to half, highly suspicious of malignancy.

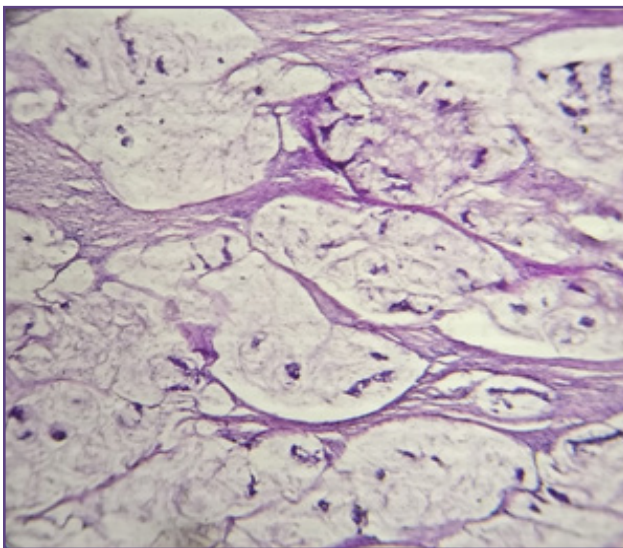
Exploratory laparotomy was done operative findings were noted. A 7.5cm\*5.5cm\*2.0 cm size diffuse circumferential growth was present in distal ascending colon, hepatic flexure and proximal transverse colon. Rt hemicolectomy was done. Specimen was sent for histopathological analysis.

On gross examination (Fig 1.) specimen of large intestine measuring 14 cm in length showed a 7\*5.5\*2.0cm size, grayish white firm mass with normal appearing segment of terminal ileum, appendix and caecum. Tumor mass was involving the bowel wall circumferentially and was reaching upto muscle layer, there was no evidence of tumor site perforation.

Histopathological examination (Fig 2.) revealed groups as well as scattered malignant cells with a moderate degree of atypia and pleomorphism within the mucin lakes. The histopathological findings were consistent with a diagnosis of well differentiated mucinous adeno carcinoma. There was evidence of invasion upto the muscle layer. Ten lymphnodes were resected in adjacent fat and all were negative for metastasis. TNM staging of tumor was stage 1 (T2 N0MX). The patient was treated as per standard guidelines.



**Fig. 1: Specimen of the resected colon on gross examination showing grey white tumor in the colon and is involving the muscle layer.**



**Fig. 1: Specimen of the resected colon on gross examination showing grey white tumor in the colon and is involving the muscle layer.**

## Discussion

Colorectal carcinoma is one of the most frequent tumors in adults. The age-adjusted annual incidence rate is 0.31 per million per year in the age range 0-19 years.<sup>[2]</sup> In spite of its rarity colorectal carcinoma accounts for the most common solid malignancy of gastrointestinal tract in children.<sup>[3]</sup> In pediatric age group Colorectal carcinoma is more frequently seen among males as compared to females.<sup>[4]</sup>

Colorectal carcinoma in children usually presents with abdominal pain mostly localized to peri umbilical and epigastric region which is often difficult to distinguish from recurrent abdominal pain. Recurrent abdominal pain is mostly functional in children which often leads to delay in diagnosis as many of colorectal carcinoma pediatric patients might present in a similar fashion.<sup>[5,6]</sup> Colorectal carcinoma in pediatric population appears to be more aggressive, presents at a later stage and is supposed to have poorer pathological findings.

However our case was diagnosed relatively at an earlier stage and the tumor had well differentiated morphology. Most children with Colorectal carcinoma present with symptoms suggestive of a metastatic spread, either as a gross tumor deposit or as microscopic deposit in lymphnode, on surface of bowel or on intra abdominal organs.

Mucinous Colorectal carcinoma is the most common histological type of colorectal adenocarcinoma seen in pediatric age group. Ferrari et al have reported 7 cases of adenocarcinoma among children, out of which 4 were mucinous type.<sup>[7]</sup> Sharma et al reported two cases of well differentiated mucinous adenocarcinoma in less than 14 year old children.<sup>[8]</sup> Children/adolescents had more unfavorable histotypes (i.e. mucinous adenocarcinoma [22%] and signet ring cell carcinoma [18%]) when compared with adult (10% and 1%, respectively).<sup>[9]</sup> The higher frequency of mucinous histology among children is suggestive of the fact that histology of colorectal carcinoma is different among children as compared to adults. It is interesting to note that in most of the children reported from India, the carcinoma was seen to involve the left colon or rectum contrary to the experience from western world where half the patients have malignancy originating from the right colon.<sup>[10,11,12]</sup> In our patient the malignancy was seen originating from the right hepatic flexure.

Curative surgical excision is the primary treatment of childhood colorectal carcinoma, due to relative decreased incidence of the tumor among pediatric population, treatment guidelines are primarily extrapolated from adult ones.

## Conclusion

Colorectal carcinoma is rare among pediatric population. Delayed diagnosis, advanced stage at presentation and mucinous histology are major determinants of poor outcome in patients of childhood colorectal carcinoma. The possibility of colorectal carcinoma as a differential diagnosis should always be considered in a child who presents with signs and symptoms of intestinal obstruction, intractable abdominal pain, altered bowel habits, long standing abdominal distension and gastrointestinal bleeding. Colorectal carcinoma should not be excluded as a possibility only based on patient's age.

We have reported this case to sensitize our fellow pathologists, pediatricians and surgeons to this entity not commonly seen in pediatric population.

## References

1. Rao BN, Pratt CB, Flemming ID, Dilawari RA et.al. Colon carcinoma in children and adolescents- A review of 30 cases. *Cancer*; 55(6)(1985):pp 1332-1326.
2. Pratt CB, George SL et.al. Epidemic colon cancer in children and adolescence. In: Correa P, Haenszel W, eds. *Epidemiology of Cancer of the Digestive Tract*. Hague/Boston/London: Martinus Nijhoff, 1982: 127-45.
3. Wyllie R, Hyams JS, Kay M, editors. (eds) *Pediatric Gastrointestinal and Liver Disease*. 4th ed. Philadelphia: Saunders; 2011.
4. Middlekamp JN, Haffner H. Carcinoma of the colon in children. *Pediatrics* 1963; 32: 558-71. 12 Van Langenberg A, Ong GB. Carcinoma of the large bowel in the young. *BMJ* 1972; 3: 374-6.
5. Pratt CB, Rivera G, Shanks et.al. Colorectal carcinoma in adolescents implications regarding etiology. *Cancer*;40(Suppl. 5) (1977):pp. 2464-2472.
6. Karnak I, A.O Ciftci, M.E. Senocak, N Buyukpamukcu et.al. Colorectal carcinoma in children. *J Pediatr Surg*; 34(10) (1999):pp. 1499-1504.
7. Ferrari A, Rognone A, Casanova M, Zaffigani E, Piva L, Collini P. et.al. Colorectal carcinoma in children and adolescents: The experience of the Istituto Nazionale Tumori of Milan. *Pediatr Blood Cancer* 2008;50:588-93.
8. Sharma MS, Kumar S, Agarwal N et.al. Childhood colorectal carcinoma a case series. *Afr J Pediatr Surg*;16, (2009): pp 66-67
9. Sultan I, Rodriguez-Galindo C, EL-Taani H, Pastore G, Casanova M, Galino G, Ferrari A et.al. Distinct features of colorectal carcinoma in children and adolescence: A population-based study of 150 cases. *Cancer* 2010; 116(3):758-765. doi:10.1002/cncr.24777.
10. Baig SJ, Hui SK, Basu K, Sanyal S, Bannerjee S, Chatterjee U et.al. Colorectal carcinoma in children: A report of two cases. *J Indian Assoc Pediatr Surg* 2000; 5:26-29.
11. Kumar JK, Rao KVG, Dwarkanath K, Rao KVJ et.al. Colorectal carcinoma in children. *J Indian Assoc Pediatr Surg* 2000;5:30-32.
12. Agarwal P, Malapure SM, Parelkar SV, Das SA, Mathure AB et.al. Carcinoma rectum in a nine year old boy. *J Indian Assoc Pediatr Surg* 2000; 5:33-35.

### \*Corresponding author:

**Dr. Gunjan Bhatia**, 1 Ra 6 Gayatri Nagar, HiranMagri Sector-5, Udaipur 313002 INDIA

**Phone:** +91 9928056404, 91-294-2465439

**Email:** gunjanpath@gmail.com

**Financial or other Competing Interests:** None.