



Adenoid Cystic Carcinoma of Nasal Cavity- A Rare Case Report

Arpita J Nishal, Mubin Patel and Neha S. Shahu*

Department of Pathology, Government Medical College, Surat, Gujarat, India

ABSTRACT

Adenoid cystic carcinoma (ACC) was first described by billroth in 1856. It is common in minor salivary glands around the mouth, uncommon in parotids and in Nose and paranasal sinuses. Sinonasal ACC accounts for 10-25% of all head and neck ACC.

We are reporting a case of nasal cavity adenoid cystic carcinoma in a 70 year old male patient who was presented with bilateral nasal block, nasal bleeding and loss of vision. On examination polypoidal growth was present in bilateral nasal cavity. Biopsy was taken and sent for histopathological examination. Histopathological findings were suggestive of adenoid cystic carcinoma of nasal cavity.

ACC is a slow-growing but highly malignant neoplasm with a remarkable capacity for recurrence. They show no sex predilection and may involve patients of any age, although they usually present in middle-aged or older patients. It has a high risk of recurrence and distant metastasis. Features of diagnostic and therapeutic evaluation are described here with.

Keywords: Adenoid Cystic Carcinoma, Nose, Salivary Gland, Rare Presentation.

Introduction

Adenoid Cystic Carcinoma was first described by billroth in 1856^[1]. It is a malignant neoplasm of salivary ductal and myoepithelial cells^[2]. It is common in minor salivary glands around the mouth, uncommon in parotids and rare in nose and para nasal sinuses. Sinonasal ACC accounts for 10-25% of all head and neck ACC. Adenoid Cystic Carcinoma of Nose and para nasal sinuses most commonly present with mass or epistaxis. It is a slow growing tumor but have a propensity for frequent local recurrence and early perineural/ haematogenous spread. Lung metastasis are usually multiple and prolonged survival with multiple metastasis may occur^[3].

Case Report

A 70 year old male patient presented to our institute with a history of ulcer over right side of nose since 2 years, loss of vision since 8 months, nasal block, nasal bleeding since 6 months and history of fall down before 10 days. Patient was operated for epistaxis 2 years ago. On examination, external nose was swollen with involvement of surrounding structure invading maxillary and bilateral orbital region. On anterior rhinoscopy, ulceroproliferative growth involving the both nasal cavity was seen. It bled on touch and was tender and around 2 x 2 cms ulcer present over right lateral aspect of dorsum of the nose. There was proptosis of eye balls. No abnormalities were detected in throat examination.

Investigations: Complete blood examination findings were normal. MRI findings were well defined lobulated heterogenously altered signal mass lesion measuring approximately 6.7 x 7.8 x 6.2 cm³ in size involving the nasal cavity and bilateral ethmoid sinuses; The lesion destructing / remodelling the nasal bone, nasal septum, ethmoid sinus, medial wall of maxillary sinus and inferomedial aspect of both orbits; Significant opacification and expansion of the nasal cavity and ethmoid sinuses by the mass lesion. The conclusion of MRI findings was neoplastic mass lesion involving nasal cavity and bilateral ethmoid sinuses. Endoscopic Biopsy was taken and sent in formalin filled container for histopathological examination.

Gross examination: Multiple tissue bits labelled as biopsy from bilateral nasal mass received, collectively measuring 6 x 4 x 3 cms in size, firm, greyish white and whole processed in four sections.

On microscopic examination: Tumor cells arranged predominantly in cribriform, solid and tubular pattern. Cribriform pattern characterized by nests of tumor cells interrupted by sharply punched out spaces filled with basophilic matrix. Cells have small angulated hyperchromatic nuclei. Hyperplastic squamous epithelium seen focally. Perineural invasion is not seen. PAS stain highlights the presence of mucinous material. Final diagnosis of Adenoid Cystic Carcinoma was given.



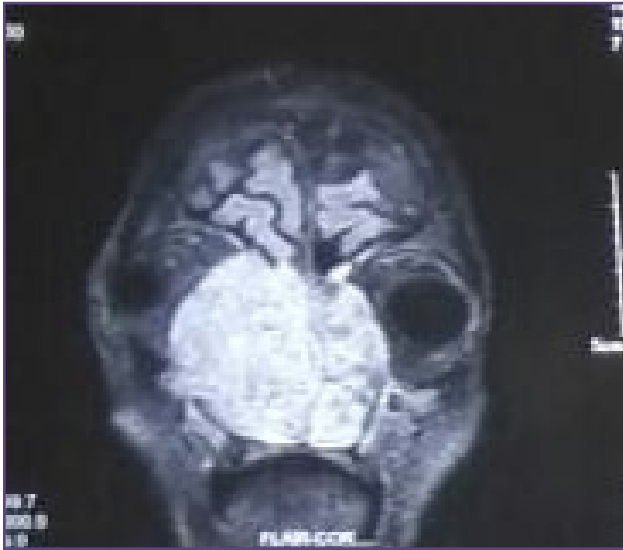


Fig. 1: MRI suggestive of a well defined lobulated mass lesion involving the nasal cavity and bilateral ethmoid sinuses.

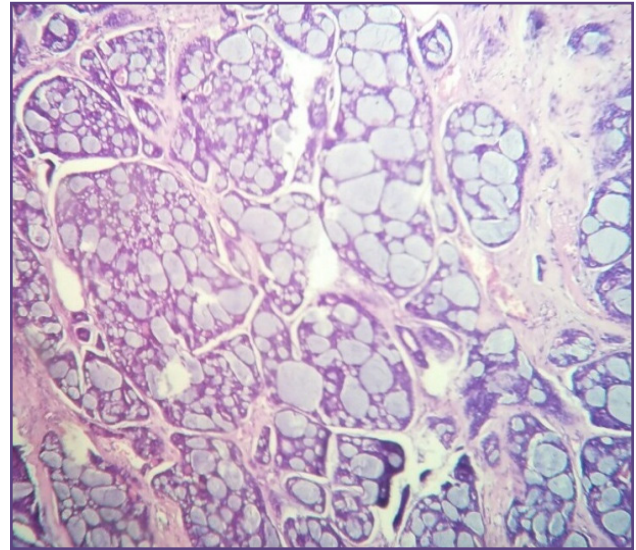


Fig. 2: Tumor cells arranged in cribriform pattern (H & E stain-10X view).

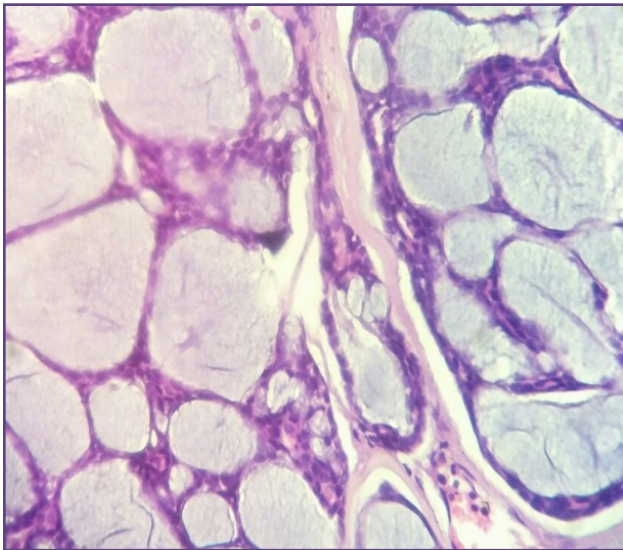


Fig. 3: Tumor cells arranged in cribriform pattern (H & E stain-40X view).

The patient was referred to nearby cancer institute. Radiotherapy was started.

Discussion

Adenoid cystic carcinoma is generally a slow-growing but highly malignant neoplasm with a remarkable capacity for recurrence. In major salivary glands like parotid, it is less common than mucoepidermoid carcinoma and acinic cell carcinoma, but in the minor salivary glands it is the most common malignant tumor^[4]. It accounts for only 0.5 to 4% of all carcinoma of nasopharynx^[5]. It shows

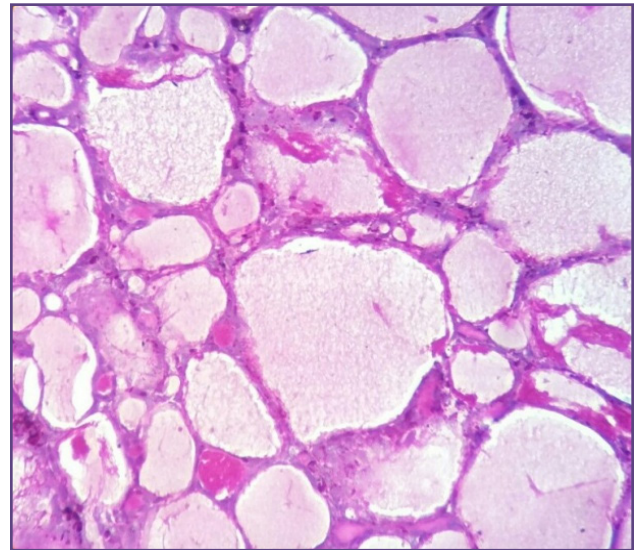


Fig. 4: Special stain highlights the presence mucinous material (Periodic Acid Schiff stain-40X view).

no sex predilection and may involve patients of any age, although they usually present in middle-aged or older patients. It is often painful, probably because of frequent perineural invasion. It has a very high (up to 85%) risk of recurrence. Adenoid cystic carcinoma tends to metastasize hematogenously to distant locations, especially the lung, unlike most other salivary gland malignancies. Lymph node metastases are rare^[6]. Of all the ACC of the head and neck region, those originating in the sinonasal region have the worst prognosis^[7]. The tumor grossly appears solid and

circumscribed, but microscopically, it extends well beyond the grossly visible and palpable limits of the lesion^[8]. Histologically ACCs can manifest a variety of tubular and cribriform structures with variably solid components. The most recognizable architectural form is the cribriform pattern, characterized by nests of tumour cells interrupted by sharply punched-out spaces filled with basophilic matrix. The tubular pattern is composed of bilayered tubules with true lumina. The tumor cells show scant cytoplasm and typically have small angulated and hyperchromatic nuclei. The solid growth pattern is characterized by sheets of tumor cells without lumen formation and may consist of epithelial or myoepithelial elements^[9]. ACC can undergo dedifferentiation to a high grade tumour with necrosis, a high mitotic rate and loss of the distinction between ductal and myoepithelial cells. In such cases immunohistochemical markers like CD43, which are diagnostic for ACC, can be adjuvant^[10]. In our case, cribriform, solid and tubular pattern are evident to diagnose ACC, which excludes the need for immunohistochemistry.

Most common differential diagnosis are basaloid squamous cell carcinoma, polymorphous low-grade adenocarcinoma, pleomorphic adenoma, epithelial-myoepithelial carcinoma, basal cell adenoma or adenocarcinoma .

Histologically adenoid cystic carcinomas show less cytological pleomorphism than basaloid squamous cell carcinoma and fewer mitotic figures and should not contain areas of squamous differentiation or dysplasia of surface epithelium. The presence of nodal metastases virtually excludes the diagnosis of adenoid cystic carcinoma, as this tumor rarely metastasizes to lymph nodes.

Polymorphous low grade adenocarcinomas usually show more heterogeneity in their growth pattern and cytologic features, while adenoid cystic carcinoma tends to have smaller and more angulated nuclei. Adenoid cystic carcinomas have been shown to be much more likely stain with antibodies to c- kit^[6]. EMA also be useful in separating PLGA from ACC. Tumor cells in PLGA are EMA positive, whereas in ACC, EMA stains only those cells lining lumina and not the non-luminal tumor cells^[11].

In case of pleomorphic adenoma, the identification of a mesenchymal component would be indicative of a pleomorphic adenoma, whereas identification of a perineural invasion or infiltration of surrounding tissues would be indicative of adenoid cystic carcinoma^[6].

In case of basal cell adenoma, the characteristic cribriform pattern of adenoid cystic carcinoma is rare. Basal cell adenoma lack cells with irregular, angular shaped nuclei

that are characteristic in adenoid cystic carcinoma. Infiltration and perineural invasion definitely distinguish adenoid cystic carcinoma from basal cell adenoma.

The cells in the adenoid cystic carcinomas are usually smaller with more irregular, angular, hyper-chromatic nuclei and characteristic cribriform pattern is not a feature of epithelial myoepithelial carcinoma^[2].

The rate of recurrence for solid tumors is 100% and for low grade variants is 59-89%. Irrespective of surgery and radiotherapy, the overall recurrence rate of sinonasal ACC is 65%.The distant metastasis is usually seen in lung and bone, which is around 35-50%. The 10 year survival rate is usually less than 20%^[11].

Conclusion

Adenoid cystic carcinoma is a rare tumor of nose and paranasal sinuses. It has a very high risk of distant metastasis and recurrence. Therefore, any patient with features of epistaxis, nasal blockage and cheek swelling needs to be investigated thoroughly by radiological and histological diagnosis. In our case, clinical and MRI findings were suggestive of neoplastic mass and diagnosis of ACC was made histologically. The present case highlights the need to be aware of unusual presentation of ACC in nose and paranasal sinuses.

Reference

1. Purushothaman PK, Ramakrishna R, Sindhu P. Adenoid Cystic Carcinoma of Nasal Cavity: A Rare Presentation Case Report. *International Journal of Scientific and Research Publications*, Feb 2015; Vol5(2):1-3
2. Steven G. Silverberg, Ronald A. De Lellis, William J. Frable, Virginia A. Livolsi, Mark R. Wick. *Silverberg's Principles and practice of Surgical pathology and Cytopathology*, 4th edition, Volume 1. Churchill Livingstone: Elsevier; 2006:1221-1246.
3. Kumar VP, Rao PN, Kumar AG. Adenoid Cystic Carcinoma of Nasal Cavity- A case report. *Indian journal of Otolaryngology and Head and Neck Surgery*, January-March 2003; Vol. 55:43-45.
4. Goldblum JR, Laura W. Lamps, Jesse K. McKenny. *Rosai and Ackerman's, textbook of surgical pathology*. 11th edition, Elsevier;2018:252-253.
5. Phan J, No S, Pollard Iii C, et al. A Rare Case of Unresectable Adenoid Cystic Carcinoma of the nasopharynx Treated with Intensity Modulated Proton Therapy. 2017;*Cirrus* 9(9):e1688. doi:10.7759/cureus.1688.
6. Edward B. Stelow and Stacy E. Mills: *Biopsy Interpretation of Upper Aerodigestive Tract and Ear*. Philadelphia: Lippincott Williams & Wilkins, a Wolters Kluwer,2nd edition;2012:104-119.

7. Jagmohan P, Sangwan S, Sethi S K, Solanki R S. Sinonasal adenoid cystic carcinoma. *Indian J Radiol Imaging*, 2005;15:403.
8. Stacey E Mills MD: Sternberg's Diagnostic Surgical Pathology, Sixth Edition;2015:2565-2566
9. El-Naggar A.K., Chan J.K.C., Grandis J.R., Takata T., Sliotweg P.J. (Eds): WHO Classification of Head and Neck Tumours (4th edition). IARC: Lyon 2017:164
10. Pournima Hodge, Subhadra Sharma, Monika Yadav: Adenoid cystic carcinoma of the parotid gland. *Contemporary Clinical Dentistry*, Apr-Jun 2012; 3(2):223-226.
11. David, J. Dabs: Diagnostic immunohistochemistry, 3rd edition. Churchill Livingstone: Elsevier; 2010:275-276

***Corresponding author:**

Dr. Neha S. Shahu, Mailing address: 289, Shreeji Nagari, Ugat, Bhesan road, Surat 395005. INDIA

Phone: +91 9106421627

Email: shahu581993@gmail.com

Financial or other Competing Interests: None.