

A Rare Presentation of Ewing Sarcoma as Supraclavicular Swelling in an Adolescent Male – A Case Report

Arun Gopal*, Shivali Awasthi, Vikas Dagar and Prateek Kinra

Department of Pathology, Armed Forces Medical College, Pune

ABSTRACT

Supraclavicular swellings can have numerous differential diagnosis ranging from infections to malignancy, in almost all age groups. Here we present a case of 15 year old boy who presented with left supraclavicular swelling and clinically diagnosed as a case of Tuberculosis, underwent FNAC which was suggestive of Small Round Blue Cell Tumor favouring Ewing sarcoma. Later, trucut biopsy of the swelling confirmed the diagnosis of Ewing sarcoma. Ewing sarcoma is one of the most common primary malignancy of bone in children but can also arise from extraskeletal region like soft tissue.

Keywords: *Supraclavicular Swelling, Small Round Blue Cell Tumor, Ewing Sarcoma.*

Introduction

Neck swelling is a common presentation in Surgical and ENT OPD. These neck swellings can be enlarged lymph nodes (LN) or soft tissue swellings. Supraclavicular swellings are commonly caused by infectious diseases, reactive degeneration in lymph nodes, branchial cleft cysts, or benign and malignant tumors.^[1] Out of all the regions of cervical area, Supraclavicular LNs have the highest risk of malignancy.^[2] Left supraclavicular LN, also called as Virchow's node, can be palpable in various conditions ranging from infections to malignancies. They can be enlarged due to malignant lesions of gastrointestinal tract and genitourinary tract as these organs are drained by left supraclavicular LN. Apart from these malignancies, breast carcinoma, Hodgkin's disease and non-Hodgkin's lymphoma can also cause Supraclavicular swellings.

Clinically, sometimes, supraclavicular swelling may look deceptive and clinician might confuse it with cold abscess or reactive node especially when the suspicion of malignancy is less in young patients. Here we present an interesting case where a 15-year-old boy presented with unilateral (left) supraclavicular swelling with no other symptoms which was suspected to be tuberculosis clinically but later turned out to be malignant lesion with metastasis.

Case Report

A 15-year-old boy with no known comorbidities, presented to surgery OPD with history of left supraclavicular swelling for last three months. There was no associated bony pain, generalized weakness, cough, fever, weight loss or swelling elsewhere in body. He was clinically diagnosed as a case of Tuberculosis and was referred to Pathology

department for Fine Needle Aspiration Cytology (FNAC). We palpated a 3x3 cm sized firm, non-tender swelling in left supraclavicular region with no skin changes in form of erythema, raised temperature or draining sinus. FNA from the swelling yielded blood mixed material.

The slides were air dried and wet fixed in ethanol followed by May-Grunwald-Giemsa, Papanicolaou and Ziehl-Neelsen stains. Microscopy revealed cellular smears showing atypical small to intermediate cells with scant cytoplasm, high nucleocytoplasmic ratio, nuclei with powdery chromatin and occasional prominent nucleoli (Figure 1a,1b). No granuloma or giant cells seen. No Acid-fast bacilli were seen on Ziehl-Neelsen stain. Considering the age profile and cellular morphology, small round cell tumor was a likely differential diagnosis but possibility of metastasis from other sites needed to be ruled out. The aspirated material was also processed for cell block.

Meanwhile, imaging done showed a solitary, predominantly solid mass measuring 2.6x3.3x3.6 cm with heterogenous echotexture and internal vascularity and without foci of calcification in left supraclavicular region. Few reactive lymph nodes (Level I and II) were also noted. Ultrasonography of abdomen to look for primary site revealed normal scan.

The cell block showed features of small round blue cell tumor and immunohistochemistry (IHC) was performed. The initial IHC was negative for Thyroglobulin, TTF-1, CK7 and CK20, thereby ruling out metastases from thyroid, lung, GIT and genitourinary tract. Synaptophysin was negative excluding the possibility of neuroendocrine tumor. WT-1 was also negative ruling out renal or

mesothelial malignancy. However, IHC was positive for Vimentin favoring mesenchymal origin of tumor. The further IHCs were negative for S100 and Myo-D1 ruling out nerve sheath and myogenic tumors, respectively. IHC was positive for CD99 and FLI1 (Figure 1c,d). Hence, the diagnosis of Small Round Blue Cell Tumor favoring Ewing Sarcoma (ES) was provided.

Later on, CECT of neck and chest was done which showed a well – defined, oval, solid lesion, measuring 3.7x4.2x4.2 cm in left supraclavicular region with heterogenous post contrast enhancement and non – enhancing areas within (Figure 2a,2b). The lesion was in close proximity of middle third of left clavicle with no evidence of cortical invasion, periosteal thickening or periosteal reaction. Multiple small nodules suggestive of metastases were seen in lateral basal segment of left lower lobe of lung. These CECT findings were suggestive of solid enhancing lesion in left

supraclavicular region with evidence of lung metastases.

The diagnosis was confirmed by a trucut biopsy sent to the histopathology section in our department. On histopathological examination, sections revealed a tumor comprising of sheets of small to intermediate cells showing moderate pleomorphism with individual cells showing high nucleocytoplasmic ratio, scant eosinophilic cytoplasm, large nuclei with speckled chromatin and occasional eosinophilic nucleoli. Background stroma was desmoplastic. Mitoses and areas of necrosis were noted. No lymph nodal architecture was seen (Figure 3a,3b). IHC was positive for CD99 and FLI1 (Figure 3c,3d) and negative for LCA and Desmin. Thus, confirming the diagnosis of ES, as provided on FNAC.

Later, the patient was referred to Oncology center with diagnosis of ES with lung metastases for further evaluation and management.

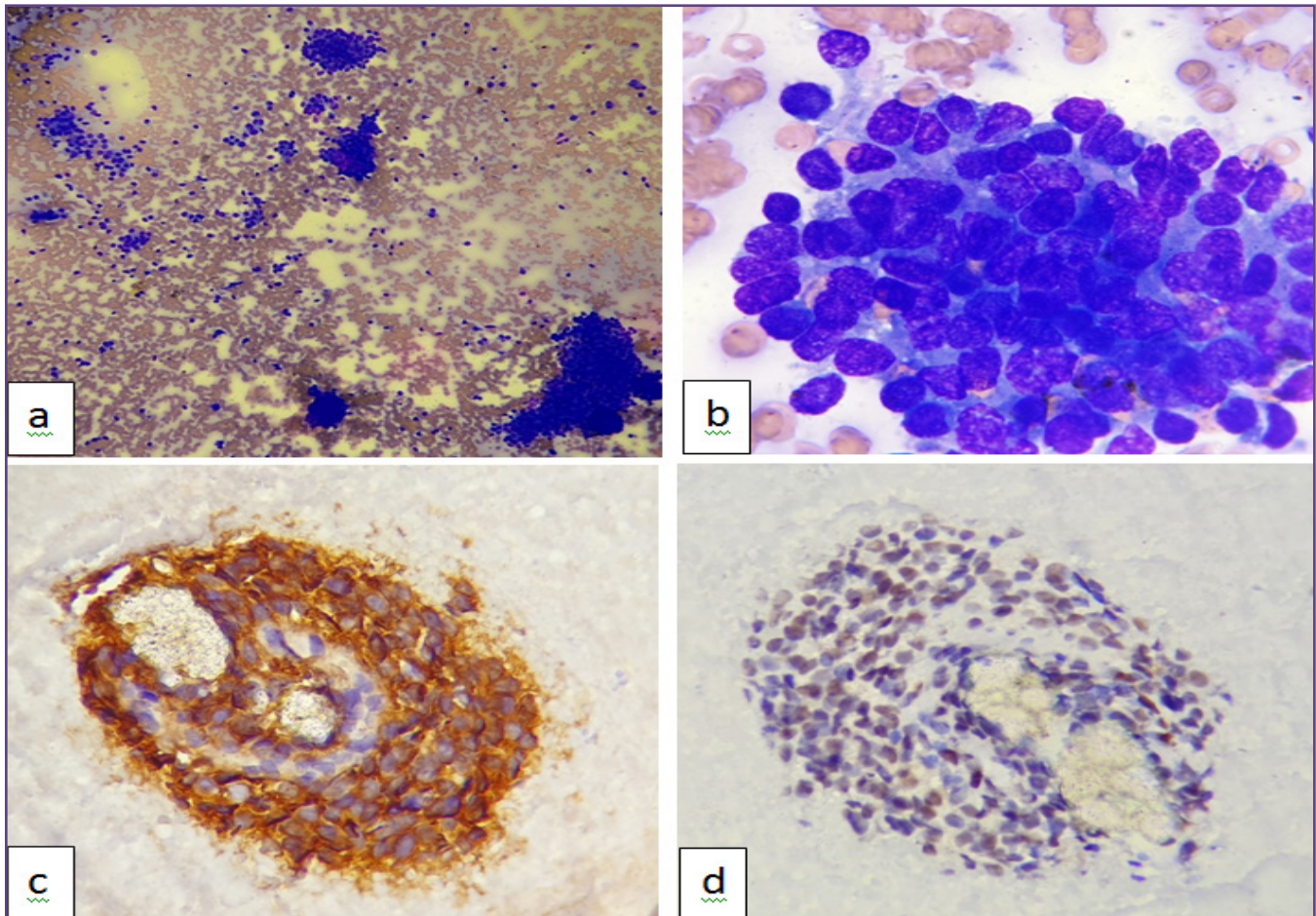


Fig. 1 :- (a) Aspirate smears show atypical cells arranged in clusters as well as singly scattered (MGG; 100X). (b) The individual cells are small to intermediate in size showing scant to moderate amount of cytoplasm, high nucleocytoplasmic ratio, nuclei with powdery chromatin and prominent nucleoli (MGG; 1000X). The atypical cells on cell block show (c) membranous positivity for CD99 (400X) and (d) nuclear positivity for FLI1 (400X)..

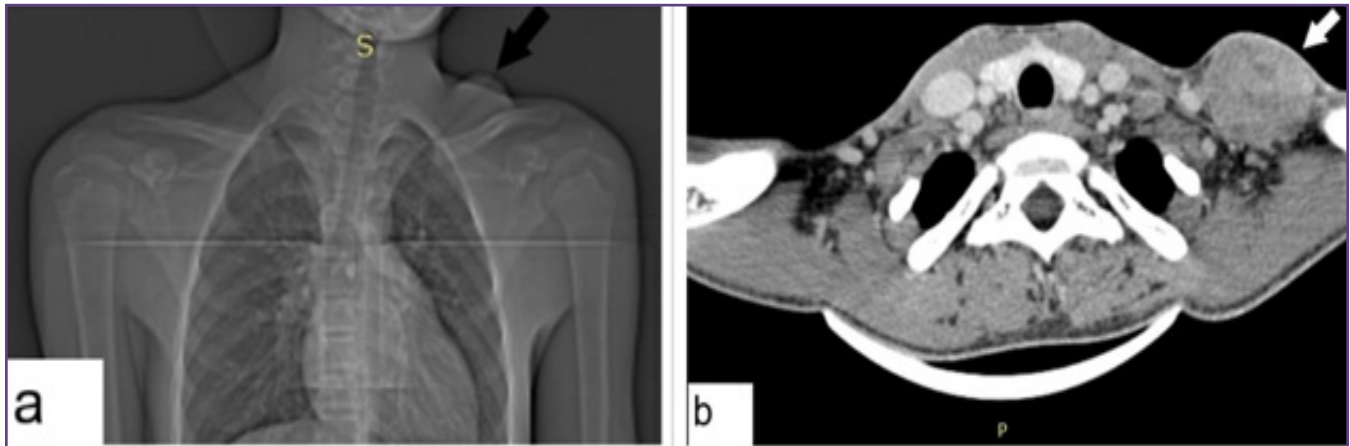


Fig. 2 :- (a) CT scan topogram shows a left supraclavicular swelling (Black arrow). (b) CECT neck shows a well - defined, oval, solid lesion, measuring 3.7x4.2x4.2 cm in left supraclavicular region (white arrow) with heterogenous post contrast enhancement and non - enhancing areas within.

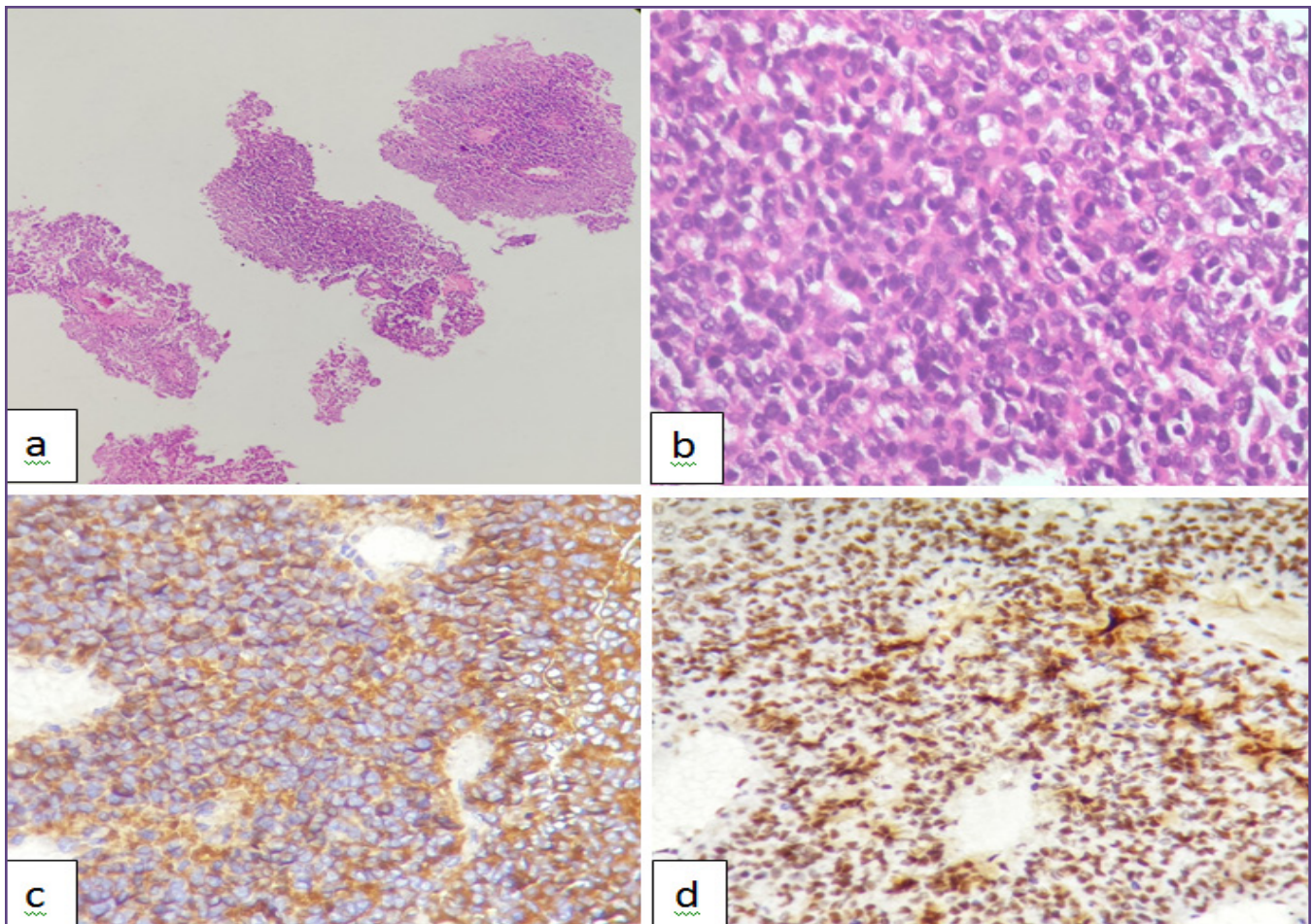


Fig. 3:- (a) The sections from biopsy show a tumor comprising of sheets of small to intermediate cells along with desmoplastic stroma (H&E; 100X). (b) These tumor cells show high nucleocytoplasmic ratio, minimal eosinophilic cytoplasm, large nuclei with speckled chromatin and anisonucleosis. Nucleoli are present and scattered mitoses are noted (H&E; 400X). The tumor cells show (c) membranous positivity for CD99 (400X) and (d) nuclear positivity for FLI1 (400X).

Discussion

Diagnosis of supraclavicular masses can be really deceptive especially when suspicion of malignancy is less and the differentials may range from infections to metastatic deposits to rarely, primary malignancy. Age of onset, location, duration, associated systemic symptoms and adequate clinical examination hints towards the probable diagnosis. Apart from hematological investigations, chest X-ray, Mantoux test, sputum examination and sonography, FNAC has also become a first line investigation in such cases due to its minimal invasiveness. FNAC can also differentiate between benign, malignant and infective pathologies. However, FNAC can be inadequate due to small amount of tissue sampled and it does not allow interpretation of nodal architecture. Therefore, whenever malignancy is suspected, tissue biopsy is recommended.^[3]

In cases of malignant supraclavicular swellings, metastatic deposits from other organs should be ruled out as per the cytological features and IHC evaluation. Sometimes, an undifferentiated small round blue cell tumor (SRBCT) may be encountered. In children, the differential diagnoses of SRBCT are rhabdomyosarcoma, Ewing sarcoma (ES), mesenchymal chondrosarcoma, small cell osteosarcoma, hemangiopericytoma and neuroblastoma.^[4]

ES was first described by James Ewing in 1921. ES is a small, round cell tumor which shows pathognomonic molecular findings and varying degrees of neural differentiation.^[5] Though ES is an uncommon malignancy, it is one of the most common primary malignancy of bone in children. Usually, ES arises from diaphysis of bone and is mostly associated with soft tissue extension of the tumor.^[6] In 1969, a case series of five patients with a round cell tumor arising from paravertebral soft tissues was described.^[7] Since then, Extraskelatal Ewing sarcoma (EES) has been identified as a distinct entity. EES affects both the genders equally.^[6] Most commonly, EES arises in chest wall, lower extremities and paravertebral region. Less commonly, it may arise in the pelvis and hip region, retroperitoneum and upper extremities.^[8] EES predominantly affects young adults and adolescents of age group of 10 to 30 years. It is aggressive in nature and shows higher rate of recurrence. Distant metastases are also seen commonly in such cases.^[9]

Microscopically, ES shows small cells with round to oval, uniform nuclei and vesicular or finely stippled chromatin. It can be differentiated from rhabdomyosarcoma (RMS) as ES lacks any significant eosinophilic cytoplasm and evidence of spindling which are seen in RMS. CD99 shows strong membranous positivity in almost all cases of ES but it is not specific. Sometimes, Synaptophysin and neuron-specific enolase may also show positivity in ES, but these

markers are non -specific. An antibody to FLI-1 may also help in diagnosis of ES.^[10]

ES is the first sarcoma where recurrent chromosomal translocation were found, the most common being t(11;22)(q24;q12), which results in EWSR1–FLI1 fusion gene formation. This rearrangement has been found in more than 90% of cases. Many other partner genes have also been found which, less commonly, fuse to EWSR1. These include ERG, FEV, 1E1AF, ETV1.^[11] On the other hand, Desmoplastic Small Round Cell Tumor (DSRCT) shows t(11;22)(p13;q12) commonly. Similarly different genetic abnormalities are seen in different SRBCTs which can be detected by molecular studies.

In our case, the cytological features were indicative of malignancy, either metastatic deposits or de novo in origin. Later, cell block confirmed it to be a small round blue cell tumor with IHC ruling out common metastatic deposits. Considering the age profile, IHCs for the differential diagnoses of SRBCT were ordered which indicated ES. Furthermore, the imaging of neck, chest and abdomen found only metastatic deposits in lung. Later, the biopsy of the supraclavicular lesion also confirmed the diagnosis. Additionally, molecular studies, which could not be performed in our case, are helpful in confirming the genetic abnormality and differentiating various differentials in such cases.

Conclusion

This case reaffirms the utility of FNAC as a first line of investigation in such cases. A timely done FNAC can help in detection of hidden malignancy in rather asymptomatic patients. Apart from cytological features, IHC panel is also a useful tool in confirming the diagnoses. It should also be highlighted that rarely, ES can present as only supraclavicular swelling and it should be considered in the differential diagnosis of round cell tumors of soft tissues.

Acknowledgements

Nil.

Funding

Nil.

Competing Interests

Nil.

Reference

1. Moesgaard L, Baerentzen S, Mirz F. Cervical thoracic duct cyst : a differential diagnosis of left supraclavicular swelling. *Eur Arch Otorhinolaryngol.* 264:797–9, 2007
2. Mohseni S. Peripheral Lymphadenopathy : Approach and Diagnostic Tools. 2014;39(2).

3. Stutchfield CJ, Tyrrell J. Evaluation of lymphadenopathy in children. *Paediatr Child Health*. 22:98–102, 2012
4. Triche TJ, Knutsen T, Miser J, Tsai S, Israel MA. Cytogenetic Characterization of Selected Small Round Cell Tumors of Childhood. *Cancer Genetics and Cytogenetics*. 208:185–208, 1986
5. Bosma SE, Ayu O, Fiocco M, Gelderblom H, Dijkstra PDS. Prognostic factors for survival in Ewing sarcoma : A systematic review. *Surg Oncol*. 27(4):603–10, 2018
6. Ahmad R, Mayol BR, Davis M, Rougraff BT. Extraskeletal Ewing Sarcoma. *Cancer*. 85(3):725-31, 1999
7. Tefft M, Vawter GF, Mitus A. Paravertebral “round cell” tumors in children. *Radiology*. 92(7):1501-9, 1969
8. Cheung CC, Kandel RA, Bell RS, Mathews RE, Ghazarian MD. Extraskeletal Ewing sarcoma in a 77-year-old woman. *Arc Pathol Lab Med*. 2001; 125:1358-60
9. John RG, Andrew LF , Sharon WW. *Enzinger and Weiss’s soft tissue tumors*. Philadelphia: Elsevier; 2014: 1028-1044
10. Brooks JSJ. *Sternberg’s Diagnostic Surgical Pathology*. Philadelphia: Wolters Kluwer Health; 2010: 184-185
11. Inwards CY, Oliveira AM. *Diagnostic Histopathology of Tumors*. Philadelphia: Elsevier Saunders; 2013: 1878.

***Corresponding author:**

Dr Arun Gopal, Junior Resident, Department of Pathology, Armed Forces Medical College, Pune.

Phone: +91 9412248276, 9149188799

Email: arungopal239@gmail.com

Financial or other Competing Interests: None.

Date of Submission : 13/07/2020

Date of Acceptance : 15/10/2020

Date of Publication : 30/11/2020