

Case Report of An Unusual Mediastinal Mass - Thymolipoma

Sreeja Raju¹, Divya S¹, M. C. Savithri¹, Ajaykumar K K² and Gayathri. G. Nair^{1*}

¹Department of Pathology, Amala Institute of Medical Sciences, Thrissur, Kerala

²Department Of Cardiothoracic and Vascular Surgery, Amala Institute Of Medical Sciences, Thrissur, Kerala

ABSTRACT

Thymolipomas are rare, slow-growing, benign anterior mediastinal neoplasms which are very often detected incidentally. Here we present a case of a 47 year old female who presented with chest discomfort and radiology revealed an anterior mediastinal mass. Total thymectomy was done and histopathology showed features consistent with thymolipoma. Very few cases of thymolipomas have been reported in Indian and world literature.

Keywords: *Thymus, Mediastinal Mass, Thymolipoma, Thymectomy*

Introduction

Thymus is principally a lymphoid organ located in the anterior and superior mediastinum. Most commonly observed thymic tumors are thymomas. Thymolipomas are rare, slow-growing, benign anterior mediastinal neoplasms composed of an admixture of mature adipocytes and non-neoplastic thymic tissue. [1] Any age group can be affected [2] and accounts for 2-9% of all thymic neoplasms.[3] It is mostly an incidental finding that is diagnosed during a workup for other medical problems. This case report is presented since it is a rarely encountered lesion. This is the very first case of thymolipoma reported in our institute. Very few cases of thymolipomas have been reported in Indian and world literature.

Case Report

A 47 year old female was referred to our hospital with complaints of cough and chest discomfort of one week duration. It was associated with vague pain at the upper back for over 6 months duration. She gives history of on and off drooping of eyelids for a period of one year. She was on homeopathic treatment for psoriasis.

Her general and physical examination was within normal limits. Ptosis was not evident at the time of examination. All systems were within normal limits. Power grade was 5/5.

The results of hemogram, biochemistry tests, and urinalysis were within normal limits. The work up for myasthenia gravis was done but was normal (neostigmine test and anti-AChR antibody titre).

Chest X-ray (Fig.1) revealed a homogenous opacity at the right cardiophrenic recess. Patient was posted for

bronchoscopy but no intraluminal pathology was identified. CT thorax revealed a well-defined heterogeneously enhancing soft tissue density lesion in the anterosuperior mediastinum measuring 5 x 3 cm with fat contents and closely abutting right side of heart maintaining the fat planes. A radiological diagnosis of thymolipoma was given.

Total thymectomy was done. Per operatively a well encapsulated conical mass measuring 6 x 4 cm involving the right inferior horn of thymus was noted.

Gross examination showed a well encapsulated nodular soft tissue mass measuring 8 x 7.5 x 2.3 cm. Outer surface was vaguely nodular. Cut section showed soft to firm, grey white to yellowish areas (Fig.2).

Microscopy showed an encapsulated neoplasm with scattered thymic tissue interspersed with varying proportions of mature adipocytes and areas of fibrosis. Hassall's corpuscles noted. No areas of necrosis or nuclear atypia or mitotic activity seen (Fig.3). With these features a histopathological diagnosis of thymolipoma was reported.

Discussion

Thymus is a principle lymphoid organ situated in the anterior and superior mediastinum.[4,5] Most common tumours of the thymus are thymomas, but other types such as lymphomas, thymolipomas, germ cell tumours, cysts and neuroendocrine carcinomas are also reported rarely.

The thymolipomas can occur at any age with no sex predilection. It is mostly an incidental finding, but can also present with local symptoms like cough, dyspnea, chest pain, hoarseness and cyanosis or paraneoplastic syndromes.

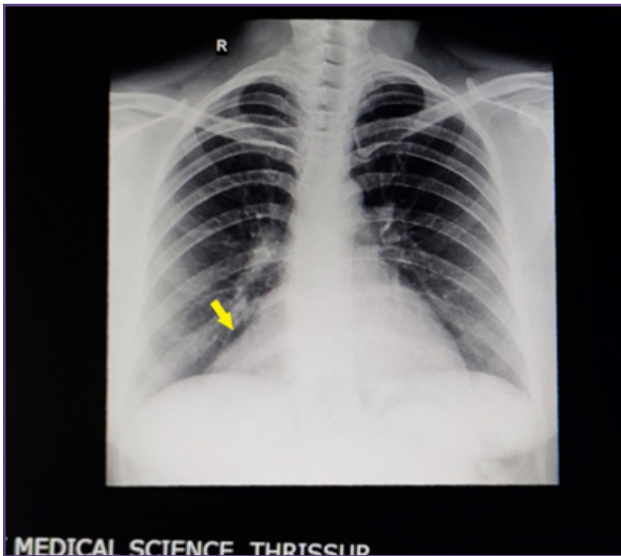


Fig. 1: Chest X-ray revealed a homogenous opacity (yellow arrow) at the right cardiophrenic recess.

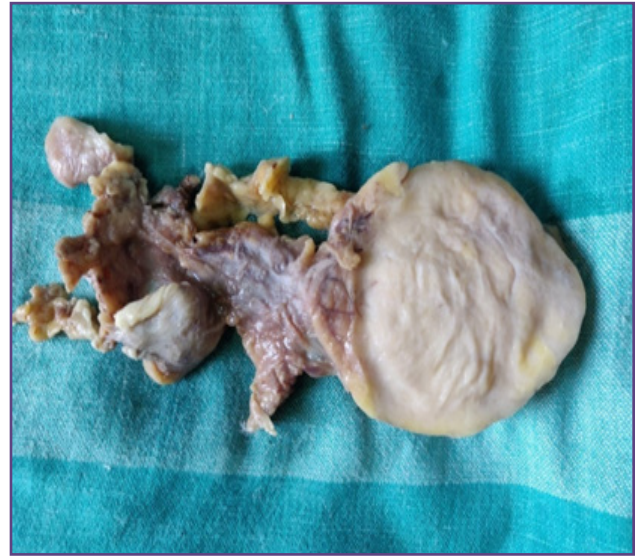

Fig. 2: Gross showed a well encapsulated nodular soft tissue mass measuring 8x7.5x 2.3 cm. Cut section showed soft to firm grey white to yellowish areas.

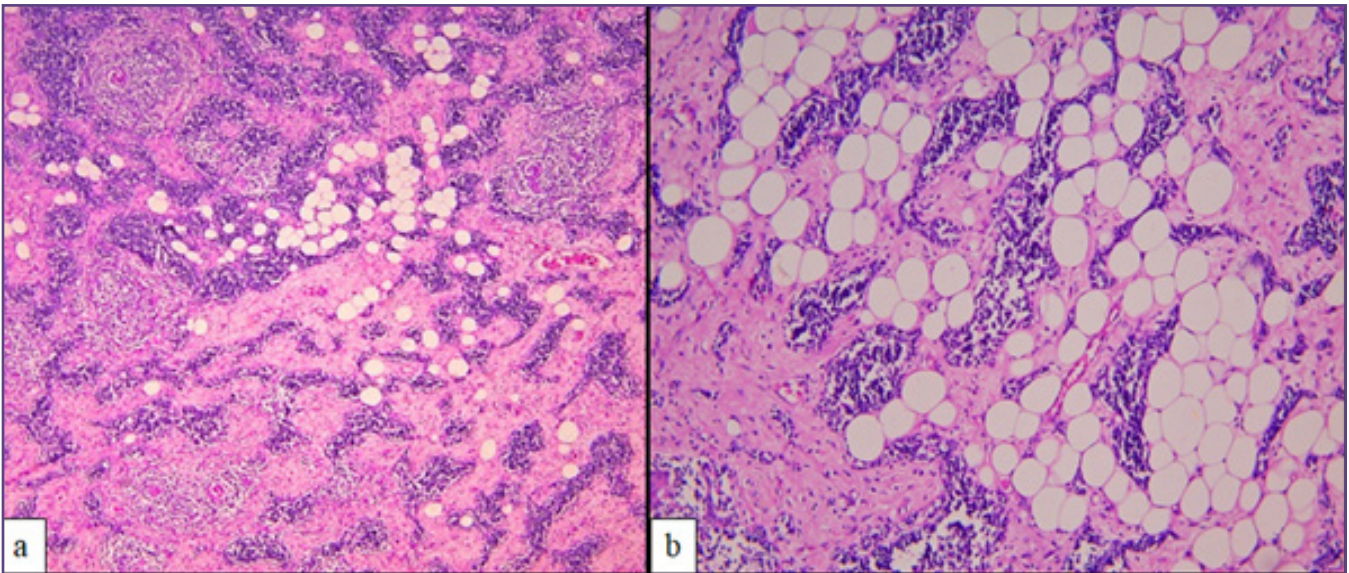


Fig. 3: a - Scattered thymic tissue interspersed with varying proportions of mature adipocytes and areas of fibrosis (H&E 100X); b - Thymic tissue and adipocytes (H& E 400X).

^[6] Myasthenia gravis is the most commonly associated condition. In rare cases, aplastic anemia, erythrocytic hypoplasia, and hypogammaglobulinemia may develop. ^[7-9] Chest X-ray may resemble cardiomegaly while CT and MRI are usually diagnostic as it shows predominant areas of mature fat with interspersed islands of soft tissue.

It is still a matter of speculation whether thymolipomas are benign tumors of specialized thymic stroma (fat) arising in relationship to the thymic epithelium or a fatty regression

of a hyperplastic thymus or thymoma. ^[4,5] The first case was documented by Lange in 1916 and was described as a lipoma of the thymus. ^[10] The term thymolipoma was first coined by Hall in 1948. ^[4]

Grossly they are slow growing, well encapsulated tumors and may become huge masses. ^[7,9] Microscopically they consist of mature adipose tissue with strands or even large areas of thymic tissue that is mostly atrophic, but may contain lymphoid follicles or Hassall's corpuscles.

Atypia and mitotic activity are not seen. ^[3] Very rarely thymolipomas may contain carcinoid tumors and thymomas. ^[1] Differential diagnosis includes thymic hyperplasia, lipoma and liposarcoma of the mediastinum. ^[2] Lipoma will lack thymic epithelial tissue and liposarcoma will show higher degree of atypia and lipoblasts. In thymic hyperplasia, adipose tissue is usually not seen.

In one case translocation involving the HMGA2 gene on chromosome 12q15 was found. ^[11] Studies are going on regarding the therapeutic and prognostic implications of this cytogenetic aberration. No genetic studies were performed for this case.

Complete resection is curable. ^[6] No metastases, recurrences or tumour related deaths have been reported.

Conclusion

Thymolipomas are very rare, slow growing anterior mediastinal neoplasms which are detected incidentally. Very few cases of thymolipomas have been reported in world literature and here we report a case of thymolipoma from our institute.

Acknowledgements

NIL

Funding

None

Competing Interests

None Declared

References

1. Bayramoğlu Z, Ömeroğlu E, Ünlü Y. Thymolipoma with massive pleural effusion: A case report. *J Surg Med.* 2019;3(3):276–7.
2. Vaziri M, Rad K. Progressive Dyspnea in a 40-Year-Old Man Caused by Giant Mediastinal Thymolipoma. *Case Rep Surg.* 2016;2016:1–3.
3. Reddy RHV, Qureshi NJ. Unusual Mediastinal Tumour of Thymic Origin. *Indian J Surg Oncol.* 2013;4(3):320–1.
4. Hall GFM. A case of thymolipoma. With observations on a possible relationship to intrathoracic lipomata. *Br J Surg.* 1949;36(143):321–4.
5. Carapinha CP, Wainwright L, Loveland JA. A giant thymolipoma. *SAJCH South African J Child Heal.* 2010;4(1):20–1.
6. Obeso Carillo GA, García Fontán EM, Cañizares Carretero MÁ. Timolipoma gigante: presentación de un caso de tumor mediastínico inusual. *Arch Bronconeumol.* 2014;50(12):557–9.
7. Rosado-de-Christenson ML, Pugatch RD, Moran CA, Galobardes J. Thymolipoma: Analysis of 27 cases. *Radiology.* 1994;193(1):121–6.
8. Hayashi A, Takamori S, Tayama K, Mitsuoka M, Ohtsuka S, Aoyama Y, et al. Thymolipoma : Clinical and Pathological Features - Report of Three Cases and Review of Literature. *Kurume Med J.* 1997;44:141–6.
9. Ramos Filho J, Melo RF, De Macedo M, Fiorelli LA, Costa A, Isolatto RB. Chest pain due to right atrial compression caused by a thymolipoma. *Arq Bras Cardiol.* 2004;82(5):484–6.
10. Almog C, Weissberg D, Herczeg E, Pajewski M. Thymolipoma simulating cardiomegaly: a clinicopathological rarity. *Thorax.* 1977;32(1):116–20.
11. Hudacko R, Aviv H, Langenfeld J, Fyfe B. Thymolipoma: clues to pathogenesis revealed by cytogenetics. *Ann Diagn Pathol.* 2009;13(3):185–8.

*Corresponding author:

Dr. Gayathri. G. Nair, Department of Pathology, Amala Institute Of Medical Sciences, Thrissur, Kerala - 680555

Phone: +91 9496333244

Email: dr.gayathri.g.nair@gmail.com

Financial or other Competing Interests: None.

Date of Submission : 24/08/2020

Date of Acceptance : 02/10/2020

Date of Publication : 30/11/2020