

Nasal Leiomyoma: Prevalent Tumor at A Peculiar Location

Md Ali Osama¹, Priti Chatterjee^{1*}, Alice Xalxo¹ and Gautam Bir Singh²

¹Department of Pathology, Lady Hardinge Medical College, New Delhi

²Department of Otolaryngology, Lady Hardinge Medical College, New Delhi

Case History

A 42-year-old male with no significant medical history presented to the department of otolaryngology with complaints of a mass in the left nasal cavity. The patient initially noticed a pea-sized mass 2.5 years back, which gradually progressed in size. The patient did not give any history of bleeding from the nose, nasal discharge, obstruction, pain or deformity of face. On examination, a solitary polypoidal soft tissue mass measuring 2.5x1.5x1.2 cm, was seen filling the left nasal cavity which did not bleed on touch, was non-tender and non-reducible. The mass was attached to the nasal septum and the probe couldn't be passed medial to it. Non-contrast CT revealed a well-defined round homogeneously enhancing soft tissue lesion in the left nasal vestibule arising from nasal septum (Fig 1a and b). Surgical excision of the mass was done and sent for histopathological examination. Microscopically, a well circumscribed tumor was seen just under the respiratory mucosal lining (Fig 2a). Focal squamous metaplasia of the mucosa was observed. The tumor was composed of interlacing fascicles of spindle cells with ovoid blunt ended (cigar shaped) nuclei and pale pink cytoplasm (Fig 2b). There was no cellular atypia or mitosis seen. Numerous thick and thin-walled vessels were noted. Immunohistochemically, the spindle cells showed strong positivity for Vimentin, SMA (Fig 3a) and Desmin (Fig 3b)

whereas S-100 was negative. The patient is doing well in a month follow-up and has showed no signs of recurrence.

Discussion

Leiomyomas are benign mesenchymal neoplasm derived from smooth muscle. They are common in uterus, cervix, ovary, gastrointestinal tract and skin but uncommon in respiratory tract; rarely found in the nose and paranasal sinuses where they constitute only 1% of all the benign lesions. [1] On extensive literature search, very few cases of nasal leiomyomas have been reported till date. [2-4] Enzinger and Weiss in their study of 7748 cases of Leiomyomas, found majority (95%) of them in female genital tract, skin (3%), GIT (1.5%) and the remaining in rare sites like nasal cavity and PNS (0.5%). [5] The rarity of its occurrence in respiratory tract is supposed to the fact that smooth muscle is only present in the wall of blood vessels and sparsely present in the nose. The possible differential diagnosis of mesenchymal tumors occurring in nasal cavity is neurofibroma, schwannoma, angiofibroma, hemangioma and leiomyosarcoma. Immunohistochemical markers like smooth muscle actin (SMA), Desmin, S-100, Vimentin and CD34 can be used to differentiate these tumors. Tumor size, histopathological features like mitotic activity, cellular atypia, infiltrating margins and

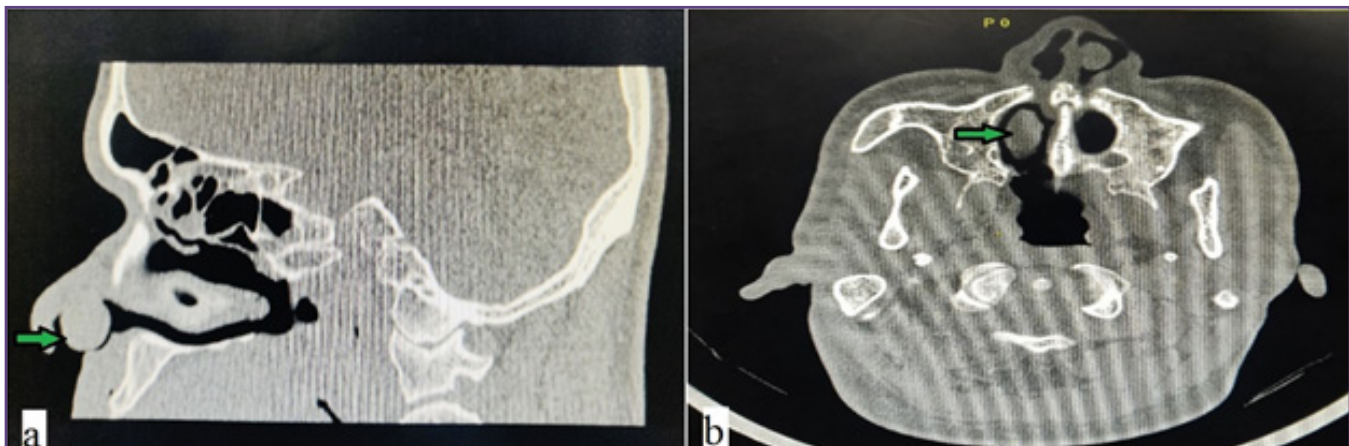

Fig. 1: (a) Sagittal NCCT image shows a mass (green arrow) in the left nasal cavity; (b) Axial NCCT image shows a homogeneous mass (green arrow) in the left nasal vestibule arising from nasal septum.

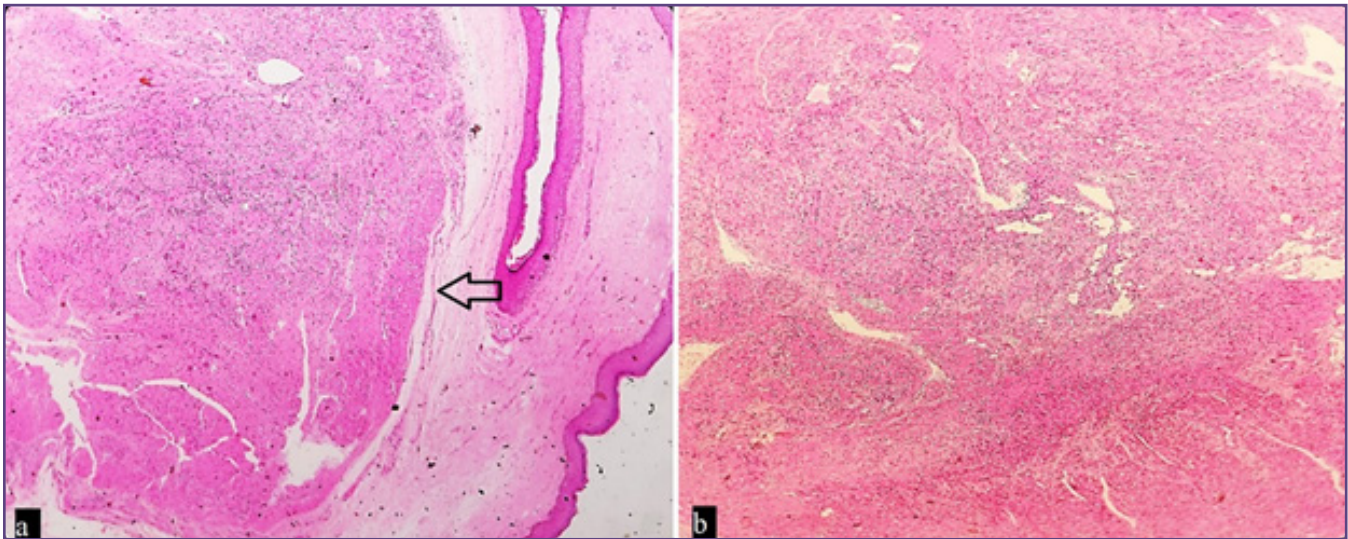


Fig. 2: (a) A well circumscribed tumor (arrow) seen just under the respiratory mucosal lining undergoing squamous metaplasia (H and E 40x); (b) Tumor composed of interlacing fascicles of spindle cells with thick and thin-walled blood vessels (H and E 100x).

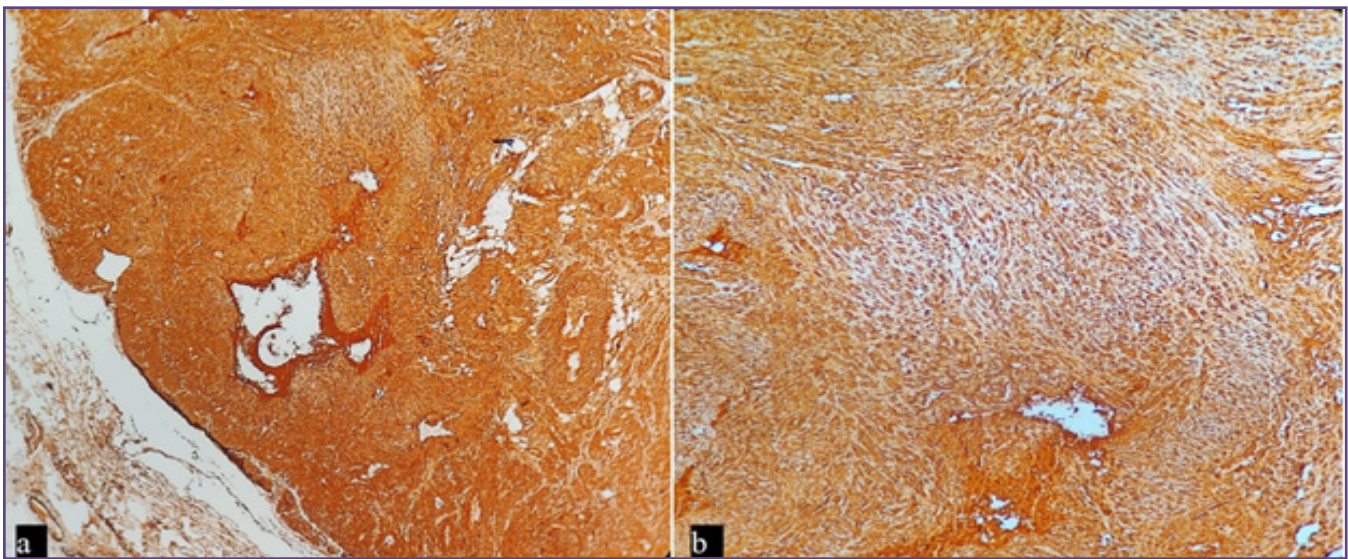


Fig. 3: (a) IHC staining- SMA positive (40x); (b) IHC staining- Desmin positive (100x).

immunohistochemical results help in the correct diagnosis and determining their malignant potential. Vincenzi et al diagnosed a case of atypical leiomyoma where the cells showed pleomorphism, pyknosis, nuclear multilobation and intranuclear invaginations. [6] Local resection (endoscopic surgery or by lateral rhinotomy) is the only treatment for these tumors and so far, no reports of recurrence after excision have been reported yet. [2]

Conclusion

Leiomyoma of nasal cavity is a rare tumor location. Careful observation of the morphological features will enable to

differentiate it from other mesenchymal neoplasms for a correct surgical approach.

Funding

None

Competing Interests

None

References

1. Veeresh M, Sudhakara M, Girish G, Naik C. Leiomyoma: A rare tumor in the head and neck and oral cavity: Report of 3 cases with review. *J Oral Maxillofac Pathol.* 2013; 17:281-7.

2. Purohit GN, Agarwal N, Agarwal R. Leiomyoma arising from septum of nose. *Indian J Otolaryngol Head Neck Surg.* 2011; 63:64-7.
3. Agarwal AK, Bansal R, Singhal D. Sinonasal leiomyoma: report of 2 cases. *Ear Nose Throat J.* 2005; 84:224-30.
4. Singh R, Hazarika P, Balakrishnan R, Gangwar N, Pujary P. Leiomyoma of the nasal septum. *Indian J Cancer.* 2008; 45:173-5.
5. Enzinger F, Weiss S. *Soft tissue tumors.* 2. St. Louis: Mosby; 1988. pp. 383–401.
6. Vincenzi A, Rossi G, Monzani D, Longo L, Rivasi F. Atypical (bizarre) leiomyoma of the nasal cavity with prominent myxoid change. *J Clin Pathol.* 2002; 55:872-5.

***Corresponding author:**

Dr Priti Chatterjee, MD, Associate Professor, Department of Pathology, Lady Hardinge Medical College, New Delhi, India

Phone: +91 9013923019

Email: doctorpriti@gmail.com

Date of Submission : 29/01/2022

Date of Final Revision : 01/04/2022

Date of Acceptance : 05/04/2022

Date of Publication : 30/04/2022

Financial or other Competing Interests: None.