



## Unveiling the Spectrum: Pathological Perspectives on Neuroendocrine Neoplasms

Bhumiben Rameshchandra Bhuvu, Hemina Himanshu Desai\*, Twinkle Bhashyantkumar Thakkar, Aesha Amrish Parikh, Hansa Goswami

Pathology Department, B.J. Medical College and Civil Hospital, Asarva, Ahmedabad, Gujarat, India

DOI: 10.21276/APALM.3351

### Abstract

#### Background

Neuroendocrine neoplasms (NENs) account for only 0.5% of all malignancies. The incidence is approximately 2 per 100,000 with a female preponderance under the age of 50 years. The main primary sites are the gastrointestinal tract (62-67%) and lungs (22-27%). In the last decade, the incidence has been rising, which might be due to more awareness, improved diagnostic tools, or a change in definition. Neuroendocrine neoplasms are sporadic, but association with the MEN1 syndrome and clustering within families is known. The 5-year survival is mainly associated with the stage of disease: 93% in local disease, 74% in regional disease, and 19% in metastatic disease.

#### Method

Biopsies received in the Department of Pathology, B.J. Medical College, Ahmedabad over the past 2 years were included. Biopsies were fixed and processed by routine paraffin method, stained by H&E, and also immunohistochemistry was performed.

#### Results

A total of 50 cases were received, with about 56% males and 44% females, with a median age of 50 years. In our study, most of the tumors were found in the gastro-entero-pancreatic system, followed by the breast and broncho-pulmonary group. NENs were graded based on mitotic count. In total, 12 had G1 grade, 15 had G2 grade, 22 had G3 grade, and 1 was placed in the NEC category. Lymph node or distant site metastasis was not found in any of the cases.

#### Conclusion

According to our study, the age of presentation of NENs is in the 5th to 6th decade, and the majority occur in the GEP group. Grading of NEN should be carried out according to the latest WHO criteria and is crucial for prognosis and management of patients.

#### Keywords:

*Neuroendocrine neoplasm, biopsy, grading, pathology spectrum*

#### \*Corresponding Author:

Dr Hemina Himanshu Desai  
[hemina@gmail.com](mailto:hemina@gmail.com)

Submitted: 09-Apr-2024

Final Revision: 10-May-2024

Acceptance: 02-Jun-2024

Publication: 11-Jul-2024



This work is licensed under the  
Creative Commons Attribution 4.0  
License. Published by Pacific Group  
of e-Journals (PaGe)

## Introduction

Neuroendocrine neoplasms (NENs) are a group of rare cancers. The incidence is approximately 2/100,000, with a female preponderance under the age of 50 years. The main primary sites are the gastrointestinal tract (62-67%) and the lung (22-27%).

The concept of functional neuroendocrine tumors can be defined as the secretion into the bloodstream of bioactive substances by the neoplastic cells[1]. Most neuroendocrine tumors are mainly sporadic, but association with multiple endocrine neoplasia type 1 syndrome and clustering within families is known[2].

In 1907, Oberndorfer first described these tumors as “carcinoid,” a carcinoma-like tumor which was considered to have less malignant potential. In 2000 and 2004, respectively, the World Health Organization (WHO) classified neuroendocrine tumors (NETs) into well-differentiated tumors and poorly differentiated tumors[4]. According to the WHO 2010 classification, GEP-NENs are classified as NET and neuroendocrine carcinoma (NEC) based on cell proliferation[5]. In the WHO 2017 classification and AJCC 8th edition, those tumors with typical morphology of well-differentiated tumors and with mitoses up to >20/10 HPF are classified as “well-differentiated NET.” This grading scheme (Grade 1–3) is based on the mitotic activity or Ki-67 index, which is recommended for well-differentiated GEP-NETs[6]. The separation of NET G3 from NEC was defined in the pancreas first in the WHO 2017 classification and adapted to the entire GEP-system in the most recent WHO 2019 classification[7]. The classification of NETs of the lung is different, being divided into low- (typical and atypical carcinoid) and high- (large cell and small cell neuroendocrine carcinoma) grade[5].

Histopathology is fundamental for the diagnosis of neuroendocrine neoplasms (NENs). Biomarkers and imaging can certainly provide clues, but a biopsy is needed for confirmation. In NENs, tumor cells are characteristically arranged in well-developed “organoid” patterns like nesting, trabecular, or gyriform/serpentine growth patterns. The tumor cells are small with relatively uniform round to oval nuclei, inconspicuous nucleoli, and a fine to coarsely granular chromatin pattern described as “salt and pepper.” Neuroendocrine carcinomas (NECs), on the other hand, present as a solid proliferation of less monomorphic cells with either scant (small cell) or abundant (large cell) cytoplasm, irregular nuclei with severe nuclear molding, and high mitotic rates. Small-cell NECs display hyperchromatic nuclei with “salt and pepper” chromatin, while large-cell NECs exhibit vesicular nuclei with conspicuous nucleoli, which can be large and eosinophilic. Areas of necrosis and apoptotic bodies are commonly seen[3].

Several Indian researchers have studied neuroendocrine neoplasms. This study aims to address several aspects of these rare neoplasms, including demographic data like age, gender, and anatomical site distribution in our Indian population. We have also studied various clinical presentations of these neoplasms in the Indian population.

The aims and objectives of this study are to evaluate age and gender-wise distribution of neuroendocrine neoplasms, to find out the anatomical distribution of neuroendocrine neoplasms, to unveil the histomorphological spectrum of neuroendocrine neoplasms, and to analyze the clinical presentation of neuroendocrine neoplasms (NENs).

## Materials and Methods

The present study was carried out at the Department of Pathology, B.J. Medical College, Ahmedabad. Fifty cases of neuroendocrine neoplasms, which underwent biopsy for histopathological examination during the period from March 2022 to February 2024, were included in this study. Detailed history regarding age, sex, clinical symptoms, and site were collected in all cases. The WHO 2019 classification was used for the categorization of NENs, utilizing morphological findings and classifying the cases histopathologically. All biopsies were fixed in 10% neutral buffered formalin, processed by the routine paraffin method, and stained with hematoxylin and eosin. Biopsy specimens were analyzed with regard to the following points: tumor location and type, neuroendocrine morphology, grade of tumor with degree of differentiation, and IHC done by peroxidase-antiperoxidase methods.

Grading was done according to the European Neuroendocrine Tumor Society (ENETS)/WHO grading criteria [8].

Data analytics: Quantitative data will be entered in a Microsoft Excel worksheet from the LIS of our institute and will be analyzed using descriptive statistics.

## Results

We identified a total of 50 patients diagnosed with NETs, of which 28 were male and 22 were female. The mean age at diagnosis was 50 years (range: 30-70 years) (see Figure 7).

**Site-wise distributions of NENs:** The most common primary site was the small intestine (n = 15), followed by the ileocolic junction (n = 10), colon (n = 8), appendix (n = 6), pancreas (n = 4), breast (n = 3), rectum (n = 2), prostate (n = 1), lung (n = 1), and stomach pylorus (n = 1) [see Chart 2 and Table 1].

*Table 1: Site wise distribution*

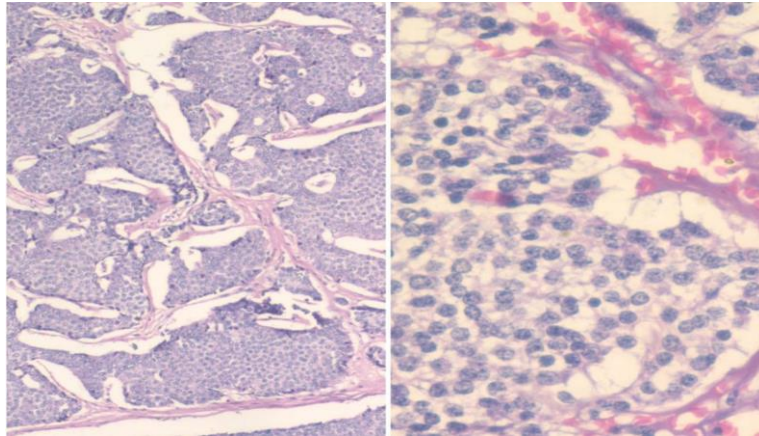
Site	Numbers
Appendix	6
Breast	3
Small intestine	15
Colon	8
ICJ	10
Pancreas	4
Lung	1
Rectum	2
Prostate	1
Pylorus	1
Total	50

**Clinical Symptoms:** Of 50 patients, 41 (82%) presented with only nonfunctional symptoms, 6 (12%) had purely functional symptoms, and 3 (6%) presented with both functional and nonfunctional symptoms. Thus, only 9 (18%) of 50 patients presented with functional symptoms. Of the 9 patients who had functional symptoms, watery diarrhea was the most common symptom, seen in 6 (66%), followed by flushing (26%), bronchospasm and cough (8%). Among patients with GEP-NEN, abdominal pain was the most common presenting symptom, seen in 72% of cases, followed by vomiting (11%), heaviness in the abdomen (8%), weight loss (6%), bleeding PR (2%), and anorexia (1%). The overall spectrum of symptomatology in NENs is shown in Chart 3 (see Chart 3).

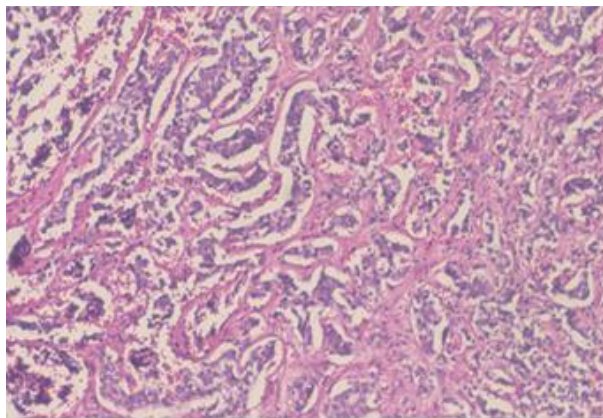
**Histopathological spectrum:** The growth patterns in NENs were either predominantly or a combination of nested (Figure 1), insular, trabecular (Figure 2), festoon, and gyriform (n = 33). NEC had a more diffuse growth pattern (n = 17). Tumors are graded by mitotic count for staging. Of the total 50 patients, 11 patients had NET G1 (22%), 16 patients had NET G2 (32%), 22 patients had NET G3 (44%), and 1 patient had NEC (2%) (Figure 4) (see Table 2). IHC for NENs showed positivity for markers Chromogranin and Synaptophysin (Figure 6).

**Site and grade-wise distribution of NECs:** Overall, NET G1 and NET G2 were most common in the small intestine, ileocolic junction, and colon. The incidence of NET G3 was the highest in the pancreas (n = 4/21) (Figure 5), followed by the appendix (n = 3/21). Among GEP-NENs, the large intestine, appendix, pancreas, and stomach had predominantly high-grade disease, whereas the small intestine, ICJ, and rectum had predominantly low/intermediate-grade disease. Among non-GEP-NENs, lung and breast

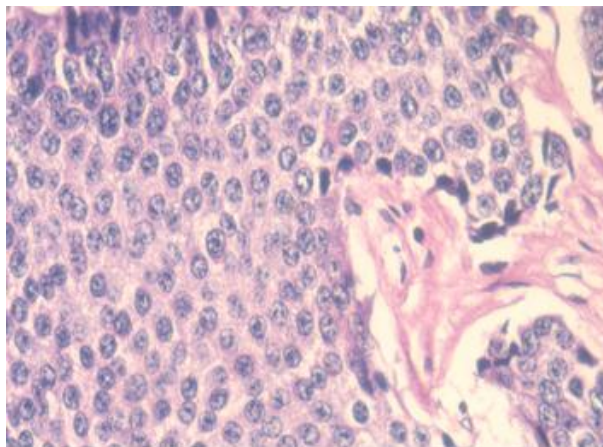
NENs were predominantly high grade. The distribution of GEP-NENs according to site and grade is summarized in Table 3 (see Table 3).



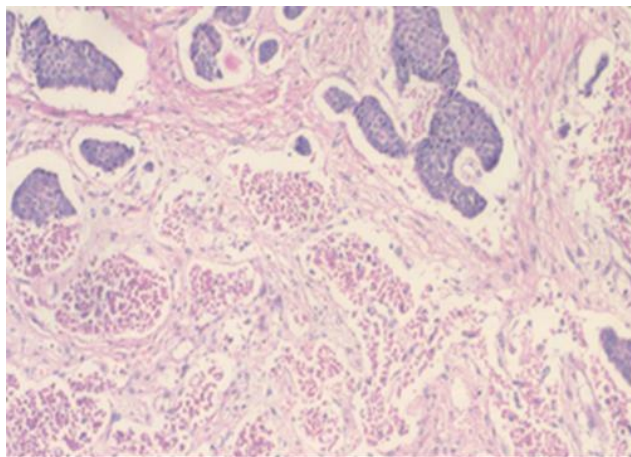
**Figure 1: Well-differentiated NET Grade 1 nesting pattern with round to oval nuclei, salt and pepper chromatin, and no mitosis in this figure in H&E stain (10x; 40x).**



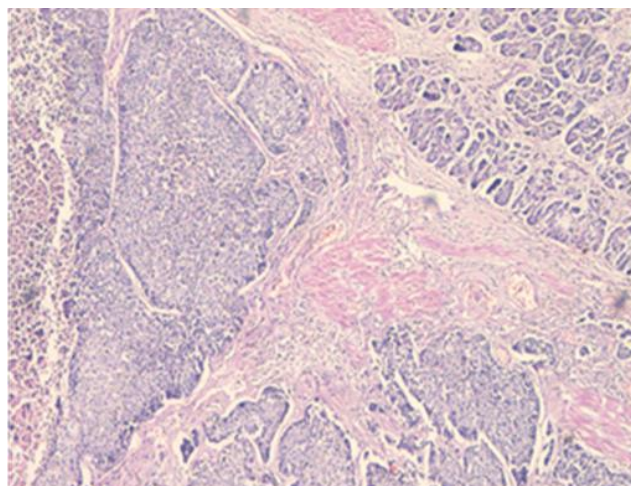
**Figure 2: NET G2 with trabecular pattern in H&E stain (20x).**



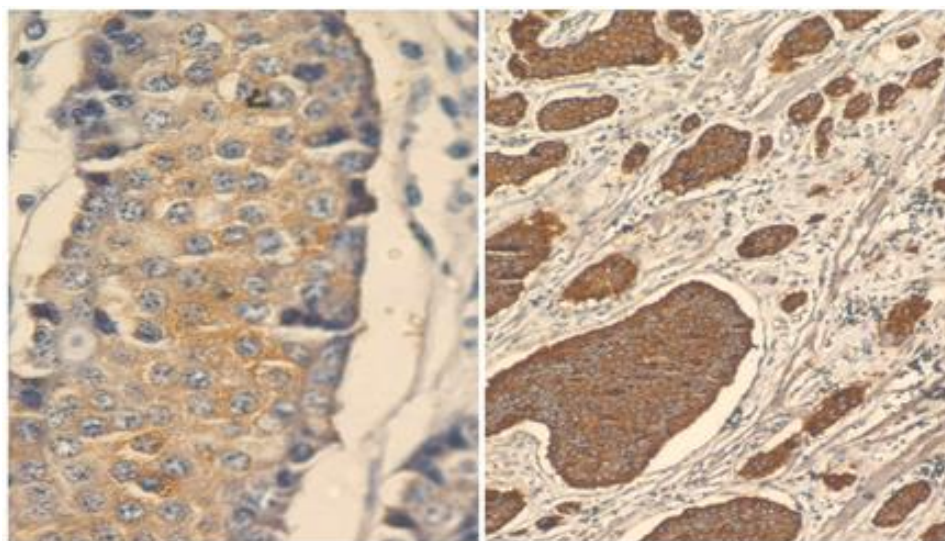
**Figure 3: Poorly differentiated NET G3 in H&E stain (40x).**



**Figure 4: NEC with necrosis in H&E stain (10x).**



**Figure 5: PanNET G3 on H&E stain (20x).**



**Figure 6: Immunohistochemistry for synaptophysin (40x) and chromogranin A (40x).**

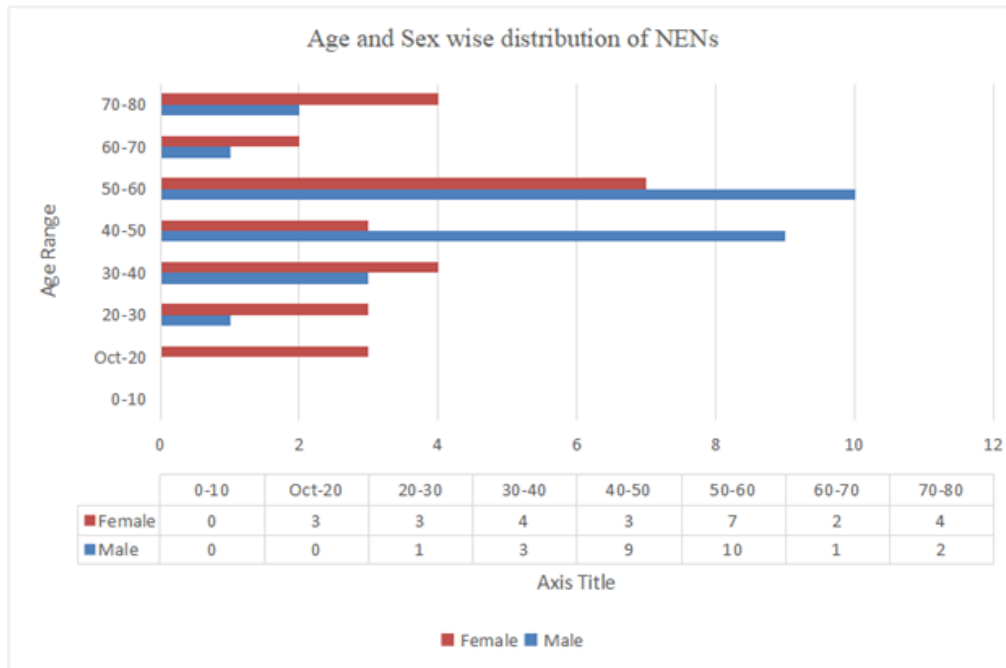


Figure 7: Age and sex-wise distribution.

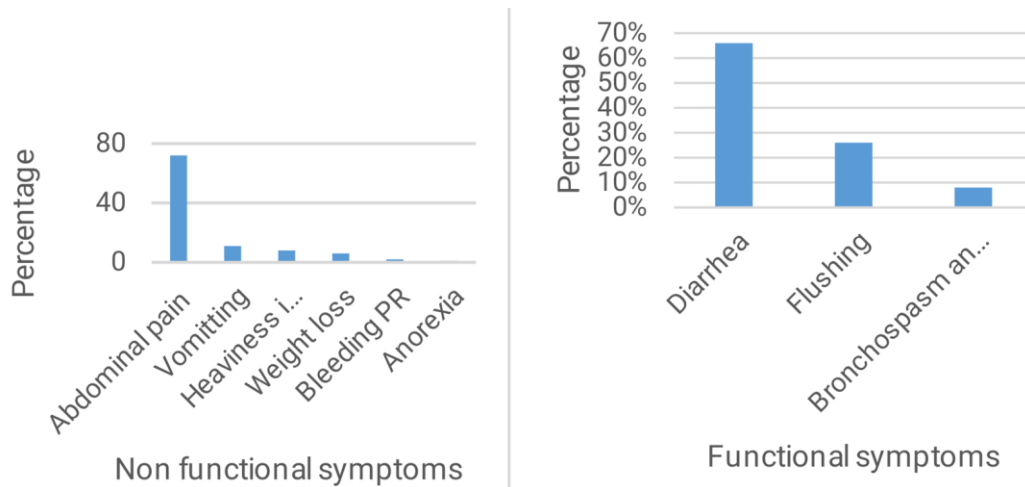


Figure 8: Clinical symptoms.

Table 2: Distribution of case according to degree of differentiation

<b>Well differentiated</b>	<b>G1</b>	<b>11</b>
	<b>G2</b>	<b>16</b>
	<b>G3</b>	<b>15</b>
<b>Poorly differentiated</b>	<b>08</b>	
<b>Total</b>	<b>50</b>	

**Table 3: Site & grade wise distribution**

Site	G1	G2	G3	NEC	Total
Appendix	1	1	3	1	6
Small intestine	3	6	5		13
ICJ	3	5	2		10
Colon	1	3	4		8
Rectum	2	-	-		2
Pancrease	-	-	4		4
Breast	-	1	2		3
Stomach	-	-	1		1
Prostate	1	-	-		1
Lung	-	-	1		1
<b>Total</b>	<b>11</b>	<b>16</b>	<b>22</b>	<b>1</b>	<b>50</b>

## Discussion

This study focuses on the demography, clinicopathological characteristics, and histopathological spectrum applied in patients with all types of NENs. Various studies across the world have reported variations in the age, sex distribution, primary site, and patterns of disease presentation in Western countries and Asian regions. The median age of presentation in Kulkarni et al. [16] is 50 years, which is similar to our study, which is also 50 years. Furthermore, the analyses of the surveillance, epidemiology, and end results program (SEER) database and Norwegian studies have reported female preponderance. However, the male predominance seen in our population can be because males are more likely to present to health care facilities in the Indian setup [10]. Western literature has documented the relationship between diet and neuroendocrine neoplasms [17]. However, no such data is available in Indian literature as per our knowledge.

In an Indian retrospective analysis of GEP-NENs, the most common site of the primary tumor was the stomach (30.2%), followed by the pancreas (23.3%) [10]. However, in an Iraqi study [11] and another recent Indian study by Kapoor et al. [14], the pancreas was the most common primary site, seen in 26.3% and 35.2% of cases, respectively. The largest SEER analysis reports the lung as the most common site of primary NEN, whereas the Norwegian study [7] and Taiwanese study [8] found the small intestine, colon, and rectum as the most common primary sites, respectively, which is similar to our study. Overall, the above studies showed that there are possible ethnic and regional variations in the primary site of origin of NENs, with pancreatic NENs being more common in Indian literature as compared to Western literature (see Table 4).

**Table 4: Comparison of site wise distribution**

Primary site rank	Our study	Yao JC et al. (US Whites)	Yao JC et al. (US Asians/PI)	Hauso O et al.	Tsai HJ et al.	Kapoor R et al.
1	Small intestine (26%)	Lung (30%-32%)	Rectum (41%)	Small intestine (26%)	Rectum (25%)	Pancreas (35.2%)
2	ICJ(20%)	Small intestine (18%-19%)	Lung (15%)	Lung (21%)	Lung (20%)	Periampullary (21.5%)
3	Colon(14%)	Unknown primary (13%)	Pancreas (8%)	Colon (8%)	Stomach (7%)	Small intestine (13.7%)
4	Appendix (12%)	Rectum (12%)	Small intestine (8%)	Rectum (7%)	Pancreas (6%)	Retroperitoneum (9.8%)
5	Pancreas (8%)	Colon (7%-8%)	Stomach (6%)	Pancreas (7%)	Colon (5%)	Unknown primary

Recent studies have shown that a small subset of patients differentiated are associated with a mitotic count (3-20/hpf) or high Ki67 proliferation indices (>20%), thus falling into the high-grade (G3) range in the current WHO grading scheme. The clinical behavior of these grade-discordant tumors is somewhat worse than grade-concordant well-differentiated G2 tumors but better than that of bona fide poorly differentiated NECs. In limited literature available, the incidence of well-differentiated Grade 3 NETs has been reported between 5.6% and 8% of the GEP-NETs in various studies. In our study group, we had only 2 cases of ileal NEN (4% overall and 4.6% of GEP-NENs) with histologically low-grade NET with low mitosis, but with a Ki67 index of 25%, thus fitting into the category of well-differentiated high-grade NEN.

There are certain limitations in our study. The most important limitation was a shorter follow-up, and many patients were lost to follow-up after subsequent response evaluation, because of which median PFS could not be reached. These patients were included in EFS analysis with the event truncated at the last follow-up. Furthermore, DOTANOC scanning, serum chromogranin A testing, and newer treatment modalities such as PRRT were not available due to limited resources. Larger multicentric data with longer follow-up are essentially required for better defining the disease characteristics in the Indian population. The Indian Council of Medical Research has released a document regarding the standard management of these rare tumors [15].

## Conclusion

NENs are more common in the GIT. They occur more frequently in the older age group. Functional NENs are less common in our study as well as in other Indian studies, suggesting a different biological profile in the Indian population. If diagnosed when the tumor reaches a poorly differentiated grade, there is an urgent unmet need for creating awareness regarding the symptomatology, diagnostic modalities, and formulating Indian NEN guidelines for optimal treatment of patients. The clinical guidelines and practices based on our findings are as follows: In low-grade G1/G2 tumors, surgery is the main treatment approach, while metastatic disease/neuroendocrine carcinoma will be treated by chemotherapy and palliative measures. So, grading of these rare tumors is of utmost importance, and therefore the role of the pathologist is pivotal for patient management. More multi-institutional studies are required to better define the epidemiological and clinical profile of this "rare" but "not so rare" disease.

**Funding:** None

**Competing Interests:** The authors declare that they have no conflict of interest.

**Statement of Ethical Approval for the Study:** Ethical approval was taken from the college ethical committee.

**Statement of Informed Consent:** The patients were informed about the FNA procedure, and consent was taken.

**Acknowledgements:** I would like to extend my gratitude to Dr. Hansa Goswami (Professor & Head of the Department of Pathology, BJMC) who gave me this opportunity. I am grateful to my guide, Dr. Hemina Desai (Associate Professor), and my colleagues for their thoughtful intervention. I would also like to thank all my teachers and laboratory staff for their support.

## References

1. Hallet J, Law CH, Cukier M, Saskin R, Liu N, Singh S. Exploring the rising incidence of neuroendocrine tumors: a population-based analysis of epidemiology, metastatic presentation, and outcomes. *Cancer*. 2015 Feb 15;121(4):589-97.
2. Klimstra DS, Beltran H, Lilenbaum R, Bergsland E. The spectrum of neuroendocrine tumors: histologic classification, unique features and areas of overlap.



3. Gheorghişan-Gălăţeanu AA, Ilieşiu A, Lambrescu IM, Țăpoi DA. The complex histopathological and immunohistochemical spectrum of neuroendocrine tumors—an overview of the latest classifications. *Int J Mol Sci.* 2023;24(2):1418.
4. Zandee WT, van der Zwan JM, de Herder WW, van Velthuysen ML. Importance of complete pathology reporting for neuroendocrine carcinoma: WHO guidelines are a good start but not enough.
5. Samanta STN, Mehta SP, Patel TS, Jetly DH. Clinicopathological study of 100 cases of neuroendocrine neoplasms of the gastroenteropancreatic system: a tertiary cancer center experience. *Indian J Med Paediatr Oncol.* 2020;41(3):340-4.
6. Silveira F, Basile ML, Kuga FS, Próspero JD, Paes RA, Bernardi FDC. Neuroendocrine tumors: an epidemiological study of 250 cases at a tertiary hospital.
7. Bräutigam K, Rodriguez-Calero A, Kim-Fuchs C, Kollár A, Trepp R, Marinoni I, Perren A. Update on histological reporting changes in neuroendocrine neoplasms. *Curr Oncol Rep.* 2021 Apr 14;23(6):65.
8. Rosai J, Ackerman LV, Rosai J. *Rosai and Ackerman's Surgical Pathology.* 10th ed. New York: Mosby; 2011.
9. Choe J, Kim KW, Kim HJ, Kim DW, Kim KP, Hong SM, et al. What is new in the 2017 World Health Organization classification and 8th American Joint Committee on Cancer staging system for pancreatic neuroendocrine neoplasms? *Korean J Radiol.* 2019 Jan;20(1):5-17.
10. Abdulfattah MK, Al-naqqash MA. The clinico-epidemiologic characteristics of Iraqi patients with neuroendocrine tumors and their response to long acting octreotide. *J Fac Med Baghdad.* 2016 Jan 3;58(4):312-5.
11. Yao JC, Hassan M, Phan A, Dagohoy C, Leary C, Mares JE, et al. One hundred years after “carcinoid”: epidemiology of and prognostic factors for neuroendocrine tumors in 35,825 cases in the United States. *J Clin Oncol.* 2008 Jun 20;26(18):3063-72.
12. Hauso O, Gustafsson BI, Kidd M, Waldum HL, Drozdov I, Chan AK, Modlin IM. Neuroendocrine tumor epidemiology: contrasting Norway and North America. *Cancer.* 2008 Nov 15;113(10):2655-64.
13. Hafeez U, Joshi A, Bhatt M, Kelly J, Sabesan S, Vangaveti V. Clinical profile and treatment outcomes of advanced neuroendocrine tumours in rural and regional patients: a retrospective study from a regional cancer in North Queensland, Australia. *Intern Med J.* 2017 Mar;47(3):284-90.
14. Kapoor R, Bhattacharyya T, Gupta R, Mittal BR, Kalra N. A systematic review of management of neuroendocrine tumors: an experience from a tertiary care centre from India. *Clin Cancer Investig J.* 2014 Sep 1;3(5):363-72.
15. Sirohi B, Barreto SG, Shrikhande SV, Bhandare M, Bal M, Chacko RT, et al. Indian Council of Medical Research consensus document for the management of gastroenteropancreatic neuroendocrine neoplasms. *Indian J Med Paediatr Oncol.* 2020;41(2):166-72.
16. Kulkarni RS, Anand AS, Parikh SK, Panchal HP, Patel AA, Mehta DP, Patel P. Clinical and epidemiological profile of neuroendocrine tumors: an experience from a regional cancer center from Western India. *South Asian J Cancer.* 2019 Jul-Sep;8(3):198-202.
17. Muscogiuri G, Barrea L, Cantone MC, Guarnotta V, Mazzilli R, Verde L, et al. Neuroendocrine tumors: a comprehensive review on nutritional approaches. *Cancers (Basel).* 2022 Sep 10;14(18):4402