

# Case Report: Solid Variant of Aneurysmal Bone Cyst: A Rare Entity

Renuka Verma<sup>1</sup>, Chetna Dhok<sup>1,\*</sup>, Anjali Ahalawat<sup>1</sup>, Mehak Jindal<sup>1</sup>, Sonia Chhabra<sup>1</sup>, Umesh Yadav<sup>2</sup>

<sup>1</sup>Department of Pathology, Pt. B. D. Sharma Post Graduate Institute of Medical Sciences, Rohtak, India

<sup>2</sup>Department of Orthopedics, Pt. B. D. Sharma Post Graduate Institute of Medical Sciences, Rohtak, India

\*Correspondence: chetnadhok2@gmail.com

### DOI

[10.21276/apalm.3681](https://doi.org/10.21276/apalm.3681)

### Article History

Received: 29-08-2025

Revised: 20-02-2026

Accepted: 21-03-2026

Published: 06-04-2026

### How to cite this article

Verma R, Dhok C, Ahalawat A, et al. Case Report: Solid Variant of Aneurysmal Bone Cyst: A Rare Entity. *Ann Pathol Lab Med.* 2026;13(4):C106-C110.

### Copyright



This work is licensed under the [Creative Commons Attribution 4.0 License](https://creativecommons.org/licenses/by/4.0/). Published by Pacific Group of e-Journals (PaGe).

### Abstract

Aneurysmal bone cyst (ABC) is a rare benign lesion of bone. It most commonly involves meta-diaphysis of the long bones and posterior elements of the vertebrae. Solid variant of ABC (sABC) is extremely rare. It is benign but aggressive tumor thus requires early diagnosis and treatment. We report a case of sABC occurring in 20 yr male which involved proximal phalanx (pp) of the great toe. Magnetic Resonance Imaging (MRI) demonstrated an expansile osteolytic lesion with cortical thinning of medial aspect of base of pp and mild marrow edema of the great toe. Curettage was done and histopathological examination (hpe) revealed large number of multinucleated osteoclast like giant cells with fibroblastic proliferation, areas of hemorrhage, hemosiderin-laden macrophages and woven bone along with few blood-filled cystic spaces and cartilaginous tissue. The diagnosis was established through a multimodal approach integrating radiological assessment and biopsy findings. Early intervention can lead to better prognosis.

**Keywords:** aneurysmal bone cyst (ABC); solid variant of aneurysmal bone cyst (s-ABC); proximal phalanx great toe; rare; benign

### Introduction

Aneurysmal bone cyst is a benign lytic lesion of bone accounting for 1% of the primary bone tumors out of which only 3% occurs in foot.[1] It mostly occurs in immature skeletal system usually in first two decades of life with equal prevalence in males and females. The term "aneurysmal" represents the blown-out, distended contour of the affected bone and the term "cyst" indicates that the disease has fluid filled cavity.[2, 3, 4]

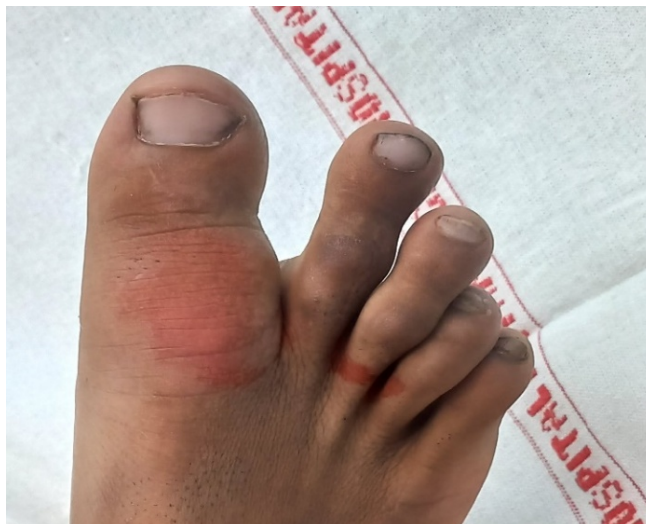According to recent WHO classification of Tumors of Bones (2020), ABCs have been recognised as Tumors Rich in Giant Cells. Also the terms "ABC" and "ABC-like changes," which are present within some pre-existing primary bone neoplasms, are suggested in place of "primary ABC" and "secondary ABC", respectively. About 70% of cases "ABC" regarded as primary bone lesions are not associated with underlying bone abnormality, whereas the remaining 30% of "ABC-like changes" are associated with primary bone abnormalities.[5]

sABC lacks cystic features and is typically found in the solid parts of bones. It constitutes 3.4% to 7.5% of overall ABC cases. It usually affects the short tubular bones of the hands and feet where metaphysis is the preferred site and are rarely found in long bones.[6]

Recent studies have shown that ABCs is a clonal neoplastic process due to recurrent chromosomal translocations associated with the USP6 located on short arm of chromosome also known as Tre-2. About 65–70% of individuals with ABC had USP6 rearrangements and 30% have CDH 11-USP6 fusions, respectively.[2, 3]

## Case Presentation

A 20-year male came to OPD with chief complaint of pain in right great toe since 5 months. On examination, a cystic lesion was identified in proximal phalanx of right great toe (Fig. 1).



**Figure 1:** Swelling of 4x2 cm at medial aspect of proximal phalanx of right great toe.

Patient did not have similar lesion anywhere else in the body and no other complaints. X-Ray revealed as a well-defined, eccentric, osteolytic expansion lesions with clear border lesion (Fig. 2).

MRI revealed an expansile osteolytic lesion in the proximal phalanx of right great toe along the lateral aspect with cortical thinning of medial aspect of base of pp and mild marrow edema of the great toe. Based on clinical and radiological findings, two possibilities were suggested i.e. aneurysmal bone cyst and giant cell tumor. To confirm the diagnosis, conventional curettage was performed using local anaesthesia and sent for histopathological examination.

Grossly multiple grey-brown to tan, soft to firm tissue pieces measuring 4x2.5x1 cm, were received. Few cystic structures were identified.

Microscopic examination revealed large number of multinucleated osteoclast like giant cells with fibroblastic proliferation, areas of hemorrhage, hemosiderin-laden macrophages and woven bone along with few blood-filled cystic spaces and cartilaginous tissue. Features were consistent with solid variant of ABC.

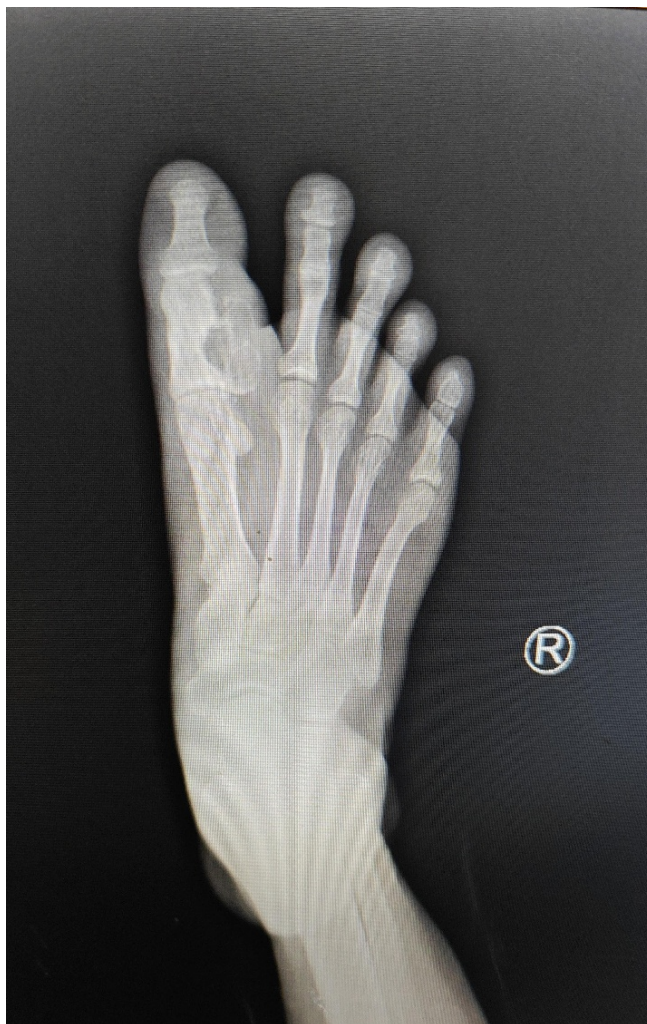As the patient was loss to follow up further intervention and prognosis could not be obtained.

## Discussion

Solid variant of ABC though in itself is a rare benign entity found in small bones of hand and feet particularly phalanges. Diagnosing the lesion is difficult based on clinical details and radiological investigation, here histopathological investigation plays a major role.

"Solid variant" of ABC has been used interchangeably with histologically indistinguishable term "giant-cell reparative granuloma", that lesion involve gnathic location like mandible, maxilla or short tubular bones of hands and feet. In WHO Classification of Tumors of Bone (2020), this terminology has changed to the solid variant ABC which previously represented tumors located in the small bones of hands and feet. Solid variant of ABC characteristically lacks blood-filled cystic spaces, hence a predominantly solid architecture is seen. ABC-like changes may be associated with several primary bone lesions, with focal histological features similar to those seen with ABC; however, in those cases there is no rearrangements of the USP6 gene at chromosome band 17p13.2. Therefore, proper biopsy of the sample which include solid variant along with genetic confirmation is required to distinguish ABC from other ABC-like changes.[4]

For diagnosis, various imaging modalities can be used such as computed tomography scan (CT scan) and magnetic resonance imaging (MRI) which showed the characteristic features of an expansile, radiolucent lesion that is often seen in the metaphyseal region of the bone and has fluid-fluid levels that are apparent on T2-weighted MRI.[3, 7]



**Figure 2:** X-ray right leg AP view.



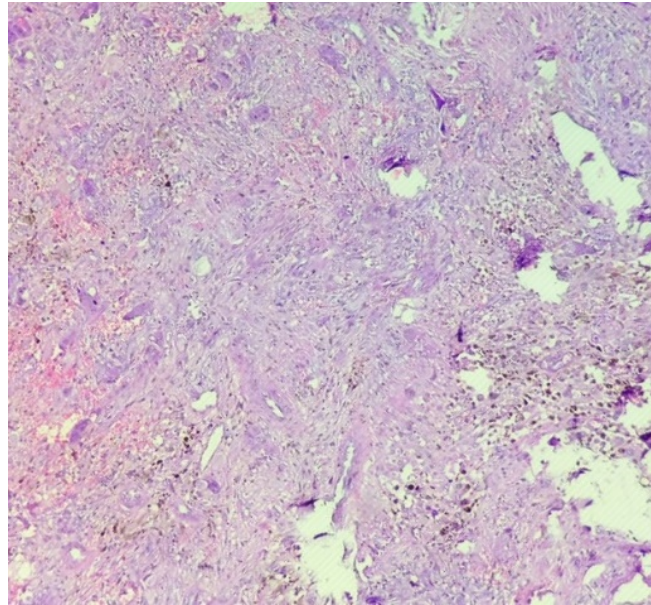
**Figure 3:** Multiple grey-brown to tan, soft to firm tissue pieces measuring 4x2.5x1 cm showing congestion and few cystic areas.

Giant cell tumor, one of the differential diagnoses, is a neoplastic, locally aggressive tumor that commonly affects the third to fifth decade of life. Radiographically, these lesions are purely lytic and located eccentrically in the epiphyses of long bones, affecting the subchondral bone along with frequent cortical expansion or interruption. On histopathological examination, these lesions have mononuclear cells, macrophages, and uniformly distributed multinuclear giant cells.[3, 5]

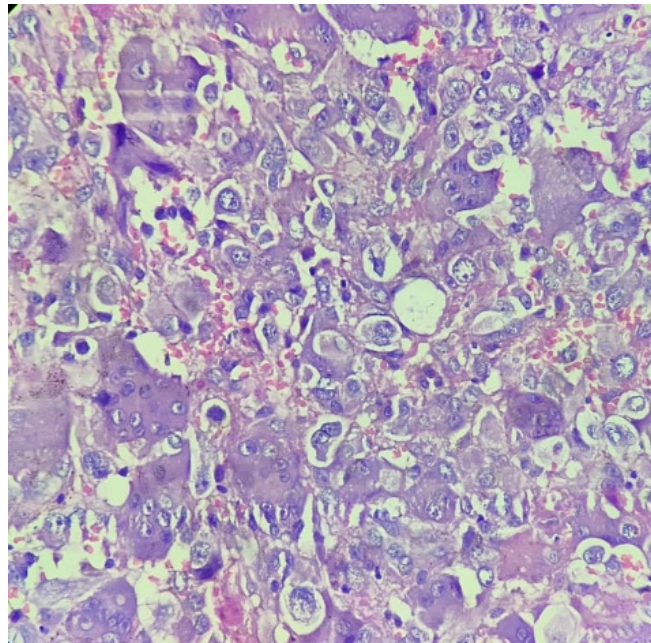
ABC has shown an overall good prognosis. The goal of treatment is to slow down disease progression and symptomatic relief involving fixation or prevention of fractures. En block resections are avoided as it can cause functional impairment and morbidity. In one third of the treated cases, local recurrence can be seen within a few months. In case of ineffective treatment or impractical treatment denosumab can be utilized.[3]

## Conclusion

sABC is a rare benign aggressive lytic bone tumor. This case highlights the importance of a systematic diagnostic approach integrating clinical evaluation, radiological imaging, and histopathological confirmation to establish an accurate diagnosis



**Figure 4:** H&E stained sections at high power (100x) respectively showing areas of haemorrhage and cystic spaces.



**Figure 5:** H&E stained sections at high power (400x) respectively showing areas of haemorrhage and multinucleated giant cells. and differentiate ABC from other lytic bone lesions. Early confirmation with the help of histopathological examination is crucial, as timely surgical intervention can prevent progressive bone destruction, deformity, and functional impairment.

**Acknowledgements:** Dr. Sunita Singh

**Funding:** NA

**Competing Interests:** NA

## References

1. Vedel JC, Johansen JK. Aneurysmal Bone Cyst in a Phalanx of a Toe. *Clin Res Foot Ankle*. 2016;4:219. doi: [10.4172/2329-910X.1000219](https://doi.org/10.4172/2329-910X.1000219)
2. Elham N, John DR. Aneurysmal bone cyst: a review. *JPTM*. 2023;57:81-87. doi: [10.4132/jptm.2023.02.23](https://doi.org/10.4132/jptm.2023.02.23)
3. Bakarman KA. Diagnosis and Current Treatment of Aneurysmal Bone Cysts. *Cureus*. 2024;16(2):e53587. doi: [10.7759/cureus.53587](https://doi.org/10.7759/cureus.53587)
4. Omar F et al. A remarkable and aggressive aneurysmal bone cyst ravaging the femoral shaft, advancing to lung metastases: An extremely rare case. *Int J Surgery Case Reports*. 2023;108:108414. doi: [10.1016/j.ijscr.2023.108414](https://doi.org/10.1016/j.ijscr.2023.108414)
5. WHO Classification of Tumours Editorial Board. *Soft tissue and bone tumours*. 5th edn. Lyon: International Agency for Research on Cancer; 2020.

6. Akhil SR, Sreeraj R, Subin S. An unusual presentation of solid variant ABC: A case report. *Journal of Orthopaedic Reports*. 2024;3:100336.
7. Bianchi C et al. Benign bone and soft tissue tumors of the foot. *EFORT Open Reviews*. 2024;9:1060–1076.