



Case Report

Radio-cytological diagnosis of nodulocaseous tubercular lymphadenitis: a clinical dilemma

Ankit Kaushik*, Disha Arora, Sachin Kolte, Kusum Gupta, A K Mandal

Department of Pathology, Vardhman Mahavir Medical College and Safdarjung Hospital, New Delhi, India

Keywords: Tubercular lymphadenitis, Ultrasound, FNAC, Breast

Abstract

Nodulocaseous tubercular lymphadenitis is a rare entity presenting with ill-defined breast lump, accompanied by non-specific systemic presentation. We present a case report of a young female patient presenting with breast lump and no definitive clinical diagnosis. The radiological investigation like ultrasound breast revealed multiple enlarged nodulocaseous lymph nodes in all four quadrants of breast. The presence of epithelioid cell granuloma with necrosis on fine needle aspiration cytology established primary diagnosis of intramammary tubercular lymphadenitis.

Nodulocaseous tubercular lymphadenitis breast often presents with atypical presentation and primary diagnosis is often difficult to establish. The case establishes the role of ultrasound breast and fine needle aspiration cytology being rapid and cost effective way of diagnosing this lesion.

***Corresponding author:**

Dr. Ankit Kaushik, B-19 Mahesh Park, Modinagar, Ghaziabad, UP, India
Email: Kaushikankit30@yahoo.co.in, Phone. +91-9953816240.

Date of Submission: May 30, 2014

Date of Acceptance: Sept 28, 2014

Date of Publishing: Jan #, 2015



Introduction

Primary breast tuberculosis is a rare form of tubercular lymphadenitis with very few cases being reported in literature.^[1] The incidence of breast tuberculosis is said to be less than 0.1% of breast lesions in the developed world,^[2,3] but in developing countries like India the incidence is expected to be quite high.^[4] The diagnosis of breast tuberculosis is often missed or over-diagnosed as carcinoma because of its atypical presentation like carcinoma or pyogenic abscess.^[5,6] The ultrasound breast and fine needle aspiration cytology provide an easy and definitive diagnosis.

Case Report

A 17-year-old female was referred to cytology section of pathology department of our tertiary care hospital with complaint of right breast lump for past ten months with no associated signs and symptoms. On physical examination the lump was diffuse and nodular involving whole of right breast with normal overlying skin. A definite primary clinical impression could not be made as the findings were different from common breast lumps of this age like fibroadenoma, adenosis and fibrocystic disease of breast. The patient was investigated for hemogram, ultrasound breast, chest X-ray and fine needle aspiration cytology (FNAC).

The ultrasound right breast was done and it showed multiple well-defined hyperechoic and hypoechoic lesions involving all the four quadrants of breast suggestive of numerous enlarged nodes showing central necrosis. Some of the nodes were completely replaced by necrosis (Figure 1). The draining axillary lymph nodes of ipsilateral axillary side also showed similar findings. The anterior posterior view of chest X-ray was unremarkable. The ultrasound of another breast was unremarkable. A presumptive diagnosis of mixed heterogeneous lesion with a strong suspicion of nodulocaseous tuberculosis was made.

The FNAC was done from right breast lump and the axillary swelling. The aspirated fluid was blood mixed pus. Because of aspirated pus a ZN stain was simultaneously performed along with routine Giemsa stain. On microscopy the Giemsa stained smear showed well-defined granuloma consisting of epithelioid cells in a necrotic background (Figure 2). The ZN stain showed the magenta-colored rod-shaped bacilli confirming ZN stain positive for acid fast bacilli (AFB) (Figure 2 inset).

The axillary swelling also yielded pus like material with similar findings. A final diagnosis of tubercular lymphadenitis was made based on available radiological and cytological findings.

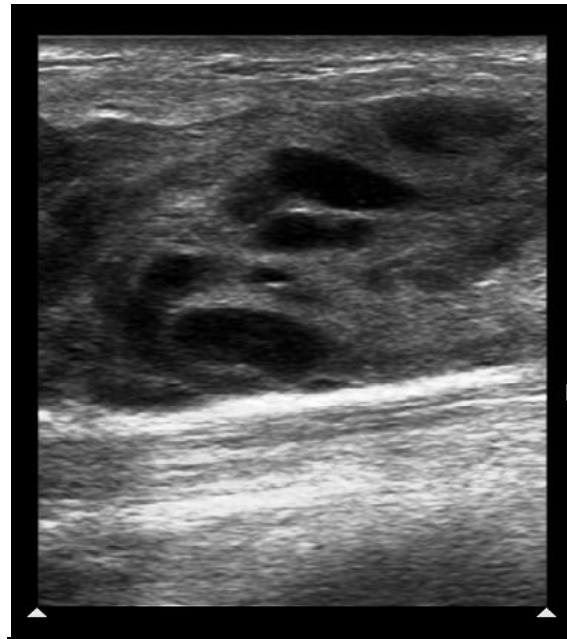


Figure 1: Ultrasound right breast upper outer quadrant showing multiple well-defined hyperechoic and hypoechoic lesions involving all the four quadrants of breast suggestive of numerous enlarged nodes showing central necrosis.

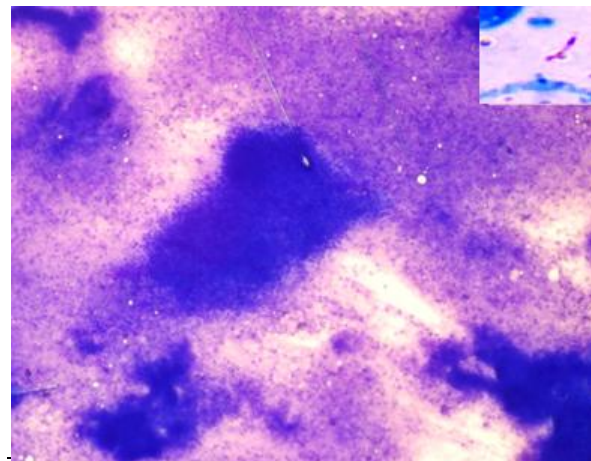


Figure 2: Giemsa stained cytological smear showing ill-defined granuloma with epithelioid cells. Inset showing AFB positive bacilli in the smear by modified Ziehl Nelson stain.

Discussion

Primary breast tuberculosis is a rare form of tubercular lymphadenitis. Like skeletal muscle and spleen, breast provides an infertile environment for tuberculosis and thus proves to be a rare site for it.^[7] Different authors from time to time had proposed regarding the primary and secondary nature of breast tuberculo-

sis. Primary breast tuberculosis is defined when breast is the only site of involvement by tuberculosis with no demonstrable tuberculosis anywhere. Vassilakos^[8] strongly supported that primary breast tuberculosis is extremely rare and another focus is usually missed by the clinician due to its rare site. The usual mode of spread of breast tuberculosis is said to be lymphatic from lungs.^[9] As in our case, reproductive females are the most common affected age group presenting with history of breast lump from few months to years.^[8]

The patients with primary tuberculosis usually present with painful breast lump^[9] with overlying skin involvement in form of multiple discharging sinus or ulceration and peau'd orange-like appearance with extensive axillary involvement.^[10] Unlike abovementioned clinical presentation our patient presented with painless, ill-defined vague lump with normal overlying skin giving a clinical impression of benign fibrocystic breast disease.

Breast tuberculosis is often misdiagnosed and a very high index of clinical suspicion along with radio-pathological and microbiological confirmation is required for diagnosis.^[11] Ultrasound is one of the cheapest investigations which can establish the solid and cystic nature of lesion, and prevent multiple puncture during FNAC without any radiation exposure.^[12] The cytological examination of breast tuberculosis gives a reliable and rapid method of diagnosing breast tuberculosis with presence of epithelioid cell granuloma and necrosis.^[13]

Although we find AFB in our cytology smear, the presence of AFB is not mandatory for diagnosis if epithelioid cell granuloma and necrosis is present.^[14] Thus FNAC can obviate the need of other diagnostic tests like histopathology, culture and PCR^[11] in diagnosing breast tuberculosis. The treatment modalities include ATT and surgery for draining sinuses, but ATT is sufficient in most cases.

Conclusion

Intramammary tubercular lymphadenitis is found rarely and with atypical presentation which makes it a difficult clinical diagnosis. A high degree of clinical suspicion is required for diagnosing breast tuberculosis. Investigations like ultrasound and fine needle aspiration cytology provide rapid and easy means of diagnosis. The presence of epithelioid cell granulomas and necrosis on cytology establishes the diagnosis, and provides a rapid and convenient way for diagnosing breast tuberculosis.

Acknowledgements

None

Funding

None.

Competing Interests

None declared.

References

1. Kalac N, Ozkan B, Bayiz H, Dursun AB, Demirag F. Breast tuberculosis. *Breast*. 2002;11:346-9.
2. Al-Marri MR, Almosleh A, Almoslmani Y. Primary tuberculosis of the breast in Qatar: ten year experience and review of the literature. *Eur J Surg*. 2000;166:687-90.
3. Dharkar RS, Kanhere MH, Vaishya ND, Baisarya AK. Tuberculosis of the breast. *J Indian Med Assoc*. 1968;50:207-9.
4. Mukerjee P, George M, Maheshwari HB, Rao CP. Tuberculosis of the breast. *J Indian Med Assoc*. 1974;62:410-2.
5. Green RM, Ormerod LP. Mammary tuberculosis: rare but still present in the United Kingdom. *Int J Tuberc Lung Dis*. 2000;4:788-90.
6. Sehgal S, Goyal P, Ghosh S, Mittal D, Singh S. Malignancy and Granulomatosis: Causality or Coincidence? Narrative Systematic Review. *Iranian Journal of Pathology*. 2014;9: 237-244
7. Mckeown KC, Wilkinson KW. Tuberculous diseases of the breast. *Br J Surg*. 1952;39:420.
8. Vassilakos P. Tuberculosis of the breast: cytological findings with fine-needle aspiration. A case clinically and radiologically mimicking carcinoma. *Acta Cytol*. 1973;17:160-5.
9. Alagaratnam TT, Ong GB. Tuberculosis of the breast. *Br J Surg*. 1980;67:125-6.
10. Shukla HS, Kumar S. Benign breast disorders in nonwestern populations: Part II - Benign breast disorders in India. *World J Surg*. 1989;13:746-9.
11. Shukla HS, Tewari M. Breast tuberculosis: diagnosis, clinical features & management. *Indian J Med Res*. 2005;122:103-10.
12. Popli MB. Pictorial essay: tuberculosis of the breast. *Indian J Radiol Imag*. 1999;9:127-32.
13. Kakkar S, Kapila K, Singh MK, Verma K. Tuberculosis of the breast. A cytomorphologic study. *Acta Cytol*. 2000;44:292-6.
14. Pagel W, Simmonds FAH, Macdonald J, Nassan E. *Pulmonary Tuberculosis*, 4th edition. London: Oxford University Press; 1964. p. 245.