

## Epidermoid renal cyst: an unusual finding

Dharmendra Rathod\*, Jayprakash Bhatt, Riddhi Khakkhar, Pratyush Parmar

Department of Pathology, Dr. Bhatt Pathology Laboratory, Rajkot, Gujarat, India

*Keywords: Epidermoid Cyst, Renal cyst*

### Abstract

This report describes a case of epidermoid cyst affecting the left kidney of a 52-year-old female. The condition was accidentally discovered during the histopathology examination. Patient presented with complain of burning micturition, nausea, vomiting and fever for 15 days. Grossly, the kidney was distorted cyst like that was filled with a cheesy material. The histological picture of non-functioning kidney was apparent in the compressed renal parenchyma by the cyst that was identical to an epidermoid cyst. In conclusion, although rare, epidermoid cyst of the kidney could cause serious kidney damage leading to a non-functioning of kidney. Epidermoid cyst of the kidney could be multiple, producing a picture similar to hydronephrosis and broadening the differential diagnosis of multicystic disease of the kidney. Timely diagnosis is essential to prevent radical surgery.

**\*Corresponding author:**

Dr. Dharmendra Rathod, Dr. Bhatt Pathology Laboratory 'Akshar house', Rajputpara Main Road, Near Bhutkhana Chowk, Rajkot-1, Gujarat, India

Ph: 91-0281-22234949, E-mail: drrdrathod@yahoo.co.in

**Date of Submission: June 14, 2014**

**Date of Acceptance: Aug 30, 2014**

**Date of Publishing: Jan 28, 2015**



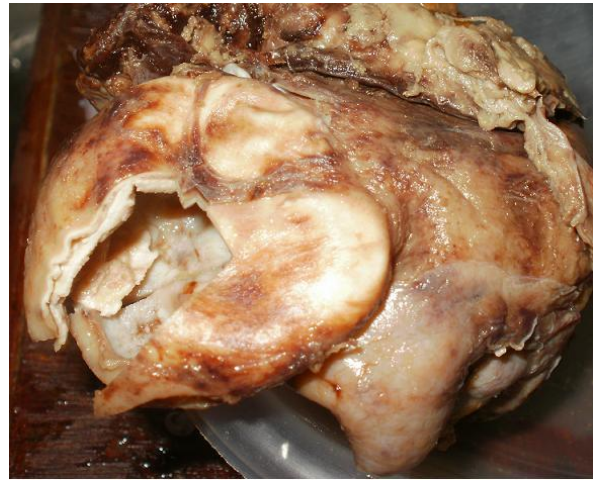## Introduction

Epidermal inclusion cyst defines to those cysts that arise from the implantation of epidermal elements in the dermis.<sup>[1]</sup> However, many cysts originate from the infundibular portion of the hair follicle, and the more general term epidermoid cyst favored. Epidermoid cyst can be arise in various anatomical locations i.e. central nervous system, jaws, ovary, spleen, testis, but the epidermoid cyst in the kidney occurs very rarely and only a few cases have been reported in the English literature.<sup>[1-5]</sup> Although it is a very uncommon lesion, a calcified intra renal lesion has to be suggested as an important landmark for differential diagnosis of renal epidermoid cyst. If a prompt diagnosis of epidermoid cyst is made preoperatively, renal preservation surgery should be done.<sup>[6]</sup> However, a non-calcified soft tissue mass in the renal pelvis is highly suggestive of urothelial carcinoma, nephroureterectomy should be basically considered.

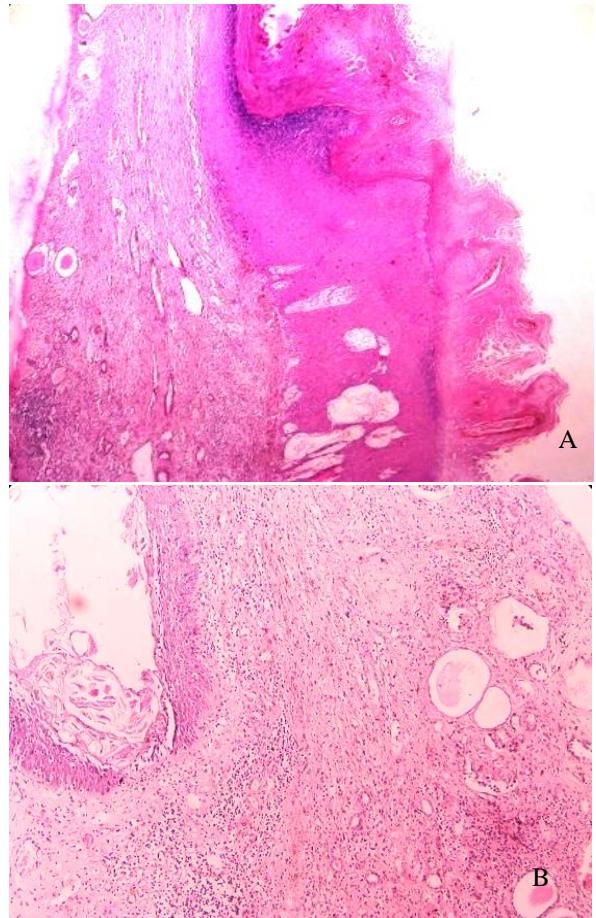
In this report we present an accidentally discovered case of left kidney parenchyma replaced by multilocular cysts pathologically diagnosed to be an epidermoid cyst.

## Case Report

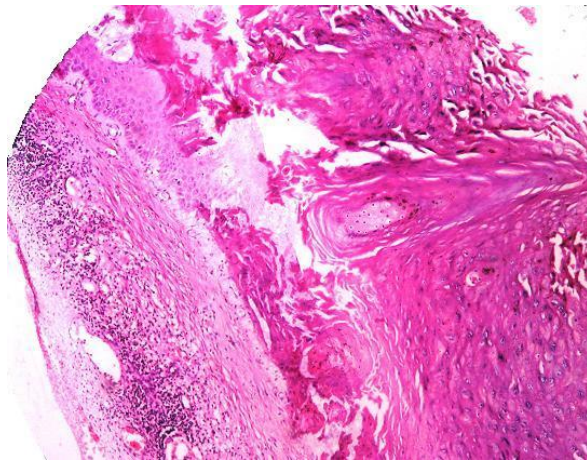
A 52 year old female patient presented with complains of burning micturition, nausea, vomiting and fever for 15 days at tertiary care hospital, Rajkot. Patient has left pleural effusion, exudative in nature without malignant cells. ECG shows sinus tachycardia with inverted T wave. However 2D Echocardiography study has been normal with no history of urinary tract stones and trauma. Laboratory values revealed elevated White blood cell count (19,200/cumm) with 87% of neutrophils and elevated serum creatinine (1.92mg/dL). In this case ultrasonography examination reveals hydronephrotic changes with absence of obstruction, stone and fibrosis. Pelvi-ureteric junction was normal. Ureter does not show any remarkable changes. Intravenous pyelogram shows hydronephrosis with nonfunctioning of left kidney, so nephrectomy was done as suspicious of stag horn stone. Gross examination of nephrectomy specimen revealed that the kidney was enlarged, distorted and measured 9.5 x 7.0 x 5.0 cm, with perinephric fat and capsule adherent on surface. On cut section of nephrectomy specimen showed most of the renal parenchyma replaced by multiloculated cystic area. At places cystic cavity contain firm cheesy like whitish, friable material and absence of grossly identified stones (figure1).



**Figure 1: Outer surface with cystic cavity with absence of grossly identified stones**



**Figure 2 (A,B): The cyst are lined by keratinizing stratified squamous epithelium and filled with laminated keratin. The adjacent renal parenchyma shows few glomeruli that were mostly sclerosed and hyalinised together with atrophy of the tubules and filled with colloid like cast.**



**Figure 3: The cyst are lined by keratinizing stratified squamous epithelium and filled with laminated keratin. (H&E, x 100)**

Microscopic examination shows the renal parenchyma was compressed by these multilocular cysts that were lined by keratinized stratified squamous epithelium with granular cell layer and filled with laminated layers of keratin (figure 2, 3). No evidence of skin appendages either pilosebaceous units or eccrine sweat glands were noticed. The surrounding renal parenchyma showed signs of atrophy in the form of decreased number of glomeruli that appeared mostly sclerosed and hyalinised. The atrophy of the tubules that appears small in size and filled with colloid like mass. The stroma shows fibrosis and thick walled blood vessels.

diagnosed as hydronephrosis by ultrasonography examination. The definitive diagnosis was reached by the microscopic examination which reveals cystic area lined by stratified squamous epithelium with granular layer and filled with laminated keratin. There is no evidence of skin adnexa. Sections from remaining tissue show glomeruli in various stages of atrophy and replacement by hyalinization. Periglomerular thickening is marked. The tubules are also atrophy and contain colloid cast. The stroma show mild area of fibrosis and chronic inflammatory exudates. The blood vessels show thickened wall with evidence of hyalinization of wall.

The presence of stratified squamous epithelium in renal lesions is considered as a rare condition which may have different causes. For example, extension of squamous metaplastic changes from the upper ureter to the pelvi-calyceal system in prolonged obstructive conditions induced mostly by stones is considered as one of the commonest source of squamous epithelium in the kidney<sup>[7]</sup>. Squamous epithelium could also be a part of other renal lesions such as teratoid variant of wilm's tumor<sup>[8]</sup>, teratoma<sup>[9]</sup> and dermoid cyst.<sup>[10]</sup>

Teratoid variant of wilm's tumor is an embryonic tumor. Radiological examination shows mass in abdomen on either side. Grossly most wilm's tumor are solitary, well circumscribed, rounded, and of soft consistency. The cut section is predominantly solid and pale gray or tan and often exhibits areas of cystic

**Table 1: Intrarenal epidermoid cyst presented as an enlarged multicystic kidney**

Authors	Year	Age (Years)	Sex	Symptoms	Presentation
<b>Present case</b>	2012	52	Female	Burning micturition, nausea, vomiting & fever	Hydronephrosis of kidney.
<b>Abdou<sup>1</sup></b>	2010	67	Male	Left loin pain	Multiple and multilocular cystic lesion of the left kidney
<b>Lim and Kim<sup>2</sup></b>	2003	51	Male	Left loin pain and hematuria	Single cystic renal mass in the lower pole of the left kidney
<b>Allen<sup>3</sup></b>	1994	74	Female	Right loin pain	Single right renal mass.
<b>Duprat et al<sup>4</sup></b>	1986	4	Male	Urinary frequency	Calcified intrarenal mass.
<b>Krogdahl<sup>5</sup></b>	1979	67	Male	Renal colic	Renal cyst interpreted as an old tuberculous focus

## Discussion

In this patient, the left kidney multiloculated cyst has replaced renal parenchyma by compressing it that was

change, necrosis, and hemorrhage. Microscopically tumor typically composed of triphasic combination of blastemal, stromal and epithelial cell types. The tightly packed blue cells are the blastemal elements,

immature tubule is the epithelial element and spindle cells are stromal elements. The heterologous elements are predominant, comprising more than 50 % of the tumor mass and composed of squamous epithelium with abundant keratin pearl formation. Teratoma present mainly as an abdominal mass with few other symptoms. Teratoma is neoplasm that arises from pluripotent cell and can differentiate along one or more embryonic germ lines. Renal teratoma is exceedingly rare condition. Majority of the tumor are benign, situated on the left side & pararenal, occasional lesions are bilateral. USG finding shows renal mass with cystic & solid changes. Microscopically cystic spaces lined by keratinizing squamous epithelium with skin adnexa.

In this case study, the absence of renal calculi and metaplastic changes in the pelvi-ureteric junction could differentiate this case from squamous metaplasia of the pelvi-calyceal system due to the obstructive and irritative effects of stones.

Different theories had been suggested for the presence of epidermoid cyst in extraordinary sites such as internal organs including kidney, spleen, brain and testis. If the implantation, sequestration or inclusion could be suitable explanations for epidermoid cyst arising in hairy and in non hairy areas, it would not be acceptable in internal organs except after exclusion of trauma. The Wolffian duct (mesonephric duct) is one of the paired embryonic tubules that drain the primitive kidney (mesonephron) to the cloaca. In this case, it is suggested that epidermoid cyst could originate from the embryonic remnant of Wolffian ducts and this hypothesis is considered as the most convenient one.<sup>[4]</sup>

In this rare case nephrectomy was done as a suspicious of stag horn calculi with hydronephrotic changes and non-functioning kidney. Epidermoid cyst can cause damage to renal parenchyma, so early diagnosis can preserve the normal kidney area and subsequently prevent radical surgery.

## Conclusion

In conclusion, epidermoid cyst of the kidney is a rare condition causing severe kidney damage leading to an end stage kidney disease. Epidermoid cyst of the kidney could be multiple producing a picture similar to hydronephrosis. Awareness of the occurrence of this cyst would broaden the differential diagnosis in un-

ilateral cystic disease of the kidney. Timely diagnosis is essential to prevent radical surgery.

## Acknowledgements

We are very much thankful to Dr. Pankaj Dholaria, B. T. Savani kidney hospital, Rajkot for providing us detail clinical history and follow up of patient.

## Funding

None.

## Competing Interests

None declared.

## References

1. Krogdahl AS. Epidermoid cyst in the kidney. *Scand J Urol Nephrol* 1979;13:131-2.
2. Duprat G, Filiatrault D, Michaud J. Intrarenal epidermoid cyst. *Pediatric Radiol* 1986; 16: 73-5
3. Emtage LA, Allen C. A renal epidermoid cyst. *Br J Urol* 1994; 74:125-6.
4. Lim SC, Kim CS. Intrarenal epidermal cyst. *Pathol Int* 2003; 53:574-8.
5. Boeminghaus F, Huth F. Epidermoid cyst of the kidney pelvis wall (Clinical, histopathological and cytological findings). *Z Urol Nephrol* 1971; 64:829-34
6. Gokce G, Kaya K, Kilicarslan H, Tas F, Ayan S, Yildiz E, et al. Epidermoid cyst in the renal pelvis. *Int Urol Nephrol* 2003;35: 9-10.
7. Ishizaki H, Iida S, Koga H, Shimamatsu K, Matsuoka K. Epidermoid cyst of the ureter: A case report. *Int J Urol* 2007; 14:443-4.
8. Boswell PD, Fugitt B, Kane CJ. Keratinizing desquamative squamous metaplasia of the kidney mimicking transitional cell carcinoma. *Urology* 1998;52:512-3.
9. Karabult A, Emr L, Gonulta M, Incel N, Germiyanoğlu C, Eroll D. Squamous cell carcinoma located in the renal calyceal system: A case report and review of the literature. *Turk J Cancer* 2002; 32:20-4.
10. Inoue M, Uchida K, Kohei O, et al. Teratoid Wilms' tumor: a case report with literature review. *J Pediatr Surg* 2006; 41:1759-63.
11. Mochizuki K, Ohno Y, Tokai Y, et al. Congenital intrarenal teratoma arising from a horseshoe kidney. *J Pediatr Surg* 2006; 41: 1313-5.