



Case Report

Extra-oral verruciform xanthoma: an uncommon entity

Akanksha Jain*, Shilpi Agarwal, Manupriya Nain, Deeksha Singh

Department of Pathology, Lady Hardinge Medical College, Delhi, India

Keywords: *Verruciform Xanthoma, Papilloma, Foamy Macrophages, Papillary Dermis*

Abstract

Verruciform xanthoma (VX) is an uncommon benign condition, which frequently affects the oral mucosa in adults. Only few cases of VX of anogenital region and skin have been reported. Clinically, it presents as a white or yellowish-white sessile or pedunculated, papillary or verrucous mucosal growth and is usually less than 2 cm in size. Although it is considered a benign entity, it has clinical importance as it needs to be differentiated with wart like growths i.e. verrucous carcinoma, condyloma acuminatum, seborrheic keratosis and due to its strong association with more serious diseases like epidermolysis bullosa, epithelial dysplasia, pemphigus vulgaris, solar keratosis and discoid lupus erythematosus. The etiology of this lesion is unknown, however is thought to be reactive rather than a neoplastic process secondary to epithelial damage induced by different associated conditions. We present two cases of VX and discuss their clinical and histopathological findings and possible correlation with a postulated etiopathogenesis.

***Corresponding author:**

Dr. Akanksha Jain, R-Z, L/11 First Floor Mahaveer Enclave-1, New Delhi-110045, INDIA
Email: doctorakanksha@gmail.com; Phone: +91-9873075148

Date of Submission: June 29, 2014

Date of Acceptance: Aug 16, 2014

Date of Publishing: Jan 28, 2015



This work is licensed under the Creative Commons Attribution International License

Introduction

Verruciform xanthoma is a rare nonneoplastic entity which primarily affects oral mucosa with an incidence of 0.025–0.095% of all cases.^[1] Involvement of anogenital region and skin is very rare. This unique lesion occurs in middle-aged and older individuals, usually in fifth to eight decade. Due to its papilloma like appearance, VX needs to be differentiated from verruca vulgaris, condyloma accuminatum, verrucous carcinoma, and, sometimes, squamous cell carcinoma. Histopathological examination, demonstrates verrucous hyperplasia of the epidermis with a variable number of xanthoma cells limited to papillary dermis as the hallmark of VX.^[2] We report two cases of extraoral VX wherein, first case presented with verrucous large lesion on skin of back, which is an uncommon site for VX, while second case presented with right labia minora swelling in a 12 year old female which is an uncommon age for VX.

Case Reports

CASE 1: A 58 year-old man presented with a well-demarcated, elevated, greyish-pink, papillomatous plaque measuring 3x3cm over the back since 5 years. A presumptive clinical diagnosis of Verrucous carcinoma was made. Patient also had past history of multiple well defined discrete itchy lesions over pinnae of ears and scalp suggestive of DLE since 8 years. He was on immunosuppressant treatment for DLE.

CASE 2: A 12 year-old female presented a painless, well-circumscribed, verrucous plaque of 1.5x1cm in diameter on right labia minora since 1 year. The lesion was clinically diagnosed as a verrucous vulgaris. There was no regional lymphadenopathy and the remainder of the physical examination was unremarkable. Routine biochemical parameters including serum lipid profile were unremarkable in both the cases.

The histological examination of the lesions of both cases revealed a well circumscribed regularly acanthotic, verrucous epithelial lesion with papillary projections lined by focally parakeratotic stratified squamous epithelium. There was no cytological atypia suggesting a pseudo epitheliomatous hyperplasia like morphology (Figure 1). The dermal papillae showed a variably rich infiltrate of mononucleated cells with large amount of pale foamy cytoplasm (Figure 2). These cells were immunoreactive for CD 68 (figure 3). Touton giant cells were not identified. A Diagnosis of

VX was made on these findings. Both cases were negative for HPV antigen. Both the cases were treated with wide local excision.

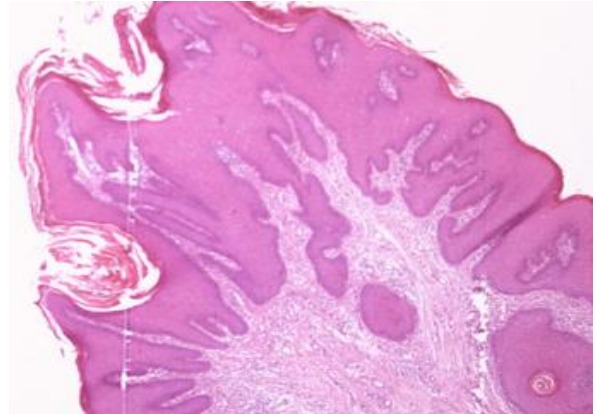


Figure 1: A well circumscribed regularly acanthotic verrucous epithelial lesion showed papillary projections lined by focally parakeratinized stratified squamous epithelium. (H&E, 100x)

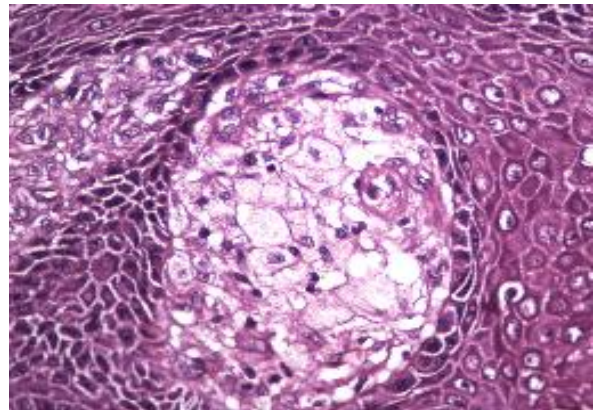


Figure 2: The dermal papillae contain a variably rich infiltrate of mononucleated cells with large amount of pale foamy cytoplasm, hallmark of VX (H&E, 400x)

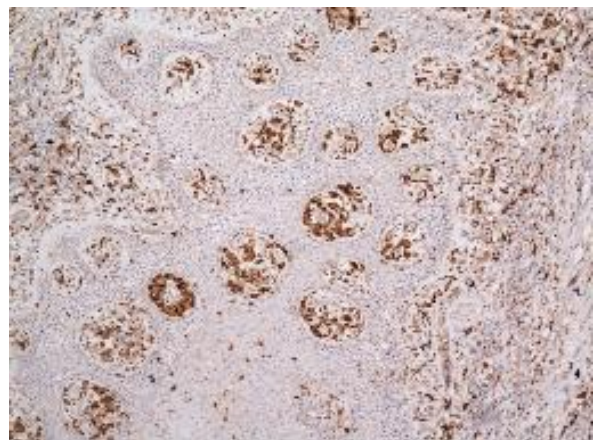


Figure 3: These foamy cells were immunoreactive for CD 68. (100x)

Discussion

The verruciform xanthoma is a rare benign verrucous lesion of unknown etiology. It was first reported as oral lesion with only rare cases reported on the skin and vulval mucosa, although it remains a predominantly oral lesion. Clinically, VX is usually described as an asymptomatic solitary verrucous, papillomatous papule or plaque with a color varying from reddish pink to gray and a diameter ranging from 0.2 cm to 2 cm^[3]. It may mimic a viral wart, condyloma accuminatum, verrucous carcinoma or less frequently, squamous cell carcinoma. It is crucial to rule out squamous cell carcinoma because of its therapeutic implications. To our knowledge, only rare cases of cutaneous VX have been reported so far.

Histopathologically, VX is characterized by hyperkeratosis, columnar invaginated parakeratosis, verrucous acanthosis, and elongation of rete ridges with presence of abundant lipid-laden histiocyte-like cells in papillary dermis which is pathognomonic of this lesion. These cells contain lipid as well as Periodic acid Schiff positive, diastase-resistant granules. Morphologically, these cells are similar to xanthoma cells, however, no association with any metabolic disease has been reported till date. A viral etiology has been speculated since extra-oral lesions are usually reported in genitalia. But numerous studies done in the past have failed to detect HPV in VX lesions. Some authors have suggested that the lesion may represent an unusual reaction to localized epithelial trauma.^[4] This theory is supported by cases of verruciform xanthoma that have developed in association with disturbed epithelium like epidermolysis bullosa, epithelial dysplasia, pemphigus vulgaris, carcinoma in situ, lichen sclerosis, solar keratosis, discoid lupus erythematosus, epithelial nevus or epidermal nevus syndrome and lichen planus. Therefore, it has been speculated that VX may be a unique reaction pattern to an initiating event that leads to selective recruitment and persistent accumulation of foamy macrophages in the dermal papillae. In recent years there has been an increase in the number of reports of VX in the context of immunosuppression^[5,6]. Thus, the impaired immune response may also have a role in the pathogenesis of these lesions. One of our patients had DLE for eight years for which he was on immunosuppressant therapy favoring above hypothesis. Both our cases reported here are unique in either site or age of presentation. The first case was misdiagnosed on incisional biopsy as pseudoepitheliomatous hyper-

plasia by two different pathologists. However due to strong clinical suspicion of malignancy, a wide local excision was performed, and on histopathological examination of the same, a diagnosis of VX was made. The second case was challenging as vulva is rare site for presentation of VX, and adolescence is an uncommon age group.

Conclusion

The take home message from both these cases is that one should be aware of this entity as it has varied clinical course. It poses a diagnostic and therapeutic challenge as it needs to be differentiated from other wart like entities including squamous cell carcinoma. Although no potential for malignancy for this lesion has been reported in the literature to date, VX is generally associated with other serious diseases. Therefore emphasis needs to be laid on searching for associated comorbidities. Also, correct categorization of this lesion is required as it is non-responsive to usual antiviral (imiquimod, podophyllin) treatment and excision is only effective and curative treatment.

Acknowledgements

We are thankful to Dr Anu Beniwal for her kind support.

Funding

None.

Competing Interests

None declared.

References

1. Buchner A, Hansen LS, Merrell PW. Verruciform xanthoma of the oral mucosa: report of five cases and review of the literature. *Archives of Dermatology*. 1981;117:563-5.
2. Mohsin SK, Lee MW, Amin MB, et al. Cutaneous verruciform xanthoma: a report of five cases investigating the etiology and nature of xanthomatous cells. *The American Journal of Surgical Pathology*. 1998; 22:479-87.
3. Shafer WG. Verruciform xanthoma. *Oral Surg*. 1971;31:784-9
4. Zegarelli DJ, Zegarelli-Schmidt EG, Zegarelli EV. Verruciform xanthoma: further light and electron microscopic studies, with the addition of a third case. *Oral Surg*. 1975; 40: 246-56.
5. Kanitakis J, Euvrard S, Butnaru AC, Claudy A. Verruciform xanthoma of the scrotum in a renal transplant patient. *British Journal of Dermatology* 2004; 150:155-77.
6. Sibaud V, Marit G, Deminiere C, et al. Multiple verruciform xanthomas of the oral mucosa associated with graft versus host disease. *Ann Dermatol Venereol*. 2006; 133:995-9.