

Carcinomatosis Peritonei of Prostatic Adenocarcinoma: Incidental Finding in a Case of Obstructed Umbilical Hernia

Rupesh Prakashrao Gundawar*, Umesh Sidheshwar Kanade, Shubhada Yadavrao Bansode, Rahul Suryakantrao Abhange, Shivaji Dadarao Birare

Dept. of Pathology, Government medical college and hospital, Latur, India

Keywords: *Carcinomatosis Peritonei, Umbilical Hernia, Prostatic Adenocarcinoma, Crystalloids,*

ABSTRACT

Peritoneal metastasis arising from prostate cancer is a very rare phenomenon. We present a rare case of a patient presenting with carcinomatosis peritonei from a prostate primary. This case report is important in that it is generally not widely recognized that prostate cancer metastasizes to the peritoneum. In the literature, peritoneal metastasis from prostate cancer, if present, are usually associated with other sites of metastases and found at very advanced stages of the disease. In our patient carcinomatosis peritonei was the first presentation which led to the diagnosis of prostate cancer and was the only site of metastasis.

***Corresponding author:**

Dr Rupesh Prakashrao Gundawar, Dept. of Pathology, 3rd floor, College building, Govt. Medical College, Latur, Maharashtra, India
Phone: +91 9503376899
E-mail: rupeshgundawar@gmail.com,



Introduction

Prostate cancer is the second cause of cancer related deaths in men.^{1,2} Haematogenous metastases are present in 35% of patients with prostate cancer, with most frequent involvement sites being bone (90%), lung (46%), liver (25%), pleura (21%), and adrenals (13%).^{3,4} The peritoneum is an extremely rare metastatic site for prostatic adenocarcinoma, with only a few cases published to date. We present a rare case of an otherwise asymptomatic patient who presented with obstructed umbilical hernia.

Case Report

An 80 year old male presented with an umbilical hernia of 5-6 months which became irreducible since 15 days associated with intermittent vomiting. No obvious urinary complaints were noted. Ultrasonography of abdomen and pelvis reported an abdominal wall defect at umbilicus containing mesentery with few subcentimetric sized lymph nodes. Ultrasonography of scrotum was unremarkable. Routine laboratory investigations were within normal limits. Patient was posted for hernia repair. Prostate was not examined during pelvic USG as patient was primarily managed for obstructed umbilical hernia

To the histopathology section, we received peritoneal tissue measuring 7×4.8×0.3cm. It was studded with multiple (total 27) variable sized greyish nodules ranging from 0.2cm to 1.8cm diameter (Fig.1). Nodules were processed for histopathological studies.

Microscopically, nodules were composed of tumour arranged in glands and acini arranged mainly in cribriform, tubulocystic and solid pattern (Fig.2). Glands were particularly perpendicular to each other. Glands were smaller with straight luminal borders (Fig.3-A). Cells lining the glands showed stratification with moderate nuclear pleomorphism, vesicular chromatin, prominent nucleoli and amphophilic cytoplasm (Fig.3-inset). Intra-luminal PAS positive dense, pink, acellular secretion (Fig.4-A) and blue tinged mucin were appreciated. Few glands showed presence of eosinophilic crystalloids (Fig.4-B).

With above mentioned characteristic histomorphology, we primarily thought of prostatic metastasis with old age being the only suggestive finding. Since the patient was lost in the follow up and available clinical details were inadequate, large immunohistochemistry (IHC) panel was put. Tumour was immunopositive for, PSA (prostate specific antigen) (Fig.4-A), AMACR (α -Methylacyl-Coenzyme-A racemose) (Fig.4-B) and pan-cytokeratin (AE1/AE3) (Fig.4-C). Tumor was immunonegative for CK7, CK20, CDX-2, chromogranin, synaptophysin, CD10, CEA and PAX-8. With above IHC panel, case was

diagnosed as peritoneal carcinomatosis (or carcinomatosis peritonei) due to prostatic adenocarcinoma.

Discussion

Prostatic adenocarcinoma are known for their metastatic notoriety with metastatic manifestations arising before symptoms due to primary cancer. Involvement of the prostatic capsule, bladder base, and seminal vesicles can occur via direct extension. Prostatic cancer is metastatic in 35% of cases, with a marked predilection for bony spread. Growth factors immobilized on bony matrix and adhesive molecules expressed in marrow stromal cells as well as production of PSA and urokinase-type plasminogen activator (u-PA) are some of the factors implicated for preferential homing of prostate cancer cells to the bones in 90% of metastatic cases.⁵ Other less common sites are lung, liver, pleura and adrenals.

Autopsy reports have suggested that prostate cancer metastasizes to the peritoneum in about 7% of the general population.³ Peritoneal metastasis is generally found in late stages of disease with either primary tumour is diagnosed or metastasis at other commoner sites have been found. Our case is unique in its own way that the peritoneal metastasis is the only manifestation with undiagnosed primary tumour. Till date, very few cases of prostate adenocarcinoma metastatic to the peritoneum, have been reported.^{6,7,8,9} In each case, the diagnosis of prostate adenocarcinoma in the prostate gland had been documented before discovery of the ascites or peritoneal metastasis. Our case stands a special note with peritoneal metastasis found incidentally before primary tumour as the only metastatic manifestation.

Conclusion

With this article, we present an additional case of an unusual manifestation of prostate cancer presented with

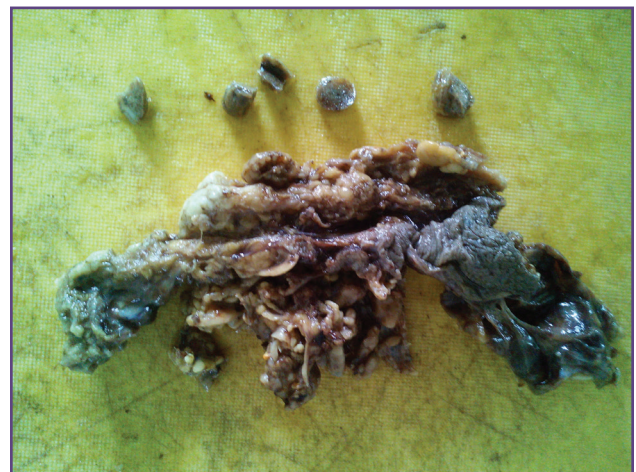

Fig. 1: Omental pad of fat is studded with varying sized multiple grey white nodules

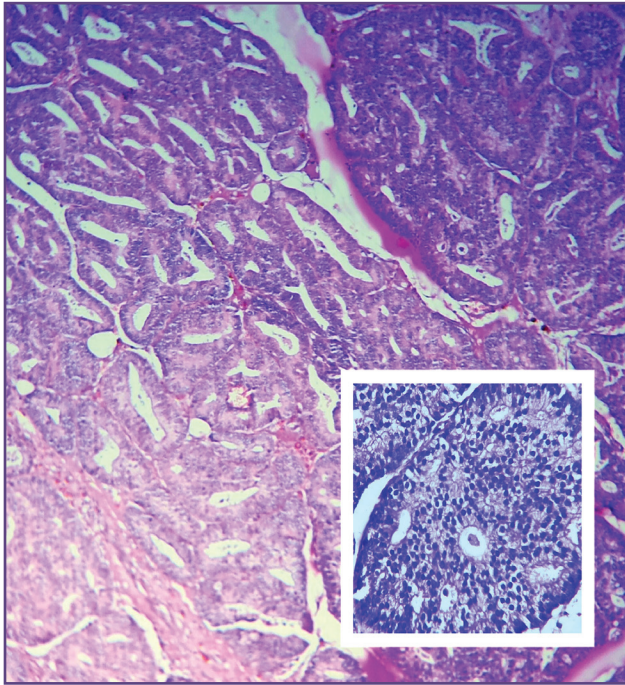


Fig. 1 Predominantly tubulocystic pattern with fused glands forming cribriform pattern (inset) (H&E, 40X).

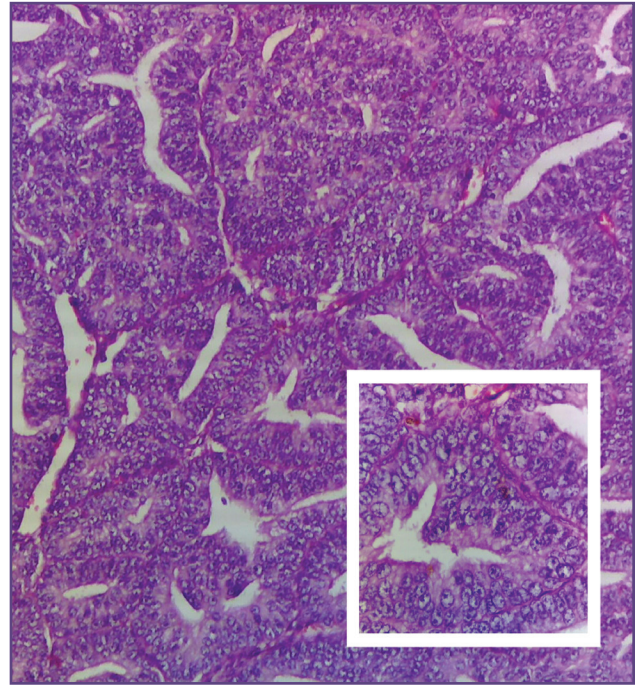


Fig. 2 Glands are showing straight luminal borders. Tumour cells showing stratification with vesicular chromatin and prominent nucleoli (inset) (H&E, 100X).

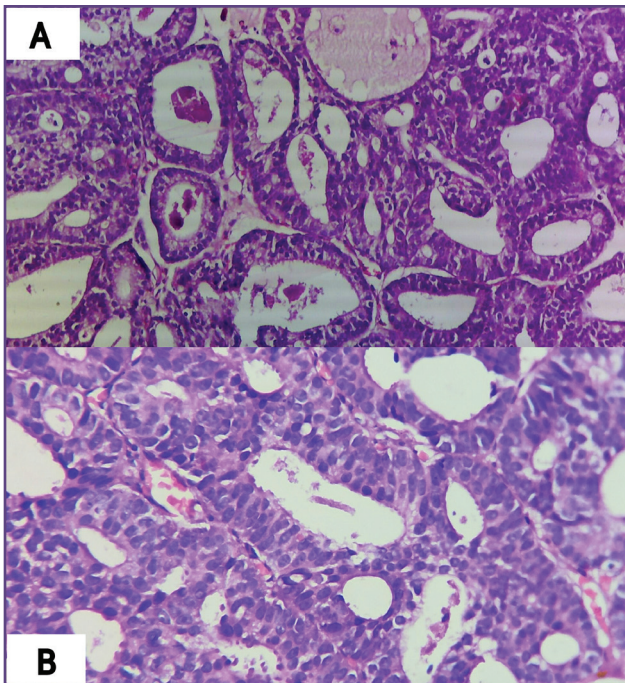


Fig. 3 Dense eosinophilic intraluminal secretion (A) and intraluminal crystalloids (B) (H&E, 100X).

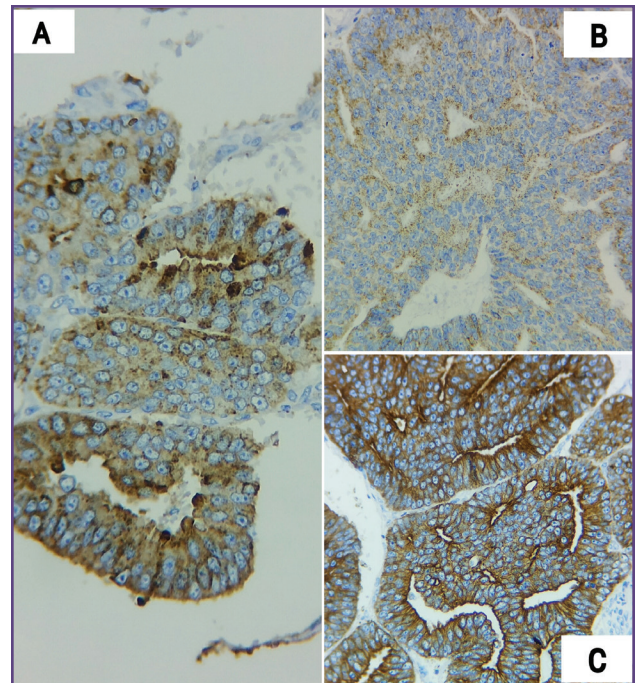


Fig. 4 Tumor is positive for PSA (A), AMACR (B) and Pan CK (C) (100X).

peritoneal metastases. Thus, surgeons and histopathologist should draw their attention to this rare clinical presentation of metastatic prostatic cancer in all aged patients.

Acknowledgements

The authors appreciate Dr Shruthi Deshkulkarni and Dr Sankalp Deshmukh for assisting in literature collection and snapping the excellent pictures of the case.

Funding

None

Competing Interests

None declared

References

1. Turkbey B., Basaran C., Boge M., Karcaaltincaba M., Akata D.: Unusual presentation of prostate cancer with generalized lymphadenopathy and unilateral leg edema. *JBR-BTR*, 2008,91: 211-213.
2. De Visschere P, Oosterlinck W, De Meerleer G, Villeirs G.: Clinical and imaging tools in the early diagnosis of prostate cancer. *JBR-BTR*, 2010,93: 62-70.
3. Bubendorf L, Schoepfer A, Wagner U, Sauter G, Moch H, Willi N, et al. Metastatic patterns of prostate cancer: an autopsy study of 1,589 patients. *Hum Pathol* 2000;31(5):578–83.
4. Conti G, La Torre G, Cicalese V, Michaletti G, Ludovico MG, Cottonaro G, et al. Prostate cancer metastases to bone: observational study for the evaluation of clinical presentation, course and treatment patterns. Presentation of the METAURO protocol and of patient baseline features. *Arch Ital Urol Andro* 2008;80(2):59–64.
5. Roodman GD. Mechanisms of bone metastasis. *N Engl J Med* 2004;350:1655–64.
6. Saif MW, Figg WD, Hewitt S, Dahut W. Malignant ascites as only manifestation of metastatic prostate cancer. *Prostate Cancer Dis* 1999;2:290–3.
7. Kehinde EO, Abdeen SM, Al-Hunayan A, Ali Y. Prostate cancer metastatic to the omentum. *Scand J Urol Nephrol* 2002;36(3):225–7.
8. Zagouri F, Papaefthimiou M, Chalazonitis AN, Antoniou N, Dimopoulos MA, Bamias A. Prostate cancer with metastasis to the omentum and massive ascites; a rare manifestation of a common disease. *Onkologie* 2009; 32:758–61.
9. Brehmer B, Makris A, Wellmann A, Jakse G. Solitary peritoneal carcinomatosis in prostate cancer (German). *Aktuelle Urol* 2007; 38:408–9.