

Fine Needle Aspiration as a Diagnostic Tool for Metastasis to Thyroid: A Dilemma

Prashant Vijay Kumavat*, Anita Padmanabhan , Manisha S Khare,
Chetan S Chaudhari, Nitin M Gadgil

Dept. of Pathology, LTMMC and LTMGH Sion, Mumbai, India

Keywords: *Fine-Needle Aspiration, Immunohistochemistry, Lobular Breast Carcinoma, Thyroid Metastasis.*

ABSTRACT

Metastasis to the thyroid gland is very rare. It is very important to differentiate metastasis to thyroid from primary thyroid malignancy from the treatment point of view. A 48-years-old lady presented with weakness of lower limbs and backache since one and half months. External examinations reveal diffuse, nodular goitre. A fine-needle aspiration (FNA) of the thyroid nodule showed malignant epithelial cells with features characteristic of invasive lobular breast carcinoma. The diagnosis offered on FNAC was metastatic lobular breast carcinoma which was later confirmed on histopathological finding at autopsy. IHC performed on thyroid nodule was positive for: CK7, AE1-AE3, ER and negative for: E-cadherin, confirming its lobular nature. TTF1 was negative. FNA could be useful for diagnosis of thyroid metastasis, but it should be confirmed by immunohistochemistry.

***Corresponding author:**

Dr. Prashant Vijay Kumavat, Room no 1303, floor no 13, building no. 27, Hawre City, Kasarvadavali, Ghodbander Road, Thane (W). India
E-mail: drkumavat_83@rediffmail.com



Introduction

Metastasis to thyroid is usually identified at autopsy. Metastasis to thyroid gland is quite rare and there are only sporadic clinical cases reported in the literature. The common metastases to thyroid arise from carcinoma of breast, liver, lungs, brain, and bone.^[1] There is recent increase in the rate of diagnosing metastatic tumor in thyroid due to radiologically guided fine needle aspiration (FNA) of the thyroid gland. We report a case of metastasis to thyroid from lobular breast carcinoma which was picked up on FNA cytology and confirmed by histopathology findings at autopsy and immunohistochemistry.

Case Report

A 48-year-old female patient presented with weakness of lower limbs and backache since one month. On examination she was cachexic and had a nodular, firm thyroid swelling involving both lobes, right lobe measuring 3x3 cm and left lobe measures 2.5x2 cm. FNAC from thyroid showed few benign thyroid follicular epithelial cells and scattered in between were small clusters of cells with hyperchromatic nuclei with occasional prominent nucleoli and moderate amount of cytoplasm, which was vacuolated at places (Figure 1a). Diagnosis of suspicious for metastasis to thyroid was made and patient was advised further clinical workup. X ray Spine showed osteoporotic fracture of L2-L3 lumbar vertebral, suggestive of metastasis. Sonomammography of Right Breast revealed a large ill-defined, hypoechoic lesion measuring 3.8x 3.5x 3.2 cm in the retroalveolar region, suggestive of neoplastic etiology. The Patient was then referred back for FNAC of right breast. FNAC of breast showed scattered and occasional small loose cluster of ductal epithelial cells with hyperchromatic nuclei with occasional prominent nucleoli and moderate amount of cytoplasm which was vacuolated

at some places giving classic signet ring cell appearance (Figure 1b). Many of the cells showed cytoplasmic vacuolization, diagnosis offered on FNAC of thyroid and breast was infiltrating Lobular carcinoma of breast with metastasis to thyroid.

One week later patient developed breathlessness and expired. At autopsy -Thyroid was enlarged and encapsulated. Right lobe measures 6x5x3 cm, left lobe measures 6.5x4x3 cm and isthmus measures 5x3x2 cm. Many enlarged lymph nodes were present. Cut section show multiple nodules with focal areas of haemorrhage (Figure 2).

Histopathology of the breast mass revealed small to medium sized non cohesive cells arranged in linear pattern in between collagenous stroma, showing a Indian file pattern (Figure 3a). At many places malignant cells encircling breast ducts giving classic targetoid pattern (Figure 3b). Histopathological findings of thyroid showed similar type of cells as seen in breast which were small to medium sized cells, scattered in between thyroid follicular epithelial cells (Figure 3c). Cells showed moderate amount of cytoplasm, hyperchromatic nuclei. Focally cytoplasm showed vacuolization pushing the nucleus to periphery, giving signet ring cell appearance (Figure 3c). Some of the cells were Alcian blue- PAS positive (Figure 3d). To confirm the diagnosis, immunohistochemistry on the thyroid mass was performed. CK 7 and AE 1- AE3 was strongly positive which confirmed malignancy of epithelial origin. TTF 1 which was negative ruled out a primary carcinoma of thyroid. IHC for ER, PR and HER 2 neu was performed, of which, ER was weakly positive. PR and HER 2 were negative (Figure 4). E cadherin was negative, thus confirming the histopathological diagnosis of metastasis of lobular carcinoma of breast to Thyroid. Histopathology of the other organs did not reveal any significant pathology.

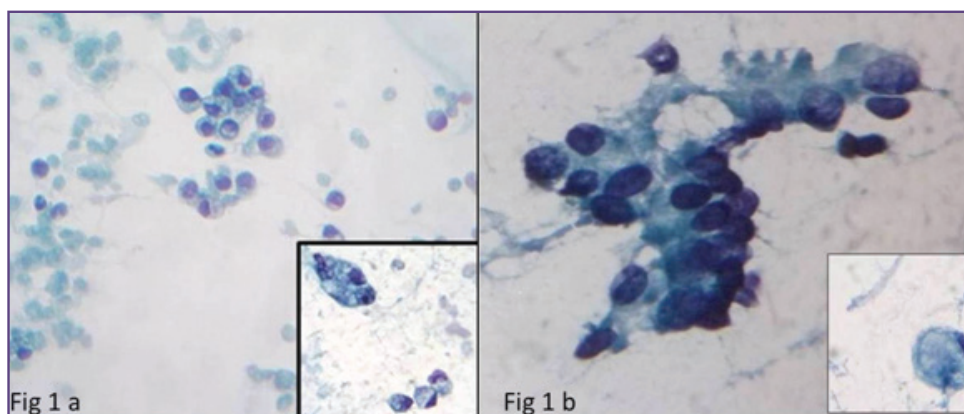


Fig. 1: (a) FNAC of thyroid show scattered malignant cell. Inset, Malignant cells with intracytoplasmic vacuolization (Pap stain 40X). (b) FNAC of Breast show scattered malignant breast cells, Inset- Signet ring cells (Pap stain 40X).

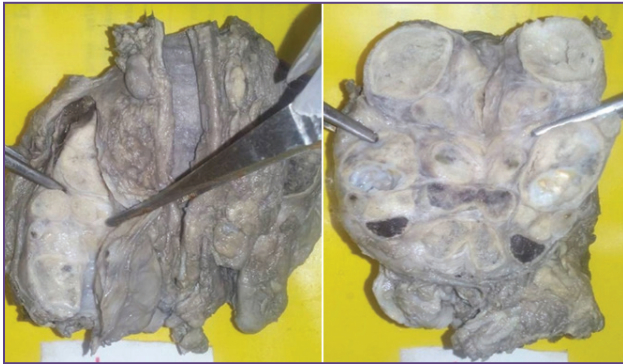

Fig. 2: Gross specimen of thyroid showing metastatic lesion.

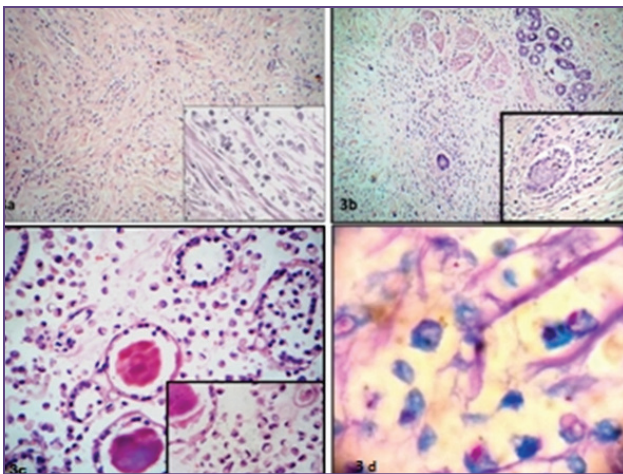


Fig. 3: (a) Primary tumor in the breast showing infiltrating lobular carcinoma (H&E, 10x), Inset - Indian file pattern (H&E, 40x). (b) Targeted pattern (10x), Inset (40x). (c) Metastatic cell in between thyroid follicles, Inset- Signet ring cell (40x). (3) - Alcian blue - PAS positive cells (40x)

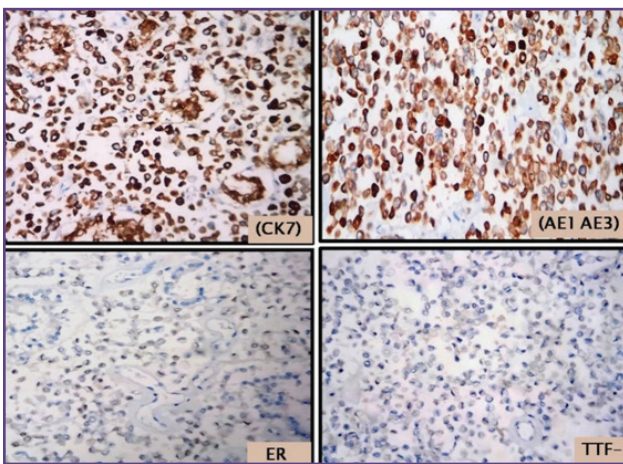


Fig. 4: Metastasis to thyroid from breast IHC strong positive staining for CK 7 and AE1 AE3, 2% weak positive ER and negative TTF -1 (40 x).

Discussion

The thyroid gland is highly vascularized; however, metastasis of malignant tumours to the thyroid are relatively rare. The exact mechanism for decrease incidence of metastasis to the thyroid is unknown, but it is thought to be associated with immunological mechanisms. [2] The incidence of metastasis to the thyroid gland in autopsy series varies from 0.5 to 24.2%, [3, 4] the variation of which is likely due to the precision of investigation during the autopsy. In autopsy studies metastasis to thyroid gland is more common than primary thyroid malignancy. [5] In most autopsy series metastasis to thyroid were from breast and lung cancers, however in clinical studies renal cell carcinoma is the most common metastasis to thyroid. [5] In a clinical setting, metastasis of the thyroid gland is detected at a low frequency, and is commonly detected at the same time as the diagnosis of the primary site or shortly thereafter. Diagnosis of thyroid metastasis is difficult, and in general, most cases are asymptomatic and identified due to the appearance of solitary or multiple masses. [3]

Liver and lung metastases are common in invasive ductal carcinoma, whereas gastrointestinal tract, peritoneum, and retroperitoneum metastases are common in invasive lobular carcinoma. [6] Thyroid metastasis is generally a part of advanced and disseminated disease and associated with poor prognosis. [4] Our patient had lumbar spine metastasis at the time of presentation.

FNAC is a useful tool to detect thyroid metastasis in clinically suspected cases. [7] FNAC is preferred as it is safe, inexpensive and simple procedure. [5] In most cases, the cytological features of the metastatic deposit are similar to those of the primary neoplasm, allowing a precise recognition. The patient described underwent FNAC of thyroid and breast, which suggested metastatic thyroid lesion from the breast cancer.

Breast metastatic carcinoma to the thyroid is uncommon phenomena in cytology practice and may give a diagnostic dilemma, particularly in case of occult primary carcinoma in the presence of some morphologic similarities with primary thyroid lesions. So histopathology results should be confirmed by IHC examinations. IHC analysis on thyroid revealed strong reactivity for CK7, AE1-AE3. ER was weakly positive. PR and HER 2 were negative. To distinguish breast metastatic lesions from primary thyroid malignancies TTF1 is a ideal marker which was negative. E cadherin marker to distinguish ductal and lobular was negative. So diagnosis of infiltrating lobular carcinoma metastasing to thyroid was confirmed.

Estrogen receptor-positive cases tend to metastasize primarily to the thyroid and parathyroid glands, while progesterone receptor-positive cases tend to metastasize to the myocardium or the epithelium of the gastrointestinal and urinary tracts.^[8]

Conclusion

We conclude that although the thyroid gland is an uncommon site of metastasis, both clinicians and pathologist should be aware of the possibility of metastatic disease in patients with history of malignancy. A patient's complete clinical history is extremely useful, and FNAC as a diagnostic tool in such difficult cases with help of immunohistochemistry to confirm the diagnosis of metastatic malignancy is warranted.

Funding

None

Competing Interests

None declared

Reference

1. Rosen IB, Walfish PG, Bain J, Bedard YC: Secondary malignancy of the thyroid gland and its management. *Ann Surg Oncol* 1995;2:252–256.
2. Czech JM, Lichtor TR, Carney JA, van Heerden JA: Neoplasms metastatic to the thyroid gland. *Surg Gynecol Obstet* 1982;155:503–505.
3. Lam KY, Lo CY: Metastatic tumors of the thyroid gland: A study of 79 cases in Chinese patients. *Arch Pathol Lab Med* 1998;122:37–41.
4. Nakhjavani MK, Gharib H, Goellner JR, van Heerden JA: Metastasis to the thyroid gland. A report of 43 cases. *Cancer* 1997;79:574–578.
5. Gerges AS, Shehata SR, Gouda IA. Metastasis to the thyroid gland: unusual site of metastasis. *J Egypt Natl Canc Inst* 2006; 18: 67–72.
6. Harris M, Howell A, Chrissohou M, Swindell RI, Hudson M, Sellwood RA: A comparison of the metastatic pattern of infiltrating lobular carcinoma and infiltrating duct carcinoma of the breast. *Br J Cancer*. 1984;50:23–30.
7. Yu J, Seethala RR, Walls A, Cai G. Fine-needle aspiration of breast carcinoma metastatic to follicular variant of papillary thyroid carcinoma. *Diagn Cytopathol* 2009; 37: 665–6.
8. de la Monte SM, Hutchins GM, Moore GW: Estrogen and progesterone receptors in prediction of metastatic behavior of breast carcinoma. *Am J Med* 1984;76:11–17.