

Congenital Hepatic Fibrosis : Report on Two Cases And its Clinicopathological Correlation

Neeraj Dhameja¹, Varnika Rai^{1*}, Rajeev Singh², Vineeta Gupta³, O.P Mishra³

¹Department of Pathology, Institute of Medical Sciences BHU, India

²Department of Radiodiagnosis and Imaging Medicine, Institute of Medical Sciences BHU, India

³Department of Pediatrics, Institute of medical sciences, BHU, India

Keywords: Congenital Hepatic Fibrosis, Caroli's Syndrome, Autosomal Recessive Polycystic Kidney Disease.

ABSTRACT

Introduction : Congenital hepatic fibrosis (CHF) is a relatively rare disease belonging to ductal plate malformations and considered as variant of autosomal recessive polycystic kidney disease with juvenile and young adult presentation.

Case report : Case 1 was a 13 year male, presented with complaints of abdominal pain and distension with multiple episodes of fever. Case 2 was a two year male patient, presented with complaints of abdominal swelling since birth, fever and nausea, along with palpable liver and non-palpable spleen.

Histopathological examinations in both cases showed dense portal fibrosis with preserved hepatocytes. Within the fibrotic portal tract dilated biliary channels were seen with neutrophilic infiltration in first case which was suggestive of superimposed cholangitis. Hepatic parenchyma showed normal arrangement of hepatocytes. Based on the findings diagnosis of CHF was made.

Conclusion : Congenital hepatic fibrosis though a rare disease should be considered in the differential diagnosis while dealing with pediatric liver biopsies.

***Corresponding author:**

Dr Varnika Rai , Sadhana Sadan , N4/35C- 92, Mahamana Nagar Colony, Karaundi, Suswahi, BHU, Varanasi- 221005, Uttar Pradesh. India

Phone: +91 9956827228

E-mail: vrachievers@gmail.com



Introduction

Congenital hepatic fibrosis (CHF) is considered as variant of autosomal recessive polycystic kidney disease with juvenile and young adult presentation.^[1] It is a relatively rare disease pertaining to ductal plate malformations.^[1] The disease appears in both sporadic (in many as 56% cases) and familial patterns. Congenital hepatic fibrosis-ARPKD is estimated to occur in 1 in 20,000 live births.^[2] Arrest of maturation and the lack of remodeling of the ductal plate engenders persistence of an excess number of immature embryonic duct structures which in turn stimulates the formation of portal fibrous tissue conferring the clinical picture of recurrent cholangitis or portal hypertension and associated symptoms.^[3] The disease appears in both sporadic and familial patterns. Clinically it is characterized by hepatic fibrosis, portal hypertension, and renal cystic disease. However clinical manifestations of CHF can be nonspecific. Here we are presenting two cases of congenital hepatic fibrosis presented within one year duration in SS Hospital, IMS BHU.

Case Reports

Case 1: A 13 year old male patient presented in the department of pediatrics of Sir Sunder Lal Hospital, IMS, BHU. Patient was having complaints of pain and distension in abdomen and multiple episodes of on and off fever and jaundice, along with history of melena and hematemesis. On physical examination- pallor present, there was increase in abdominal girth. Spleen and liver both were palpable. On ultrasound features of portal hypertension was present.

On Investigations, hemoglobin was 5.1 g/dl, Total leucocyte count was $12.6 \times 10^3 / \mu\text{l}$, Platelet count was 64000 / μl . Liver function tests revealed total bilirubin was 2.5 mg/dl, ALT was 69 U/L, AST was 46 U/L. Total protein was 6.3 g/dl. Serum urea 27 mg/dl and serum creatinine 0.5 mg/dl.

CT scan findings (fig 1A) showed hepatosplenomegaly with dilated central and peripheral intrahepatic biliary radicals with multiple round hypodense cystic areas showing central dot sign. Extra hepatic biliary channels were not dilated. CT findings are suggestive of Caroli's disease. Bilateral kidneys were mildly bulky, however cortico-medullary differentiation was within normal limits.

Histopathological examinations (fig 1B, C and D) showed dense portal fibrosis with preserved lobules of hepatocytes. Within the fibrotic portal tract dilated biliary channels were seen with neutrophilic infiltration which was suggestive of superimposed cholangitis. Hepatic parenchyma showed normal arrangement of hepatocytes. No granuloma or malignant cells were seen. Based on the clinical, radiological and histopathological findings, diagnosis of CHF was made.

Case 2: A 2 year old male patient was admitted in the pediatric ward of Sir Sunder Lal Hospital IMS BHU. Patient was having complaints of abdominal swelling since birth, fever and nausea since 15 days. On examination, pallor was present. Per abdomen, there was distension of abdomen with umbilicus central everted. Liver was palpable and spleen was non palpable. Bilateral renal lump palpable. Rest systemic examination were within normal limit.

On Investigations, hemoglobin was 7.4 g/dl, Total leucocyte count was $12.82 \times 10^3 / \mu\text{l}$, Platelet count was 6.5 lakh / μl . Liver function tests revealed total bilirubin was 0.3 mg/dl, AST was 152 U/L, ALT was 88 U/L. Total protein was 7.4 g/dl. serum urea 122 mg/dl and serum creatinine 2.9 mg / dl.

CT findings (fig 2A & B) were mild dilatation of central intrahepatic biliary radicals with focally dilated peripheral biliary radicals with central dot sign, suggestive of Caroli's disease. Bilateral kidneys were enlarged, hypodense with loss of cortico-medullary differentiation. Few focally scattered hyperdensities also noted likely calcifications. In view of findings of Caroli's disease, CT differentials were ARPKD and medullary sponge kidney.

Histopathological findings (fig 2C & D) were same as case no 1 however histopathological features of cholangitis were lacking. Liver biopsy showed dense portal fibrosis with several dilated ducts embedded in it. Lobules of hepatocytes were also noted with normal arrangement of hepatocytes thus further reinforcing our diagnosis of CHF.

Family history of both patients were negative for any fibropolycystic disease.

Discussion

Congenital hepatic fibrosis is considered as an autosomal recessive disorder.^[4] CHF is one of the fibropolycystic diseases, which also include Caroli's disease, autosomal dominant polycystic kidney disease (ADPKD), and autosomal recessive polycystic kidney disease (ARPKD).^[1]

Numerous cases of CHF coexists with autosomal recessive polycystic kidney disease (ARPKD) or dilatation of the intrahepatic or extrahepatic biliary tree, characteristic of Caroli's syndrome.^[5,6] On the basis of age of presentation and the degree of renal involvement, ARPKD has been divided into four types by Blyth and Ockenden^[3] – perinatal, neonatal, infantile and juvenile.

It predominantly affect children and adolescents.^[7] Infants present with abdominal distension from enlarged organs, respiratory distress and systemic hypertension. Older

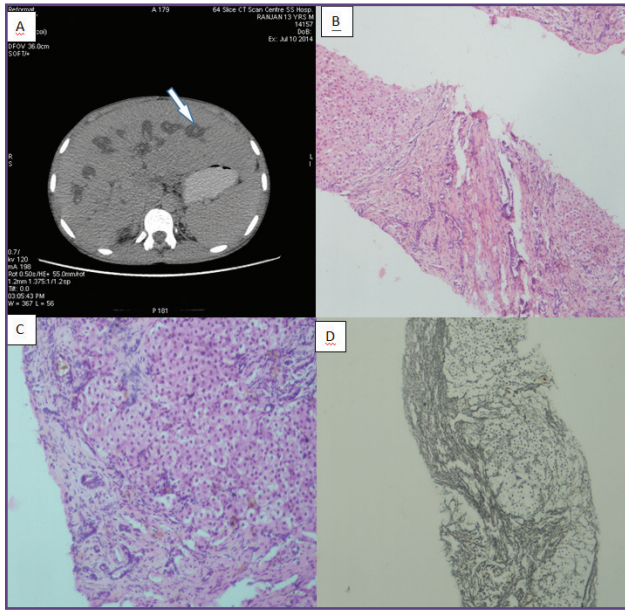


Fig. 1(A). NCCT Abdomen showing hepatosplenomegaly, dilated intrahepatic biliary radicals with hypodense cystic areas with “central dot sign” (arrow) suggestive of Caroli’s disease. **(B)** Liver biopsy with diagnostic dense fibrosis of portal tracts with numerous marginal dilated bile ductular profiles. (H& E 100 X). **(C)** Bile in few ducts with periductular neutrophilic infiltration (H& E, 200 X). **(D)** Portal area with extensive fibrosis and normal hepatocytes arrangement within nodule. (reticulin stain 100x)

patients present with hepatosplenomegaly or bleeding from oesophageal varices but can be asymptomatic.^[8] Renal involvement is maximal in perinatal group and minimal in juvenile group of ARPKD.^[3] In the infantile group the clinical picture is either of chronic renal failure or of increasing portal hypertension. The juvenile group classically incorporates children (mostly 1–5 years old) who present with portal hypertension. In liver histopathological changes are marked.^[3]

Patients of CHF with ARPKD typically present as neonates or infants with severe renal impairment or pulmonary insufficiency,^[4] likewise our second case presented with features of renal insufficiency however pulmonary insufficiency features were absent.

Caroli’s syndrome comprises a clinical syndrome which is a combination of Caroli’s disease and those of congenital hepatic fibrosis. Correspondingly our first case was also showing features of CHF in histology besides features of Caroli’s disease on radiological findings.^[9]

Four clinical forms of CHF have been recognized – portal hypertensive, cholangitic, mixed portal hypertensive-

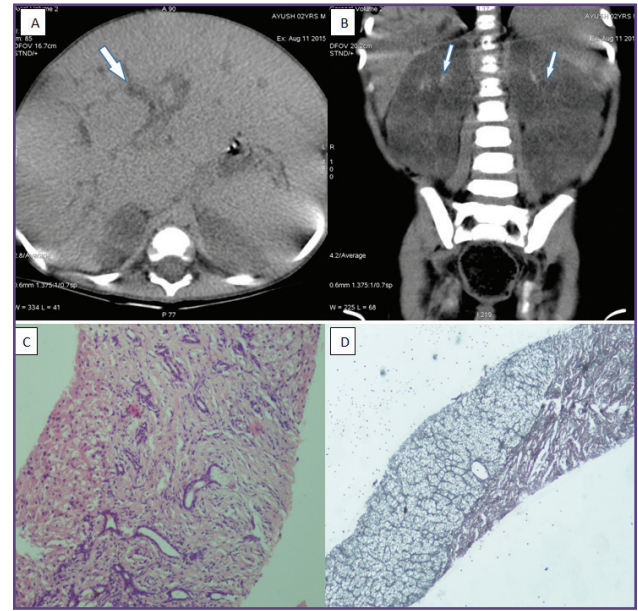


Fig. 2(A). NCCT abdomen axial sections of Case 2 showing mild central intrahepatic biliary duct dilatation. **(B)** NCCT abdomen coronal sections of Case 2 showing bilateral enlarged hypodense kidneys-ARPKD. **(C)** Portal area with extensive fibrosis and several bile ducts with cuboidal epithelium, arrested at different stages of the maturation process. (H & E , 200X). **(D)** Portal area with extensive fibrosis and normal hepatocytes arrangement within nodule. (reticulin stain 100x)

cholangitic and latent forms.^[10] The pure cholangitic form is rare. In the mixed form patients suffer from recurrent bouts of cholangitis, with or without jaundice, in addition to the manifestations of portal hypertension. Our first case is also showing feature of mixed type presentation with portal hypertension characterized by melena, hematemesis and splenomegaly along with cholangitis characterized by fever, jaundice and pain in abdomen.

Grossly Liver is enlarged in CHF, has a firm to hard consistency, and shows a fine reticular pattern of fibrosis, no cysts are visible to the naked eye.^[10, 11, 12]

According to Shorbhagi et al 2010^[11] laboratory workup may reveal mild elevations in liver enzymes. Concordantly in our both cases there was increased level of liver transaminases along with increased level of alkaline phosphatase. There was also elevation in total serum bilirubin due to associated cholangitis in our 1st case. Desmet et al^[13] 1992 described that abnormal renal functions tests were associated with extensive cystic renal disease, which might even progress to end-stage renal failure, this in agreement to our second case.

A confirmed diagnosis of congenital hepatic fibrosis can only be made by a examination of a liver biopsy. Histological findings: portal tracts show expansion by connective tissue, with wide areas of septal bridging fibrosis connecting portal tracts to each other.

Persistent ductal remnants are usually evident along the margins of portal tracts and fibrous septa. Interlobular bile ducts may be ectatic. Signs of cholestasis may be observed in the setting of associated cholangitis. Portal veins may be hypoplastic or completely absent.^[14] A portal vein anomaly can be present as a component of the disorder, rather than a consequence, since bile ducts and portal veins share embryonic origins. Livers affected by congenital hepatic fibrosis usually contain numerous Von Meyenburg complexes.^[4] Because of the similarities in the clinical picture, it is necessary to differentiate CHF from early liver cirrhosis, for which a liver biopsy is essential.^[1]

Congenital hepatic fibrosis can be distinguished from inflammatory bridging fibrosis or cirrhosis by lack of inflammation, lack of regenerative nodules, and presence of anastomosing biliary channels rather than proliferating bile ductules. Reticulin stain is useful because it may confirm the presence of regenerative activity as evidenced by cell plates greater than two cells thick in the cirrhotic liver.

As there was no supporting family history present both our cases appeared to be having autosomal recessive sporadic pattern. While our first case seemed to be a Caroli's syndrome (CHF with Caroli's disease), our second case was more likely a case of Congenital Hepatic Fibrosis with associated ARPKD. Both our patients are alive till date and are clinically stable.

Conclusion

Congenital hepatic fibrosis is a rare disease with varying age of manifestations. It can lead to portal hypertension and fatal complications appertained to it. Therefore pediatric liver biopsies should always be carefully evaluated in order to rule out diagnosis of CHF despite presence or absence of contributive clinical background of patient.

Acknowledgements

We are thankful to Dr Mohan Kumar

Funding

None

Competing Interests

None declared

Reference

1. Shorbagi A, Bayraktar Y. Experience of a single center with congenital hepatic fibrosis: a review of the literature. *World journal of gastroenterology* 2010;16: 683.
2. Patel J N et al. Congenital Hepatic Fibrosis associated with polycystic kidney disease. *Annals of Pathology and Laboratory Medicine* 2015;2:187-191.
3. Blyth M, Ockenden BG. Polycystic disease of kidneys and liver. *J Med Genet* 1971; 8:257-84.
4. Arroyo M, Crawford JM. Pediatric Liver Disease and Inherited, Metabolic, and Developmental Disorders of the Pediatric and Adult Liver. In Odze RD, Goldblum JR, eds. *Surgical Pathology Of The GI Tract, Liver, Biliary Tract and Pancreas*. 2nd ed. Philadelphia: Saunders Elsevier; 2009.p.1245-1290.
5. Nakanuma Y, Terada T, Ohta G. Caroli's disease in congenital hepatic fibrosis and infantile polycystic disease. *Liver* 1982;2:346-54.
6. Summerfield JA, Nagafuchi Y, Sherlock S, et al. Hepatobiliary fibropolycystic diseases. A clinical and histological review of 51 patients. *J Hepatol* 1986;2:141-56.
7. Portman BC, Roberts EA. Developmental abnormalities and liver disease in childhood. In: Burt AD, Portman BC, Ferrell LD, eds. *MacSween's Pathology of the Liver*. 6th ed. London, UK: Churchill Livingstone Elsevier;2012.p.102-156
8. Averback P. Congenital hepatic fibrosis: asymptomatic adults without renal anomaly. *Arch Pathol Lab Med* 1977;101:260-1.
9. Yonem O, Bayraktar Y. Clinical characteristics of Caroli's syndrome. *World J Gastroenterol* 2007; 13: 1934-1937
10. Fauvert R, Benhamou JP. Congenital hepatic fibrosis. In: Schaffner F, Sherlock S, Leevy CM, editors. *The liver and its diseases*. New York: Intercontinental Medical Book; 1974. p. 283-8.
11. Witzleben CL. Cystic diseases of the liver. In: Zakim D, Boyer TD, editors. *Hepatology A textbook of liver disease*. Philadelphia: WB Saunders; 1990.p. 1395-411.
12. De Vos BF, Cuvelier C. Congenital hepatic fibrosis. *J Hepatol* 1988;6:222-8.
13. Desmet VJ. What is congenital hepatic fibrosis? *Histopathology* 1992; 20: 465-477
14. Gocmen R, Akhan O, Talim B. Congenital absence of the portal vein associated with congenital hepatic fibrosis. *Pediatr Radiol* 2007; 37: 920-924.