

# A Rare Case of Juvenile Fibromatosis Infiltrating Neck Subcutis in a 3-year Old Girl

Amit Kumar<sup>1</sup>, Rakesh Mehra<sup>2</sup>, Tanushree Narain<sup>1</sup>, Neha Garg<sup>1</sup>, Pallavi Agrawal<sup>1\*</sup>

<sup>1</sup>Department of Pathology, Mahavir Cancer Institute And Research Centre, Patna (Bihar), India

<sup>2</sup>Department of Radiology, Mahavir Cancer Institute And Research Centre, Patna (Bihar), India

*Keywords: Juvenile, Fibromatosis, Neck, Submandibular*

### ABSTRACT

**Background:** Fibromatosis is a rare benign tumor of fibro-myofibroblastic origin. This non-metastasizing tumor has high potential to locally invade and recur after surgical excision. Since 1950, only 99 cases of fibromatosis of head and neck in pediatric age-group are reported in the literature. We present the 100th case in this category.

**Case-report:** A three year old girl presented with a right sided neck mass progressively increasing in size since one year. On imaging the tumor was found extending from submandibular to supraclavicular region, which on incisional biopsy showed features consistent with the diagnosis of Juvenile Fibromatosis. Histologically, it may be confused with other entities under broad diagnostic category 'fibromatoses', but immuno-histochemical analysis confirmed the diagnosis. Patient underwent wide local excision and was followed-up for two years with no features of recurrence.

**Conclusion:** A rare and interesting tumor of pediatric age group with high tendency to recur after surgical excision. But surgical resection with tumor free margins prognostically decreases the chance of recurrence.

**\*Corresponding author:**

Dr. Pallavi Agrawal, (M.D., DNB, PDCC) Consultant Pathologist, Room no. 314, Department of Pathology, Mahavir Cancer Institute And Research Centre, Patna (Bihar) 801505, India

Phone: +91 7739165410

E-mail: Dr.pallavimamc@gmail.com



## Introduction

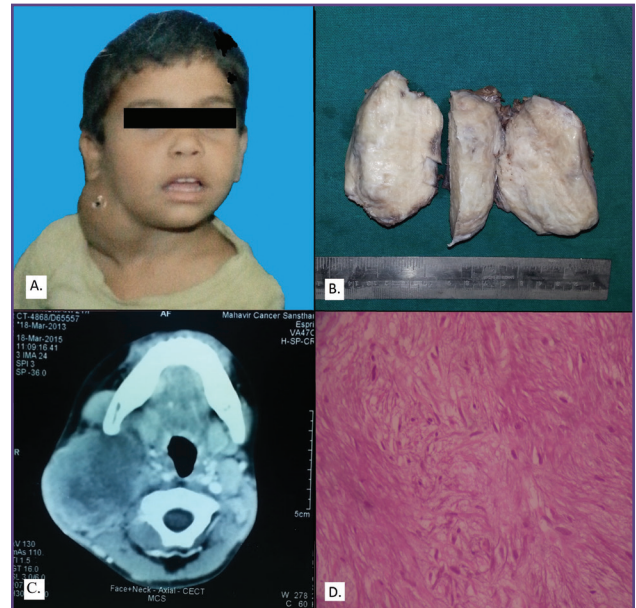
Fibromatosis is an extremely rare disorder with an incidence of 2-4 cases per million a year, representing only 0.03% of all neoplasm<sup>[1]</sup>. It is an apparently non-neoplastic condition characterized by proliferation of fibroblastic and myofibroblastic cells resulting in formation of tumor-like masses. It is a benign and locally invasive disorder without the metastatic potential but with tendency to recur<sup>[2, 3]</sup>. Till date only 99 cases of fibromatosis of head and neck in pediatric age group are reported in literature world-wide. Majority of the cases are sporadic with unknown etiology but some cases show familial predisposition i.e., occur as a part of Gardner's syndrome or Familial adenomatous polyposis<sup>[4, 5]</sup>. It is divided into the superficial and deep subtypes. Superficial fibromatosis include palmar and plantar fibromatosis while the deep fibromatosis usually involves muscles of trunk and limb. The deeper fibromatosis show tendency to locally invade and recur after surgical excision. We present the whole clinico-pathologic spectrum of a case of 3 year old girl diseased with this entity.

## Case Report

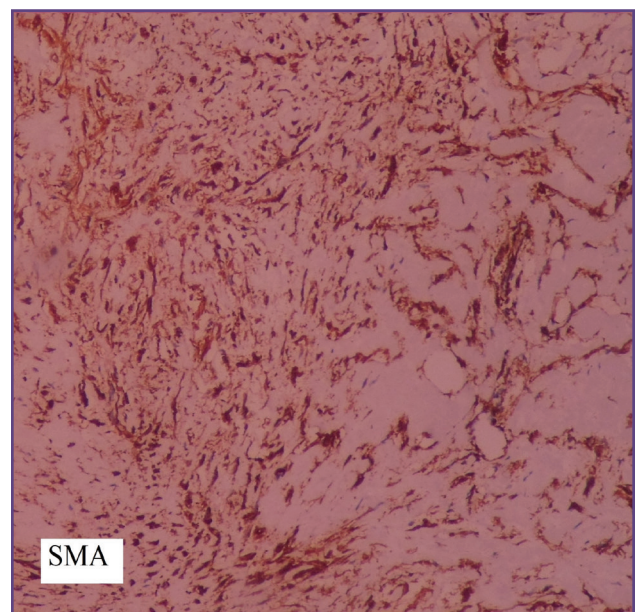
A 3-year old girl presented with a large right-sided neck mass since one year which was progressively increasing in size (Fig-1). On physical examination a firm, non-tender, mobile swelling measuring 9×5cm was identified extending from submandibular to the supraclavicular region. The overlying skin appeared excoriated but wasn't fixed to the underlying mass. There was no regional lymphadenopathy. The child was otherwise doing well. All the hematological and biochemical parameters were within the normal limits. Contrast enhanced computerized tomography (CECT) revealed a well-defined heterogeneously enhancing mass lesion measuring 9×6×4cms with infiltration into the surrounding muscles. An incisional biopsy was performed from the visible mass which on histopathological examination showed ill-defined nodule like structure composed of an admixture of spindle to plump fibroblast in vague fascicular arrangement. Nuclear atypia and necrosis was not seen. It was diagnosed as 'benign spindle cell tumor with likely possibility of Juvenile Fibromatosis'.

Multidisciplinary team planned for the wide local excision of the lesion due to the progressively increasing size of mass and close approximation of mass with the neuro-vascular bundle in neck. Internal jugular vein and sternocleidomastoid muscle were preserved. Gross examination showed a well-circumscribed non-capsulated solid mass measuring 10×7×6cms. Cut-surface was firm, homogenous and grey-white. Histopathological examination showed plump fibroblast in vague fascicular arrangement. No nuclear atypia, mitoses, necrosis hemorrhage or calcification was identified. A provisional

diagnosis of Juvenile Fibromatosis was considered which was confirmed on IHC. The tumoral cells were diffusely positive for SMA (Fig-2). The patient was followed-up for two years with no evidence of recurrence.



**Fig-1: (A) Clinical picture showing the extension of the right sided neck mass. (B) Gross photograph of the solid well circumscribed tumor. (C) CECT scan shows a well-defined heterogeneously enhancing lesion with central necrosis. (D) High-power view showing spindle to plump fibroblasts arranged in vaguely fasciculated pattern with no nuclear atypia or mitoses, H&E 400X.**



**Fig-2: Photomicrograph showing tumor cells diffuse immunoreactive with SMA (DAB, 400X)**

## Discussion

Fibromatosis is a benign but locally invasive neoplasm of fibro-myofibroblastic origin. It can occur at any age, but very rarely seen in infants and juvenile age group. This tumor is of unknown etiology though the role of localized trauma, endocrine and genetic factors are suggested by some authors. Sometimes fibromatosis regresses at menarche and an anti-estrogen tamoxifen has been shown to have an inhibitory effect on such lesions suggesting the role of endocrine factor in etiology. The most common site of involvement in pediatric age group is scalp and neck usually presenting as a nodular mass in subcutis as is reported in this case [6]. Fibromatosis can occur at other sites like arm, shoulder, axilla, mesentery and abdominal wall. These lesions are usually solitary but can be multiple. This tumor is highly predisposed to locally invade the surrounding tissue. CT and MRI can help in assessing the degree of local invasion. These lesions never metastasize, however 10% exhibit unpredictable biological behavior with extremely aggressive growth potential. Histopathological examination remains the gold-standard modality for diagnosis. The microscopic picture comprises of well-defined nodules of plump to spindle shaped fibroblasts arranged in vaguely fascicular pattern. These tumors lack nuclear atypia, mitoses and necrosis. Immunohistochemical analysis shows diffuse positivity with vimentin and SMA. Fibromatosis constitutes part of a spectrum of poorly understood proliferative lesions whose histologic features overlap to such an extent that it becomes very important for the pathologist to be aware of the anatomic location of lesion, sex and clinical behavior before characterizing the lesion. Juvenile Fibromatosis is an entity which comes under the broader diagnostic group 'Fibromatoses' which includes other tumors of fibro-

myofibroblastic origin sharing similar histologic features [7]. The differential diagnoses of Juvenile Fibromatosis are discussed in Table-1. Wide local excision of the tumor with clear margins remains the treatment modality of choice with proper follow-up. This makes fibromatosis a very difficult condition to treat in young patients especially in head and neck region where excision becomes difficult without sacrificing vital structures and neurological structures. There is no consistently successful drug therapy available. Cytotoxic chemotherapy utilizing drugs such as methotrexate, vinblastine/ vinorelbine have been given to delay progression of the tumor until child is considered old enough for radiotherapy. Therapeutic responses also have been observed after non-cytotoxic drugs such as anti-estrogens or non-steroidal anti-inflammatory drugs (NSAIDs). NSAIDs stimulate the immune response and impair the proliferation of tumor cells. Radiation therapy is indicated in inoperable cases, after R2 resection (resection with gross positive margins/ incomplete margins) and R1 resection (surgery with microscopic positive margin) [8]. Prognosis of the Juvenile Fibromatosis is very good with no metastasis. Great care must be taken in the clinico-radiologic diagnosis of soft tissue tumors and this entity must be always kept in mind while formulating diagnosis of such cases.

## Conclusion

Juvenile Fibromatosis is a benign locally invasive neoplasm of rarity. The biopsy and immuno-histochemical examination remains the gold-standard for diagnosis of this entity. Surgical excision of the tumor is the main-stay of treatment. This case is presented to emphasize on the challenges faced for diagnosing such lesions as they have

**Table 1: Differential diagnosis for juvenile fibromatosis.**

Differential Diagnosis	Histopathological features and immuno-histochemical feature
Reactive fibrosis	Variable growth pattern with focal hemorrhage and hemosiderin deposition
Fibromatosis colli	Originate from sternocleidomastoid. Diffuse fibroblastic proliferation of varying cellularity with entrapped and atrophic muscle fibers.
Fibrous hamartoma of infancy	Organoid pattern composed of interlacing fibrous trabeculae, islands of loosely arranged spindle shaped cells and mature adipose tissue. Vimentin(+), Actin(+)
Infantile myofibroma	Nodular growth pattern. Plump myoid spindle cells, cigar shaped nuclei with eosinophilic cytoplasm. Occasional nuclear atypia. Vimentin(+), actin(+), S-100(-)
Infantile fibrosarcoma	Sheets of solid packed spindle cells arranged in herring bone pattern, hyperchromatic nuclei with predominant nucleoli. Moderate mitoses. Vimentin(+), SMA(+), Desmin(-), myoglobin (-), S-100(-).
Benign fibrous histiocytoma	Short intersecting fascicles of fibroblastic cells arranged in storiform pattern. Occasional histiocytic with giant cells. CD68(+)
Juvenile aponeuritic fibroma	Plump fibroblast with round or ovoid nuclei, indistinct cytoplasm separated by dense collagen. Occasional mitotic figures.

to be differentiated from other soft tissue tumors which display borderline pathological features regarding benign or malignant behavior. Immuno-histochemical analysis is generally helpful to reach a definitive diagnosis.

### Acknowledgements

The author would like to record the appreciation for the thoughtful and skilled guidance of the Consultants of the Department of Pathology, Mahavir Cancer Institute and Research Centre, Patna. Without the willing assistance of these people, it would have been difficult to work on this topic.

### Funding

None

### Competing interests

None

### Reference

1. Basha SM, Dutt SC, Murthy NS, Syed G. Juvenile fibromatosis of the temporomandibular joint: A rare case report. *Dent Res J*, 2014; 11(2): 284-87.
2. Wilkins SA, Waldron CA, Matthews WH et al. Aggressive fibromatosis of the head and neck. *Am J Surg*. 1975; 130: 412-16.
3. Seper L, Burger H, Vormoor J, Joos U, Kleinheinz J. Aggressive fibromatosis involving the mandible: Case report and review of the literature. *Oral Surg Oral Med Oral Pathol Oral Radiol Endod*. 2005;99; 30-8.
4. Lee JC, Thomas JM, Phillips S et al. Aggressive fibromatosis: MRI features with pathologic correlation. *Am J Roentgenol*, 2006; 186(1): 247-54.
5. Carr RJ, Zaki GA, Leader MB et al. Infantile fibromatosis with involvement of the mandible. *Brit J Oral Maxillofacial Surg*. 1992; 30; 257-262.
6. Perez Cruet MJ, Burke JM, Weber R et al. Aggressive fibromatosis involving the cranial base in children. *Neurosurgery*, 1998;43: 1069-102.
7. Debner Louis P. Soft Tissue, Peritoneum and Retroperitoneum: In pediatric Surgical Pathology. 2<sup>nd</sup> Ed. Baltimore, USA. Williams and Wilkins 1987: 885-90.
8. Halperin E, Brady L, Perez C, Wazer D. Principles and practice of radiation oncology, 6th Ed. Lippincott, Williams and Wilkins, Philadelphia 2013;(78):1535.