

# A Study of Histological Types of Leprosy Along with Clinico-Histopathological Correlation in a Tertiary Centre from North Maharashtra Region

Maya S Vasikar\*, Bharati M. Patil, and Rajesh Y. Thakur

Dept of Pathology, Shri Bhusaheb Hire Govt. medical College, Dhule, Maharashtra, India

## ABSTRACT

**Background:** To achieve WHO new global strategy of 2016-, To decrease the case load of leprosy, early and proper classification of leprosy for proper treatment and avoiding disability due to leprosy. Aim- Aim of this study was to find out the incidence of various histological types of leprosy in North Maharashtra. To find out which is the common type and to know the importance of histopathological examination in diagnosis of leprosy and its correlation clinically.

**Methods:** A retrospective study of five years from Jan 2011 to Dec 2015 was conducted in the department of Pathology Government Medical College Dhule. Clinical diagnosis was correlated with histopathological report.

**Results:** Sixty seven clinically diagnosed cases were included in the study. From sixty seven cases two cases on histopathological and on AFB (Fite Ferraco) stain were negative for leprosy. The Male to Female ratio was 0.8:1, maximum cases belonged to age group 21-30 years, and clinically hypo-pigmented hypo aesthetic macules were commonly seen. Clinically as well as histopathological Borderline Tuberculoid leprosy was common, it also showed maximum parity. A case of Histoid leprosy was too diagnosed on HPE which clinically was diagnosed as lepromatous leprosy. Erythema nodosum leprosum two cases were diagnosed clinically as well as histopathological in this period. Fite Farraco stain was positive in all cases of borderline lepromatous and lepromatous leprosy.

**Conclusion:** A combination of clinical diagnosis, histopathological examination along with AFB stain is essential for proper treatment of the patient and for achieving leprosy free world.

**Keywords:** Leprosy, Macules, Histopathology, Fite Farraco Stain.

## Introduction

Leprosy is a chronic infectious disease caused by Mycobacterium Leprae. It can affect any age and both sex. Leprosy was a major public health problem of India in the last century. Hence in 1955 the leprosy control programme was initiated with single drug Dapsone. In 1982 it was switched to multidrug therapy following the recommendation of WHO [1]. There was dramatic decline in number of leprosy patient in the world. In 1993, the National leprosy Elimination programme (NLEP) was initiated by WHO. The goal of the programme was to decrease the prevalence rate of leprosy below 1 case/10,000 population. India has achieved this goal in December 2005 by achieving the prevalence rate of leprosy 0.95 cases/10,000 populations [2]. In March 2006 it is further declined to 0.84/10,000 population [3].


The focus of WHO was to eliminate leprosy at global level by the end of 2000 year. In 2015 a total of 2, 10758 new leprosy cases were reported from 106 countries in all WHO regions, representing a 21% drop from the number of cases

reported in 2005 [4]. India has 60% of the entire global case load, followed by Brazil and Indonesia [4]. In 2016 WHO has launched a new global strategy. The global leprosy strategy 2016-2020: "Accelerates towards a leprosy free world." It aims to reinvigorate efforts for leprosy control and to avoid disability, especially among children affected by the disease in endemic countries [5].

To achieve WHO new global strategy and to decrease the global case load, it is essential to have an early, proper diagnosis, by clinical and, histopathological correlation, so a complete treatment according to the type of leprosy can be given. Hence the present study was undertaken to know which type of leprosy is common in North Maharashtra and clinico-histopathological correlation was done to avoid mislabelling of a case. Thus it will help in avoiding disability as well as grievance to the patient and to the society.

## Material and Methods

A retrospective study of five years from January 2011 to December 2015 was conducted in our department. We



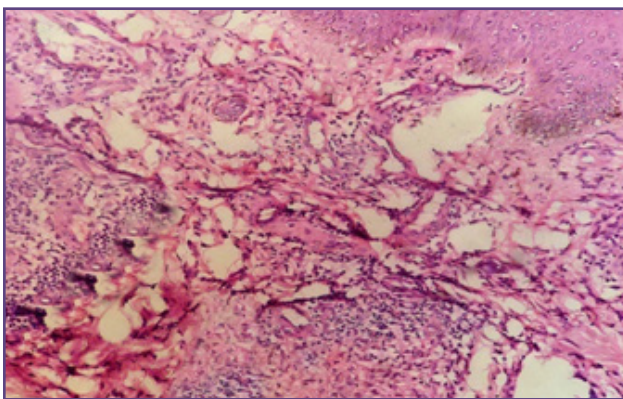
received sixty seven skin biopsies of clinically diagnosed leprosy cases in the five year study span. The biopsy specimens were processed as per standard procedure, sections were stained with haematoxylin-eosin and Fite-Faraco stain was done for demonstration of acid fast bacilli. Ridley-Jopling classification was used to classify leprosy. The histopathology slides along with its AFB (Fite Farraco) stain were reviewed. Clinical data and clinical diagnosis done by dermatologist were retrieved from the histopathological requisition form.

## Results

The study shows that 30(44.7%) were male, while 37(56.9%) were female. The male to female ratio was 0.8:1. The majority of patient belonged to 21-30 years (26.8%), followed by 11-20 years (25.4%). The age group of patient ranged from 9 years to 83 years. Clinically the most common presentation was hypo-aesthetic, hypo-pigmented macules 65%, followed by plaque 30%, nodules 3%, Erythematous lesion 2%. The highest number of cases clinically diagnosed were borderline Tuberculoid (BT)56.7%, followed by borderline lepromatous(BL)13.4%,lepromatous leprosy(LL)11.9%,indetermine leprosy(IL) and Tuberculoid leprosy(TT) both 7.4% and two cases of erythema nodosum leprosum2.9%.

**Table 1: Clinico- histopathological co-relation.**

HPE TYPE	NO.of cases	IL	BT	TT	BL	LL	ENL	Parity
IL	7	2	5					28%
BT	24	1	22	1				91%
TT	9	1	4	4				44%
BL	14		6		6	2		42%
LL	8				3	5		62%
Histoid	1					1		
ENL	2						2	100%
Chr infl	2	1	1					
<b>TOTAL</b>	<b>67</b>	<b>5</b>	<b>38</b>	<b>5</b>	<b>9</b>	<b>8</b>	<b>2</b>	<b>67</b>

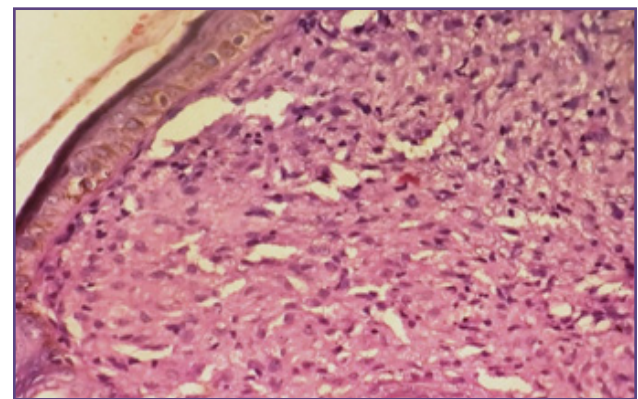


**Fig. 1: Borderline Tuberculoid Leprosy (400X H&E)- showing granuloma of epithelioid cells and lymphocytes in dermis.**

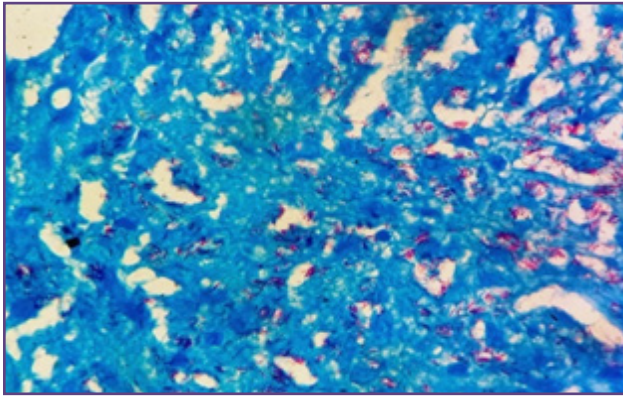
On histopathological examination, the most common histological type was borderline Tuberculoid (BT) leprosy 35% (fig 1), followed by borderline lepromatous (BL) 20.8%, Tuberculoid (TT) leprosy 13%, lepromatous (LL) leprosy 11.9% (fig 2), indeterminate leprosy (IL) 10.4%. From sixty seven cases, two cases diagnosed as indeterminate leprosy and Borderline Tuberculoid leprosy, on histopathological showed no evidence of leprosy. They were diagnosed as perivascular dermatitis

Fite Farraco stain for demonstration of Acid fast lepra bacilli was done in all cases. It was positive in all the histopathological diagnosed BL and LL types of leprosy cases (fig 3). It was negative in IL, TT and 9 cases of BT leprosy.

Analysis of clinical diagnosis & histopathological types was done (Table1). Maximum parity of 91% was seen in borderline Tuberculoid leprosy, followed by lepromatous leprosy 62%. Two cases of Erythematous nodosum leprosum were diagnosed clinically and they were confirmed by HPE. Both the cases were of lepromatous leprosy, on treatment. A case of lepromatous leprosy was diagnosed as Histoid leprosy on histopathology (fig 4). The patient was a male aged 42 years. Histoid leprosy showed bundles of acid fast bacilli in spindle shaped cells.



**Fig. 2: Lepromatous Leprosy, early stage (400X H&E)- Thinning of epidermis, macrophages with pink, granular cytoplasm in dermis.**



**Fig. 3: Fite Farraco stain : positive for Acid fast bacilli (100X) in fig 2 case.**

### Discussion

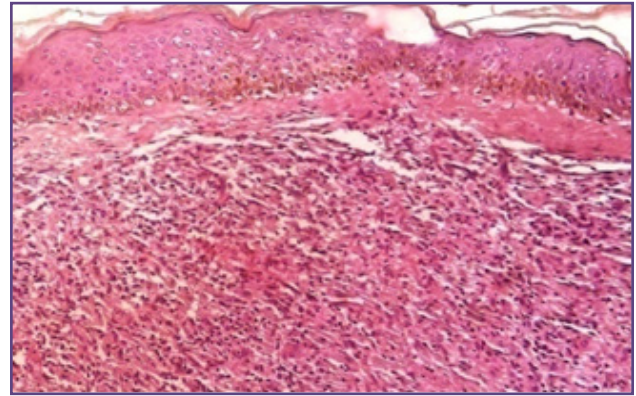
Leprosy, Hansen's disease is an infectious and highly curable disease.

In the present study, the male to female ratio was 0.8:1. A slight increase in female preponderance was seen. While male preponderance was seen in studies conducted by M Giridhar (2012)<sup>[6]</sup>, Moorthy(2001)<sup>[7]</sup>. The explanation provided was inhibition on the part of females for reporting and treatment due to social taboos and stigma<sup>[6, 7]</sup>. In our setting we can say that as years passed health awareness in females has increased due to mass media.

Maximum cases (26.8%) belonged to young, active age group 21 to 30 years. Majority of the studies showed maximum cases in the same age group (41%-23.5%)<sup>[6, 7, 8, 9]</sup>. Least numbers of cases (2.9%) were below the age of 10 years in present study. This is explained due to of longer incubation period of lepra bacilli<sup>[10]</sup>. The eldest case in our study was 84 years female while 9 year boy was the youngest case. Again explaining that increased awareness in mother resulting in early diagnosis in a 9 year old boy.

Hypo pigmented, hypoaesthetic macules were the commonest clinical lesions (65%) seen in our study, and in these lesions, features of IL, BT, TT leprosy were frequently found. While in plaque (30%), nodules (2%), features of BL, LL, and Histoid leprosy were seen. Similar result was obtained in a study by Vargas Ocampo and Francisco 2004<sup>[11]</sup>, Shivmurthy V 2013<sup>[12]</sup>.

Two cases clinically diagnosed as IL and BT leprosy, on histopathological examination were diagnosed as perivascular dermatitis. Similar finding was seen by Manander U et al<sup>[13]</sup>. While M Giridhar et al<sup>[6]</sup> diagnosed Lupus Vulgaris and vitiligo in two clinical diagnosed cases of leprosy. The discrepancy is explained due to misinterpretation and over diagnosis of hpigmented macule as leprosy. Misdiagnosis is common in children



**Fig. 4: Histoid Leprosy- interlacing bands of spindle shaped cells.**

with IL type of leprosy with hypopigmented patch on face in whom sensory deficit is difficult to illicit<sup>[9]</sup>.

BT was most common clinical (56.7%) and histopathological (35%) type of leprosy in our study. Similar findings were seen in other studies too<sup>[12, 13, 14,]</sup>.

The clinical and histopathological correlation was seen in 41 cases (61%) in our study. While Kumar et al<sup>[15]</sup> found 60.6% in the year 2000, Pandya<sup>[16]</sup> et al found 58% in the year 2008, Mathur<sup>[17]</sup> et al found 80.4% in 2011, Giridhar<sup>[6]</sup> et al found 60.23% in 2012, Rizvi<sup>[9]</sup> et al found 70% in the year 2015, Banushree C S<sup>[18]</sup> found highest 79.44% in the year 2016.

In our study maximum parity was seen in BT (91%), followed by LL (62%), which co-related with Manandhar u et al<sup>[13]</sup>. While B Mehta et al<sup>[8]</sup>, Moorthy et al<sup>[7]</sup>, Banushree et al<sup>[18]</sup> found maximum parity in lepromatous leprosy. While Alia Rizvi<sup>[9]</sup> et al found maximum parity in Tuberculoid leprosy. Indicating maximum parity in polar type of leprosy.

One case of TT and one case of BT leprosy showed histological features of indeterminate leprosy. Similar findings were noted by other authors too<sup>[13, 19, 20]</sup>. Five cases of BL leprosy were classified as BT leprosy. Bhatia A S<sup>[19]</sup> et al and Sehgal V N<sup>[20]</sup> also noted similar findings.

Histoid leprosy is considered as a variant of lepromatous leprosy. It shows male preponderance and the average age of diagnosis is between 21 and 40 years<sup>[21]</sup>. Our case was too clinically diagnosed as lepromatous leprosy, the patient was a male aged 42 years and showed nodular presentation.

Two cases of Erythema Nodosum leprosum were clinically and histopathological diagnosed. Both the cases were of Lepromatous leprosy on treatment. The end of National leprosy eradication programme (NLEP) in India indicates the elimination of leprosy as a public health problem. But

numbers of newly diagnosed leprosy cases are increasing in private and teaching hospitals<sup>[16, 17]</sup>.

### Conclusion

Though clinical diagnosis of types of leprosy can be done, to avoid disparity and for proper treatment histopathological examination and Fite Farraco stain is essential. Thus a definitive diagnosis and proper treatment will help us to achieve the WHO global leprosy strategy 2016-2020: Accelerating towards leprosy free world.

### References

1. Rao P N: Recent advances in the control programs and therapy of leprosy. *Indian J Dermatology Venerology Leprology*.2004; 70: 269-76.
2. Special Correspondent, India achieves leprosy eradication target. *The Hindu News paper* 2005, Jan 31, p 15.
3. National leprosy eradication programme-Progress report for the year 2006, central leprosy division. Directorate General of health services, Nirbhan Bhavan, New Delhi; 2006.
4. WHO Global leprosy update on the 2014 situation. *Weekly epidemiology record*, 2014; 36:389-400.
5. Global leprosy programme. *Global leprosy strategy 2016-2020*; 2016: 7.
6. Giridhar M, Arora G. Clinico-histopathological concordance in leprosy: A Clinical, Histopathological and Bacteriological study in 100 cases. *Indian Journal leprosy*.2012; 84:217-225.
7. Moorthy BN, Kumar P, Chatura KR, Chandrasekhar HR, Basavaraja PK. Histopathological correlation of skin biopsies in leprosy. *Indian journal of Dermatology Venerology Leprology*.2001; 67:299-301.
8. Mehta B, Desai N, Khar S. Clinico-pathological co-relation in leprosy. *International journal of dermatology*.2012; 9(1):1-5.
9. Rizvi AA, Sharma YK, Dash K et al: An epidemiology and clinico-histopathological study of leprosy in semi urban area under Pimpri Chinchwad Municipal Corporation in Pune district Maharashtra. *Medical journal of Dr D Y Patil university*.2015; 8(5):609-613.
10. Fine PE. Leprosy: the epidemiology of a slow bacterium. *Epidemiology Rev*. 1982; 4: 161-188.
11. Vargas-Ocampo and Francisco. Analysis of 6000 skin biopsies of the National leprosy control Programme in Mexico. *Int J Lepra-other Mycobact Dis* 2004 59;28-35.
12. Shivamurthy V, Gurubasavraj H, Sastry SP, Kumar P: Histomorphological study of leprosy. *Afr J Medical health science*.2013;12: 68-73.
13. Manandhar U, Adhikari RC, Sayami G: Clinico-histopathological correlation of skin biopsies in leprosy. *Journal of Pathology Nepal*.2013; 3:452-8.
14. Tiwari M, Ranabhat S: Clinico-histopathological correlation of leprosy. A retrospective study of skin biopsy specimens in Chitwan Medical Science Research and Practise 2015, 2 (1): 8-11.
15. Kumar A, Negi SR, Vaishnav K. A study of clinic-histopathological correlation of leprosy in a tertiary care hospital in western district of Rajasthan. *J Res Med Den Sci* 2014; 2:43-8.
16. Pandya AN, Tailor H J. Clinico histopathological correlation of leprosy. *Indian J Dermatology Venerology Leprology* 2008; 74:174-6.
17. Mathur MC, Ghimre RBK, Shrestha P, Keda SK. Clinicopathological correlation in leprosy. *Kathmandu Univ Med J* 2011; 9: 248-51.
18. Banushree CS, Bhat RV. Clinicopathological correlation of Hansen's disease, a retrospective study of skin biopsies. *Indian Journal of Pathology and Oncology*, 2016; 3(3): 491-495.
19. Bhatia AS, Katach K, Naryanan R B. Clinical and histopathological correlation of leprosy. *Int J Lepra-other Mycobact Dis* 1977; 45:278-80.
20. Sehgal VN, Sardana K, Dogra S: The imperatives of leprosy treatment in the pre and post global leprosy elimination era: appraisal of changing the scenario to current status. *J Dermatology treatment*. 2008; 19: 82-91.
21. Annigeri SR, Metgud SC, Patel JR: Lepromatous leprosy of Histoid type: A case report *Indian Journal Medical Microbiology*. 2007; 25.

#### \*Corresponding author:

**Dr Maya Vasaikar**, Jaihind college Road, Behind Modern Nursery, opposite DR. Morey hospital. Deopur, Dhule, 424002, Maharashtra, India.

**Phone:** +91 8806052553

**Email:** mayavasaikar@yahoo.co.in

**Financial or other Competing Interests:** None.

**Date of Submission :** 21.11.2016

**Date of Acceptance :** 05.04.2017

**Date of Publication :** 05.07.2017