

Urinary Bladder Cancer: Two Rare Cases

Meenu Gupta*, Gopinath Barui and Tushar Kanti Das

Dept of Pathology, R.G. Kar Medical College Kolkata (India)

ABSTRACT

Urinary bladder carcinoma is the seventh most common carcinoma worldwide. Most common type is urothelial carcinoma. Rest of the types are squamous cell carcinoma, Adenocarcinoma, small cell carcinoma, sarcoma. Here we present two rare cases of urinary bladder carcinoma one 72 yr. male diagnosed as Adenocarcinoma and another 55 yr. female diagnosed as Squamous cell carcinoma, both presented with features of hematuria and irritating symptoms of bladder.

Keywords: Urinary Bladder Cancer, Adenocarcinoma, Squamous Cell Carcinoma, Rare Cancers

Introduction

Bladder tumor is the seventh most common tumor worldwide. Urothelial carcinoma is the commonest type accounting of 90% of all primary tumors of the bladder. As per the Indian Cancer Registry data in men, it is the 9th most common cancer accounting for 3.9% of all cancers. Male to Female ratio of urinary bladder cancer is 8.9 :1. In urothelial carcinoma there is a high tendency for divergent differentiation leading to a variety of histologic variants.

Primary adenocarcinoma of bladder is derived from the urothelium of bladder but exhibit a pure glandular phenotype. Patients usually presented in 6th and 7th decade of life with male predominance. [1,2] Squamous cell carcinoma of bladder is a rare malignancy accounting for 1-3 % of bladder. Infection with parasite Schistosoma hematobium is an important risk factor in the parts of the world where organism is endemic. [3] In both Adenocarcinoma and Squamous Cell Carcinoma, hematuria is the most common symptom, but some patients present with bladder irritation symptoms.

Here we present two rare cases of urinary bladder carcinoma, 72 Yr male presenting with adenocarcinoma and 55 yr female presenting with squamous cell carcinoma.

Case Report

CASE 1: A 72-year male patient presented in the surgery outdoor with complain of on and off hematuria and increasing frequency and burning sensation during micturition for past 2 months. Patient is a known diabetic, hypertensive and has hypothyroidism for which he is on medication.

Physical examination was within normal limits. An ultrasound was done which showed normal size and shape of urinary bladder with an echogenic mass (27 x 26

mm) seen in the lateral wall. No lesion was found in the colorectal area. After which cystoscopic biopsy was taken and send to the department of pathology, it consists of multiple fragmented tissue pieces all together measuring (4x3x1.5) cm. Whole of the tissue was processed.

Microscopy showed back to back arrangement of glands with definite invasion in muscularis propria. The glands were morphologically adenocarcinoma of intestinal type. No evidence of urothelial carcinoma was found even after repeated processing and sectioning of whole of the tissue. Histomorphological features consistent with the diagnosis of Invasive Adenocarcinoma of bladder (enteric type) .(Fig. 1)

Metastatic Adenocarcinoma was ruled out with the study of ultrasonography and C.T. scan and other ancillary investigations which was negative for any primary in colorectal area.

CASE 2: A 55-year-old female presented to the surgery outdoor with the complain of hematuria for 3 months. Physical examination was not significant. Then an ultrasonography was performed that revealed a large lobulated heterogeneous space occupying lesion (60x50x27) mm at the right lateral wall of the urinary bladder.

A cystoscopic biopsy was taken consisting of multiple fragmented tissue pieces all together measuring (3x2x1) cm. Whole of the tissue was processed.

Microscopically it revealed squamous cells with definite pearl formation along with intercellular bridges arranged in sheets. Most of the area showing mild to moderate differentiated form. No area of Urothelial carcinoma was seen even after searching meticulously. Histomorphological features are consistent with Invasive Squamous Cell Carcinoma .(Fig. 2)

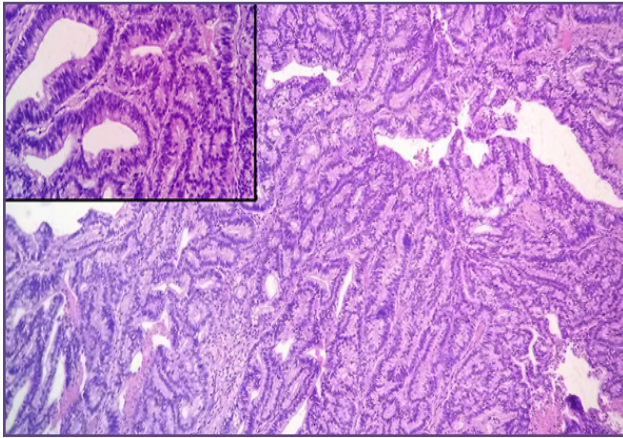


Fig. 1: Pictograph showing low power and high power (inset) view of Adenocarcinoma of urinary bladder, enteric type. H&E Stain 100X and 400X (inset).

Discussion

Urinary bladder cancer arises from epithelial lining (urothelium) of the urinary bladder. The most common type is Urothelial carcinoma. Other less common types include squamous cell carcinoma, adenocarcinoma, sarcoma, small cell carcinoma and secondary deposits from other cancers in the body. The common origins of secondary bladder adenocarcinomas include the colon, prostate, endometrium, cervix, breast and lung. [4,5]

Adenocarcinoma is an uncommon malignancy in the urinary bladder, which may arise primarily in the bladder as well as secondary from a number of other organs. Most notably, almost 90% of bladder tumors in patients with exstrophy of bladder are adenocarcinoma. [6] Up to 10% of all bladder cancers are adenocarcinomas in areas where schistosomiasis is endemic. [7] Other possible risk factors include chronic irritation, obstruction, cystocele and endometriosis. Grossly, bladder adenocarcinoma usually arises from the trigone and posterior wall but can be found anywhere in the bladder. Histologically, bladder adenocarcinoma exhibits various growth patterns: (a) enteric (colonic or intestinal); (b) mucinous (colloid); (c) signet ring cell; (d) mixed patterns and (e) not otherwise specified (NOS). [3]

The enteric pattern is composed of intestinal-type glands with pseudostratified columnar cells and nuclear atypia, closely resembling colorectal adenocarcinoma. It may produce intracellular or extracellular mucin, and necrosis is not infrequent. In this case, adenocarcinoma is of enteric type.

The mucinous pattern produces abundant extracellular mucin with tumor cells floating in a pool of mucin. The signet ring cell pattern is composed of diffusely infiltrative

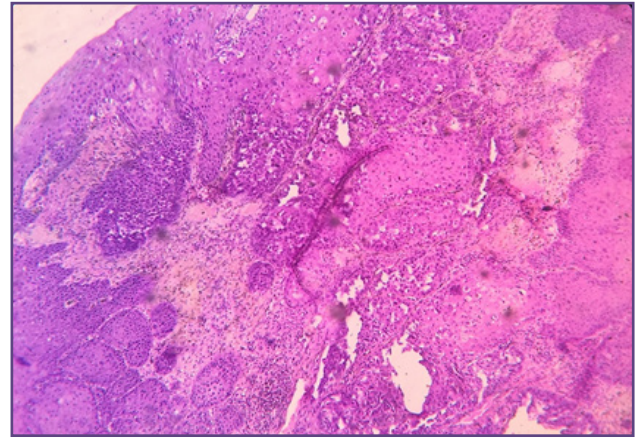


Fig. 2: Pictograph showing low power view of Pure Squamous Cell Carcinoma of urinary bladder. H&E Stain 100X.

poorly differentiated cells with prominent intracellular mucin and indented eccentric nuclei. A number of benign glandular lesions should be also considered in the differential diagnosis of bladder adenocarcinoma.

Cystitis cystica et glandularis may become florid, mimicking adenocarcinoma. In our case report the diagnosis of primary bladder carcinoma was made only after exclusion of secondary involvement by adenocarcinoma from other organs. Secondary bladder adenocarcinomas are more common than primary adenocarcinoma. [8]

It is very difficult to differentiate urachal from non urachal origin of bladder adenocarcinoma. Due to the presence of lateral location of the tumour, absence of cystitis cystica and cystitis glandularis on histopathology, with definite evidence of adenocarcinoma involving the full thickness of bladder wall including deep tissue and no evidence of urachal elements, involvement of space of Retzius, anterior abdominal wall or umbilicus seen morphologically or radiologically, in this case the diagnosis of primary adenocarcinoma of bladder was considered.

Non-cystic urachal adenocarcinomas resemble the primary urinary bladder adenocarcinomas and exhibit a similar histological spectrum. The enteric type is morphologically indistinguishable from colorectal adenocarcinoma (WHO 2016).

In countries such as Egypt where schistosomiasis was endemic, SCC has historically represented the predominant histological type of bladder cancer. Schistosomiasis is considered the major predisposing factor for SCC and is responsible for the high incidence of SCC in these regions. [9]

In both SCC and Urothelial carcinoma, tobacco smoking has been reported as a major risk factor for bladder

cancer. Squamous metaplasia involves non-keratinizing or keratinizing whitish plaques floating on an inflamed urothelium and has been linked to SCC.^[10]

The risk of bladder cancer development following squamous metaplasia is 21–42%.^[11] SCC is described as an epithelial neoplasm exclusively displaying histological features such as squamous pearls, intercellular bridges, and keratohyalin granules.^[12] (WHO 2016). Although squamous features are present in Urothelial carcinoma variants with mixed histology, the definition of SCC or pure SCC is reserved for tumors that only contain squamous components without any evidence of urothelial components.^[13] In this case in spite of repeated processing and sectioning no evidence of Urothelial carcinoma was found.

SCC has a preference for the trigone region, but may also occupy any region of the bladder, including diverticula, or extend locally to the urethra or ureter. SCC tumors are rarely superficial, and early stage tumors, i.e. Ta and T1 tumors, are uncommonly encountered.

Pathological prognostics of SCC include tumor stage, grade, Lymphovascular invasion, and presence of Lymph Node involvement. A recent analysis of all stage III and stage IV bladder cancer cases in Ontario, Canada, noted that whilst the disease course of SCC was more rapid compared to TCC, the 5-year overall survival (OS) of SCC was equivalent to TCC after adjusting for covariates. Radical cystectomy and urinary diversion is the standard treatment of SCC of the urinary bladder.

Reference

1. Grignon DJ, Ro JY, Ayala AG, et al. Primary adenocarcinoma of the urinary bladder. A clinicopathologic analysis of 72 cases. *Cancer*. 1991 Apr 15; 67(8):2165-72.
2. Wang HL, Lu DW, Yerian LM, et al. Immunohistochemical distinction between primary adenocarcinoma of the bladder and secondary colorectal adenocarcinoma. *Surg Pathol*. 2001 Nov; 25(11):1380-7.
3. Ghoneim M.A., Abdel-Latif M., el-Mekresh M. et al. Radical cystectomy for carcinoma of the bladder: 2720 consecutive cases 5 years later. *J Urol*. 2008; 180:121–127
4. Bates AW, Baithun SI. Secondary neoplasms of the bladder are histological mimics of nontransitional cell primary tumours: clinicopathological and histological features of 282 cases. *Histopathology*. 2000 Jan; 36(1):32-40.
5. Melicow MM. Tumors of the urinary bladder: a clinicopathological analysis of over 2500 specimens and biopsies. *J Urol*. 1955 Oct; 74(4):498-521.
6. Epstein JI, Amin MB, Reuter VE. *Glandular Lesions. Biopsy Interpretation of the Bladder*. 2nd edition. Philadelphia, PA: Lippincott Williams; 2010. pp. 180–213.
7. Ghoneim MA, Abdel-Latif M, el-Mekresh M, et al. Radical cystectomy for carcinoma of the bladder: 2,720 consecutive cases 5 years later. *J Urol*. 2008 Jul; 180(1):121-7
8. Silver SA, Epstein JI. Adenocarcinoma of the colon simulating primary urinary bladder neoplasia. A report of nine cases. *J Surg Pathol*. 1993 Feb; 17(2):171-8.
9. Ghoneim M.A., el-Mekresh M.M., el-Baz M.A., et al. Radical cystectomy for carcinoma of the bladder: critical evaluation of the results in 1026 cases. *J Urol*. 1997; 158:393–399.
10. Rausch S., Lotan Y., Youssef R.F. Squamous cell carcinogenesis and squamous cell carcinoma of the urinary bladder: a contemporary review with focus on nonbilharzial squamous cell carcinoma. *Urol Oncol*. 2014;32 32.e11-6.
11. Khan M.S., Thornhill J.A., Gaffney E., et al. Keratinising squamous metaplasia of the bladder: natural history and rationalization of management based on review of 54 year's experience. *Eur Urol*. 2002; 42:469–474.
12. Manunta A., Vincendeau S., Kiriakou G., et al. Non-transitional cell bladder carcinomas. *BJU Int*. 2005; 95:497–502.
13. Izard J.P., Siemens D.R., Mackillop W.J., et al. Outcomes of squamous histology in bladder cancer: a population-based study. *Urol Oncol*. 2015;33 425.e7-13.

*Corresponding author:

Dr Meenu Gupta, Flat no 6D, Shikharjunj Appts, 3 Canal East Road, Near Kolkata Station, Kolkata(India) -700067,

Phone: +91 8447698465

Email: drmeenu43@gmail.com

Financial or other Competing Interests: None.

Date of Submission : 21.04.2017

Date of Acceptance : 08.08.2017

Date of Publication : 23.12.2017