



## Rhino-Orbito-Cerebral Mucormycosis

Urshlla Kaul, Prabhakar Patro, Amruta Padhye and Reeta Dhar

Dept of Pathology, MGM medical college and hospital, Navi Mumbai (India)

### Dear Sir,

Mucormycosis is a sporadic opportunistic infection occurring in patients with serious underlying diseases like diabetes, acute leukemia and patients on steroids or cytotoxic drugs.<sup>[1]</sup> Several clinical forms are recognized. Rhinocerebral mucormycosis is a fulminant infection of the nasal cavity, paranasal sinuses and soft tissues of the orbit. The infection spreads rapidly from sinus to orbit, cavernous sinus, and cranium, and if not diagnosed early and treated promptly, results in death.<sup>[2][5]</sup>

A 38 year old female presented with headache, vomiting, 2 episodes of seizures, fever, right side exophthalmos, loss of vision, periorbital swelling with uncontrolled diabetes mellitus. She also had a non-healing ulcer on the right foot. MRI revealed orbital cellulitis and fungal sinusitis with spread to the brain. Endoscopy revealed black colonies in right Ethmoidal and maxillary sinuses spreading to the left sinuses. A pus swab and sinus mucosal tissue was first sent to the microbiology lab, which revealed Mucormycosis after preparing KOH mount, SDA (Sabouraud's dextrose agar) and LPCB mount (Lactose phenol cotton blue). The patient was operated, right total orbital exenteration was done. We received 4 specimens for histopathology - tissue from nasal mucosa, right sided total orbital exenteration, orbital apex tissue and bony tissue from maxilla. On the postero-medial surface of the exenteration, just beside the optic nerve, a black area was observed in the periorbital fat. Microscopically, broad, hyaline, nonseptate hyphae, branching at right angles were seen on H&E (hematoxylin and eosin stain) which was confirmed by GMS (Gomori's methenamine silver stain). Hyphae were found in the nasal mucosal tissue, lateral rectus muscle, periorbital fat and sclera. Neural invasion was seen. Scleral tissue also showed necrosis with chronic inflammatory infiltrate. In spite of treatment, the patient developed post-operative hemiplegia and died.

Mucor is a saprophytic fungus of the class of Zygomycetes. They are saprophytes of soil, manure, bread mold and decaying vegetables. Normally a virulent, mucor can cause disease only when immunity is very low – as in cases of diabetic ketoacidosis, poor glycemic control, immune-suppression, acute leukemia or lymphoma, or on chemotherapy. The primary infection is in the upper respiratory tract and the nose<sup>[3]</sup>. Then it spreads

to the turbinate bone, paranasal sinuses, orbit, eyes and breaks the cribriform plate to reach the brain.<sup>[3]</sup> Rhino-orbital mucormycosis is an aggressive, angioinvasive fungal infection which is seen in immunocompromised hosts. It is the 3<sup>rd</sup> most common fungal infection in India following Candidiasis and Aspergillosis. Rhino-Orbital Mucormycosis (ROM) is a rare disease with an overall prevalence in 0.15% of the diabetics. Death may occur within two weeks in untreated or unsuccessfully treated patients. The fungus belongs to the Phycomycetes class, whose most common genera are *Mucor*, *Rhizopus*, *Absidia* and *Basidiobolus*. Types of mucormycosis based on the site are Rhinocerebral, Pulmonary, Cutaneous, Gastrointestinal. The infection spreads along the vascular and neuronal structures and it infiltrates the walls of the blood vessels. It causes erosion of the bony walls of the ethmoid sinuses and it may spread into the orbit and the retro-orbital area and in the brain (cerebro-rhino-orbital mucormycosis). Death may occur due to the cerebral abscesses.<sup>[4]</sup>

The identification of risk factors, clinical features, and radiological findings increases the possibility of an early diagnosis, which may prevent progressive tissue invasion, reduce the need and/or extent of surgical resection, and improve survival. However, clinical features and imaging studies are non-specific. Definite diagnosis requires demonstration of characteristic hyphae in tissue or recovery of the organism in the culture. Yield of organisms in culture is sub-optimal. Hence, histopathological examination plays a critical role in establishing the diagnosis and provides evidence of tissue invasion.

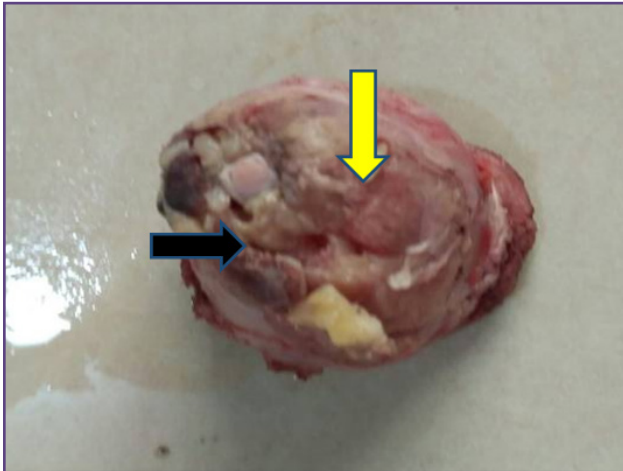
### Acknowledgements

Department of medicine, Department of Ophthalmology, Microbiology, MGM medical college and hospital.

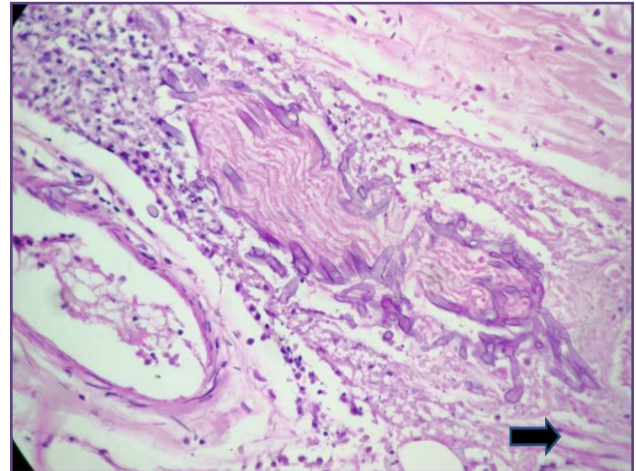
### References

1. Lehrer RI, et al.: Mucormycosis, Ann. Intern. Med. 93:93, 1980.
2. Walsh TJ, Gamaletsou MN, McGinnis MR, Hayden RT, Kontoyiannis DP. Early clinical and laboratory diagnosis of invasive pulmonary, extrapulmonary and disseminated mucormycosis (zygomycosis). Clin Infect Dis 2012;54Suppl 1:S55-60.
3. Textbook of Microbiology; 3rd edition, Prof. C. P. Baveja, Chapter 66, pg{549-550}

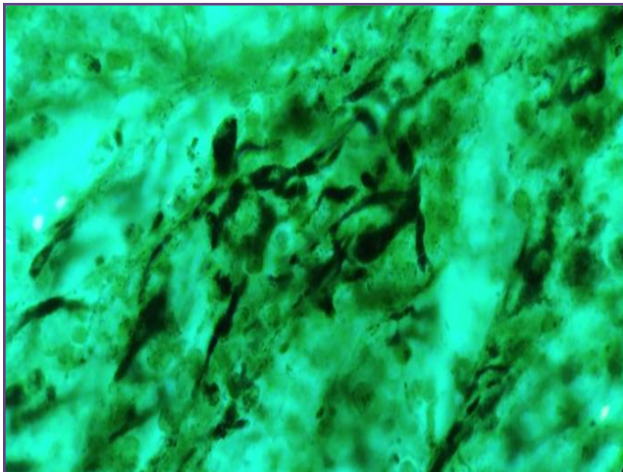




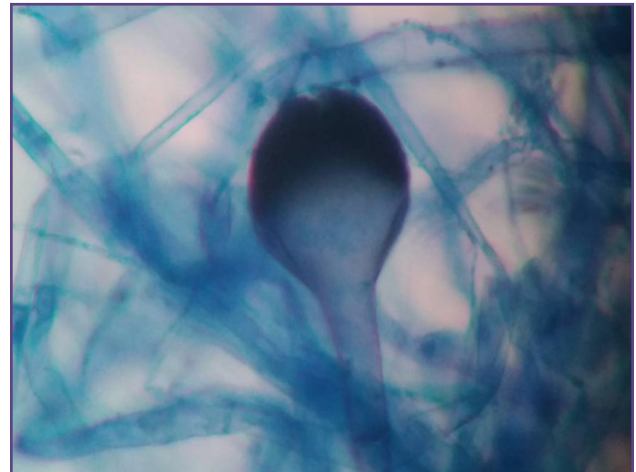
**Fig. 1: GROSS** – Postero-medial surface of exenteration showing a black area (black arrow) beside the cut margin of the optic nerve (yellow arrow).



**Fig. 2: H&E stain (40x)** Broad, nonseptate, right angle branching (black arrow) within and around a nerve bundle. Necrosis and lymphocytic infiltrate also seen.



**Fig. 3: GMS stain (100x)** – broad, nonseptate hyphae in black along with sporangia. Fibrocollagenous tissue is seen in green.



**Fig. 4: LPCB mount (100x)** – A Sporangium filled with sporangiospores on a background of broad hyphae.

4. Ravindra V. Shinde, Geeta S. Karande, S.T. Mohite, S.R. Patil, .RHINO-ORBITAL MUCORMYCOSIS IN DIABETES MELLITUS. *Journal of Clinical and Diagnostic Research* [serial online]2013 Jun 6 1145 - 1147

5. Sravani T, Uppin SG, Uppin MS, Sundaram C. Rhinocerebralmucormycosis: Pathology revisited with emphasis on perineural spread. *Neurol India* [serial online] 2014

**\*Corresponding author:**

**Dr. Jyoti Mishra**, Assistant Professor, Department of Pathology, School of Medical Sciences and Research, Sharda Hospital, Knowledge Park-III Greater Noida, Uttar Pradesh, India-201306

**Phone:** +91 0120-2329700

**Email:** drm714@gmail.com

**Financial or other Competing Interests:** None.

**Date of Submission :** 18.06.2017

**Date of Acceptance :** 19.07.2017

**Date of Publication :** 23.12.2017