

Isolated Tuberculosis of Gall Bladder: A Rare Case Report

Roma N Rajdeo*, Ravi N Rajdeo², A P Bakshi and A V Shrikhande

Dept. of pathology, Indira Gandhi Govt. Medical College, Nagpur, Maharashtra, India

Dept. of Radiology, Govt. Medical College, Nagpur, Maharashtra, India

ABSTRACT

Gastrointestinal tuberculosis is commonly seen in the form of tuberculous peritonitis or involvement of the abdominal lymph nodes. Isolated gallbladder tuberculosis is very rare worldwide, with only 50 cases reported in the literature till 2003. We report a case of a 65 years old male patient who presented with clinical features of chronic calculous cholecystitis. Radiological investigations showed a necrotic mass within fundus with thickened wall of gallbladder along with a calculus suggesting possibility of carcinoma of gallbladder. Laparoscopic cholecystectomy was done and histopathological examination revealed tuberculosis of gallbladder. This case highlights the need to be aware of such unusual presentation of tuberculosis in endemic areas and in patients with chronic gastrointestinal tract symptoms.

Keywords: Gallbladder Tuberculosis, Granulomatous Cholecystitis, Calculous Cholecystitis

Introduction

Abdominal tuberculosis is common in developing countries, but gallbladder involvement is extremely rare^[1]. The diagnosis of gallbladder tuberculosis is often not suspected prior to surgery or a biopsy^[1]. Cholelithiasis is a common association of both tuberculosis and malignancy of gallbladder. Their clinical presentations also mimic each other^[2]. Pre-operative diagnosis of gallbladder tuberculosis is difficult, more so in calculous cholecystitis, as most of the symptoms are attributed to gall stones. And post-operative persistence of symptoms due to tuberculosis is sometimes misdiagnosed as the 'post-cholecystectomy syndrome'^[2]. A high level of awareness and appropriate investigations should allow early diagnosis and proper treatment.

Case report

A 65 years old male patient presented to surgery out-patient department with complaints of recurrent attacks of right hypochondrial pain since 6 months. Pain was localized and intermittent with increase in intensity on eating spicy and fatty food. He suffered loss of appetite, occasional vomiting and low grade fever with evening rise of temperature. There was no history of clay colored stools, jaundice, itching, haematemesis or melaena. A day before admission patient had severe pain, fever, abdominal distension. There was no past history of tuberculosis or contact with tuberculosis patient. Our patient was of low socio-economic status.

On examination, he had pallor and wasting. There was no lymphadenopathy. Abdomen was distended, soft and tender in right hypochondrium with ascites. Bowel sounds were frequent and digital per rectal examination was unremarkable. Cardiovascular, respiratory and central nervous system examination showed no abnormality. A

provisional clinical diagnosis of chronic cholecystitis was made. Other possible differential diagnoses included were pancreatitis, ascending cholangitis and hepatitis.

On investigations, hemoglobin was found to be low (9.9gm/dl), PCV 28.7%, total leukocyte count was 8600cells/mm³ with reactive neutrophilia, normal platelet count with microcytic hypochromic anemia. ESR was 26mm at 1hr. Liver function tests, renal function tests, pancreatic function tests, serum electrolytes and coagulation profile of the patient were within normal limits. Ascitic fluid was negative for malignant cells. Chest x-ray revealed no abnormality. Abdominal ultrasonography showed a necrotic mass within fundus with thickened wall of gallbladder along with a calculus suggesting possibility of carcinoma of gallbladder along with moderate ascites. CT abdomen revealed over distended sludge filled gallbladder with a calculus of 3.5cm diameter, irregular gallbladder wall with maximum thickness of 7mm, moderate to gross ascites and pericholecystic fluid collection (Figure 1). Diagnosis of calculous cholecystitis was made and laparoscopic cholecystectomy was done. We received a gallbladder of size 7x4 cm filled with necrotic material and a calculus of size 3.5 cm diameter with thickened gallbladder wall. On microscopic examination, thickened fibrotic wall with multiple caseous granulomas comprising of caseous necrosis, epithelioid cells, langhans and foreign body type giant cells were found (Figure 2A, 2B). Ziehl-neelsen stain was found to be positive for acid fast bacilli (bacterial load was 12-13bacilli/OIF) confirming the diagnosis of tuberculous cholecystitis (Figure 2B inset). However, auramine rhodamine stain and immunofluorescence could not be performed. Mantoux test done retrospectively after histopathological examination was found to be positive.

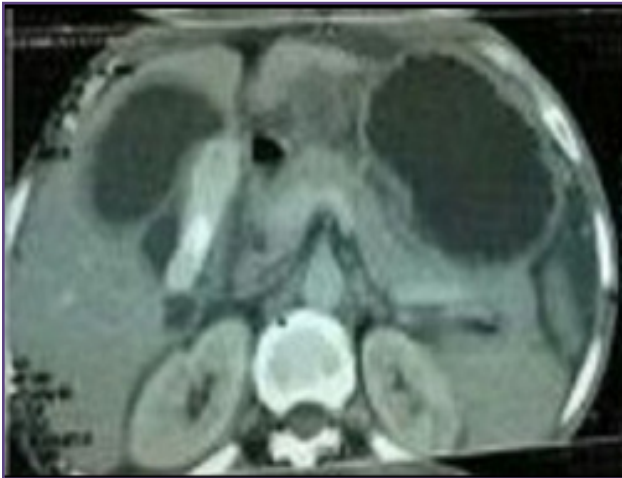

Fig. 1: CT abdomen showing distended sludge filled gall bladder with a calculus of 3.5cm diameter.

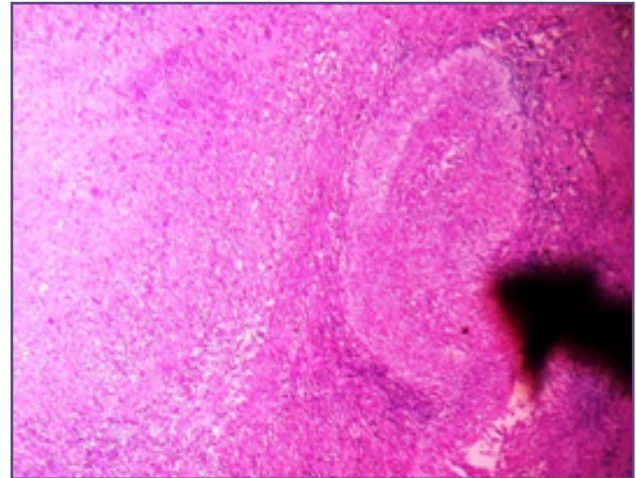


Fig. 2A (H & E stain, 10X): thickened fibrotic wall with granuloma (black arrow) comprising of caseous necrosis.

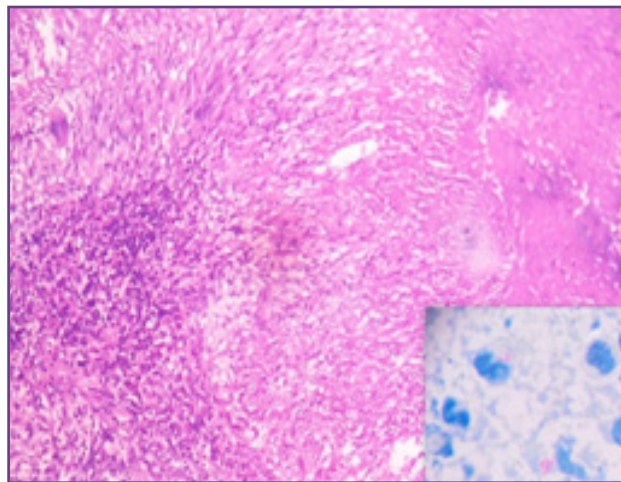


Fig. 2B (H & E stain, 40X): Granuloma comprising of caseous necrosis, epithelioid cells, giant cells and lymphocytic infiltrate. Inset (ZN stain, 100X) shows acid fast tubercular bacilli.

Discussion

Tuberculosis of the gallbladder was originally described by Gaucher in 1870. Over a century later, Bergdahl reported 41 cases of this condition which remains uncommon, even in areas with a high incidence of tuberculosis [3]. Gastrointestinal tuberculosis is commonly seen in the form of tuberculous peritonitis or involvement of the abdominal lymph nodes. Gallbladder tuberculosis is very rare worldwide, with only 50 cases reported in the literature till 2003 [4]. It occurs most commonly in women over 30 years of age [5,6] and cholelithiasis is associated in more than 70% of cases [4]. According to Sir BOA Moynihan, “a gall stone is a tomb-stone erected to the memory of the organism within it”. Infecting organism reaches gallbladder via blood stream or lymphatics from a focus nearby [2]. Mycobacteria can also be a cause of

cholelithiasis and/or cholecystitis, particularly when tuberculosis is disseminated to the peritoneum and lymph nodes in the vicinity. The rarity of tuberculous involvement of gallbladder could be due possibly to hypovascularity of gallbladder sac and high alkalinity of concentrated bile inside it. Isolated tuberculosis of gallbladder has also been reported but without any direct evidence of its primary involvement [2]. Our case had no evidence of tuberculosis elsewhere with no any past history of tuberculosis and can be assumed to be primary gallbladder tuberculosis. When the bacilli travel by ascending infection through the biliary passages, they form a nidus for the stone formation. Around the bacilli, multiple layers are laid down which leads to the formation of the stone. Also, the bile becomes infected with the presence of the bacilli. It has been suggested that cystic duct obstruction leads to the disappearance of the

bile acids from the gallbladder and to a lowered resistance against tuberculous bacilli [7]. Cholelithiasis and cystic duct obstruction are considered the most important factors in the development of gallbladder tuberculosis [1]. Isolated gallbladder tuberculosis has been reported on a few occasions, mostly in adult patients [8,9]. It has also been shown to occur following military tuberculosis [10]. It may be due to the secondary spread from the distant foci or direct extension from neighborhood lesions. Absence of tubercles on gallbladder mucosa indicates hematogenous or lymphatic spreading, whereas tubercles mainly located on the mucosa suggest canalicular dissemination. Tubercles scattered over the serous layer of the gallbladder suggest spreading from peritoneal cavity [11,12]. Review of the role of ultrasound in the detection of hepatobiliary disease showed that the presence of gallbladder wall thickening and sludge, when coupled with right upper quadrant pain and normal liver function tests, correlates with a significant incidence of intrinsic pathology of the gallbladder [13,14].

Conclusion

The incidence of abdominal tuberculosis is increasing and the familiarity with its clinical presentation shortens its diagnostic time and improves its management. As tuberculous cholecystitis is difficult to diagnose and most cases are diagnosed post cholecystectomy or at post-mortem, all resected cholecystectomy specimens should be sent for histopathological examination for evidence of tuberculosis.

References

1. Akhtar K, Zaheer S, Ahmad SS, Mansoor T. Gall bladder tuberculosis. *Ann Trop Med Public Health* 2009;2:61-2
2. Mukherjee S, Ghosh AK and Bhattacharya U. Tuberculosis of gall bladder - problem of diagnosis. *Ind. J. Tub.* 2001;48,151
3. Cheddie S, Bisetty T, Singh B. Isolated Tuberculosis of the Gallbladder. *The Internet Journal of Surgery.* 2012 Volume 28 Number 2
4. Kapoor S, Sewkani A, Naik S, Sharma S, Jain A, Varshney S. Myriad presentations of gall bladder tuberculosis. *Indian J Gastroenterol* 2006;25:103-4
5. Abu-Zidan FM, Zayat I. Gallbladder tuberculosis: case report and review of the literature. *Hepatogastroenterology* 1999;46:2804-6
6. Duan JG, Liu CL, Chen Y. One case of gall bladder tuberculosis. *Clin J Radiol* 1992;26:379-80
7. Pandya JS, Palep JH, Shinkre NB, Patil NN, Palan VA. Primary biliary tuberculosis - an unusual case. *Indian J Surg* 2003;65:440-1
8. Bergdahl L, Boquist L. Tuberculosis of the gallbladder. *British Journal of Surgery* 1972;59(4):289-92
9. Patel MR, Tharkore V, Rajput AR, et al. Chronic tuberculous cholecystitis. *Tropical Doctor* 1995;25(1):33
10. Piper C, Gamstatter G, Bettendorf U, et al. Gallbladder tuberculosis. Review and case report of a patient with advanced renal failure. *Leber, Magen, Darm* 1987;17(6):381-6
11. Misgar MS, Kariholu PL, Bhat DN, Fazili F, Yousuf M, Muhajid S. Tuberculosis of gallbladder. *J Med Indian Assoc* 1980;74:196-7
12. Tobias H, Sherman A. Hepatobiliary tuberculosis. In: Rom WN, Garay SM, eds. *Tuberculosis*. Boston: Little Brown, 1996:599-607
13. Tsakayannis DE, Kozakewich HPW, Lillehei CW. Acalculous cholecystitis in children. *Journal of Paediatric Surgery* 1996;31(1):127-31
14. Jennings WC, Drabek GA, Miller KA. Significance of sludge and thickened wall in ultrasound evaluation of the gallbladder. *Surgery, Gynaecology and Obstetrics* 1992;174(5):394-8

*Corresponding author:

Dr. R. N Rajdeo, C/O Dr. Jitin Bajaj, 8/8 Kalkajiextension, Near Apna park, Nehru place, New Delhi, India 110019

Phone: +91 7694959651

Email: roma.rajdeo@yahoo.com

Financial or other Competing Interests: None.

Date of Submission : 14.07.2017

Date of Acceptance : 24.10.2017

Date of Publication : 13.01.2018