

Pleural Effusion Obscuring Pulmonary Echinococcosis: Diagnosis by Cytology

Anshu Jain, Veena Maheshwari, Divya Rabindranath*, Kashmi Sharma

Department of Pathology, J.N.Medical College, A.M.U., Aligarh, India

Keywords: *Echinococcus, Pleural Effusion, Hydatid Cyst, Cytology*

ABSTRACT

Echinococcosis or hydatid disease, caused by larvae of the tapeworm *Echinococcus*, is frequently seen in an endemic country like India. A single organ is involved in 85-90% cases, pulmonary involvement occurs in 10 - 30% of cases, being second only to the hepatic involvement. Besides anaphylactic reactions a pulmonary hydatid cyst may be complicated by rupture into neighbouring structures like bronchi and pleural cavity with or without infection. We report an unusual case of ruptured hydatid disease in pleural cavity rarely seen in adults diagnosed by fine needle aspiration cytology. A 45 year old male came to our emergency department in shock with symptoms of shortness of breath and altered mental status from the previous day. Radiograph showed massive left sided pleural effusion and therapeutic aspiration was done. Pleural fluid cytology showed few hydatid scolices. Serum echinococcal antigen was also tested to be positive. CT scan revealed pleural effusion with multiple air pockets and pleural thickening on left side, and loculated cyst with septae on right side, thereby confirming the diagnosis as active pulmonary hydatid cyst with rupture into the pleural cavity, which is not a common finding in adult population.

Hydatid cyst rupture should be considered in the differential diagnosis of cases with pleural effusion. Rupture of a pulmonary hydatid cyst into the pleural cavity is rare, but represents the most serious complication of the hydatid disease. In regions where echinococcal disease is endemic, a high level of clinical suspicion is necessary for diagnosis and appropriate management of this condition.

***Corresponding author:**

Dr. Divya Rabindranath, Department of Pathology, J.N.Medical College, A.M.U., Aligarh, U.P., India. 202001.

Phone: +91- 7895683197

E-mail: divy30@hotmail.com



Introduction

Human Echinococcosis is a serious helminthic disease affecting endemic areas being Mediterranean countries, South Africa, Australia, New Zealand and Central Asia including India.^[1] Most common form of disease found in humans is called as unilocular Echinococcosis caused by *Echinococcus granulosus*.^[2] The next common being Alveolar Echinococcosis caused by *Echinococcus multilocularis* followed by Polycystic Hydatid disease caused by *Echinococcus vogeli* and rarely *Echinococcus oligarthus*. Disease can involve any part of the body but seen most commonly in liver and lungs. Manifestation of the disease depends on location in the body. Pulmonary Echinococcosis is seen rarely in adults and usually remains asymptomatic until the time of rupture. Rupture of pulmonary cyst into the pleural cavity is rare, but represents the most serious complication of the hydatid disease. The incidence of rupture is found to be more frequent in children and reported to be 26.7% in one series.^[3] Ruptured hydatid cyst poses a diagnostic challenge as radiographic picture is highly varied. It is diagnosed usually by imaging, histological, cytopathological and serological techniques. Surgery with postoperative anthelmintic therapy is the treatment of choice, and a close follow-up is required.

Case Report

A 45 year old male came to our emergency department in shock with symptoms of shortness of breath and altered mental status from the previous day. There was no history suggestive of bronchial asthma, drug intake, allergy or chest trauma. His blood pressure was 80/60 mm Hg, heart rate 128 beats/min, respiratory rate 42 breaths/min, and temperature 38.5°C. Investigations revealed Hb of 11.1gm%, total leucocyte count of 19,280 cells /cumm, (P72, L17, M1, E10, B0). ESR was 110mm/hr. Radiograph showed massive left sided pleural effusion with right sided round well circumscribed non homogenous opacity suggestive of loculated pleural effusion (Fig.1). Therapeutic aspiration was done. Pleural fluid examination revealed total leucocyte count to be 550cells/cumm, and eosinophilia. Cytology showed hydatid scolices with neutrophils in the background (Fig.2). Immunoglobulin-G enzyme-linked immunosorbent assay for *Echinococcus* was positive. CT scan revealed massive left sided pleural effusion with shift of mediastinum to contralateral side with basal pleural thickening and floating lily sign. Right lung also showed a round well circumscribed fluid filled cystic lesion with multiple septations suggestive of multiple daughter cysts and basal hydatid sand (Fig.3). Ultrasound abdomen was suggestive of normal study with no involvement in liver, thereby confirming the diagnosis of primary bilateral hydatid lung disease with rupture into the pleural cavity on the left side, which occurs rarely in the

adult population. Patient was started on albendazole 400mg twice a day for 6 cycles of 4 weeks each with 2 weeks drug free interval between the cycles since then and follow up was done every 3 monthly for 1 year with serial radiological and clinical examinations, during which the patient remained asymptomatic and showed no signs of recurrence.

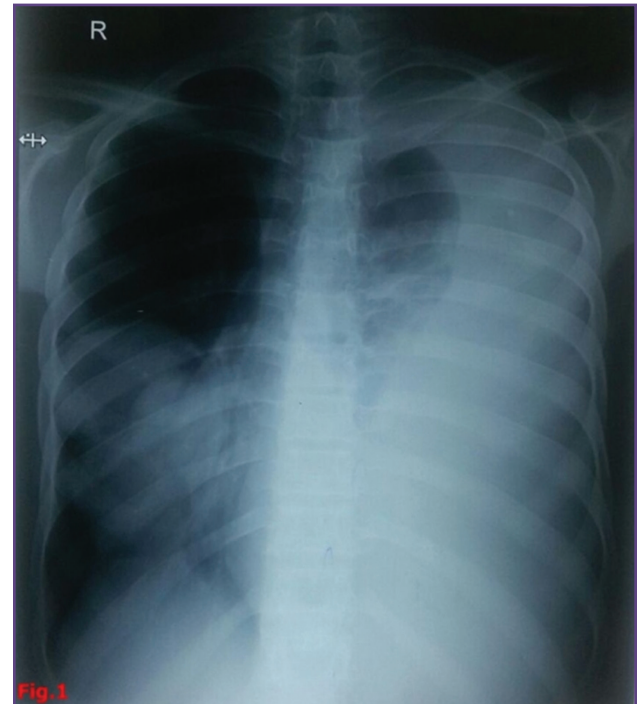


Fig.1: Radiograph showing massive left sided pleural effusion with right sided round well circumscribed non homogenous opacity suggestive of loculated pleural effusion.

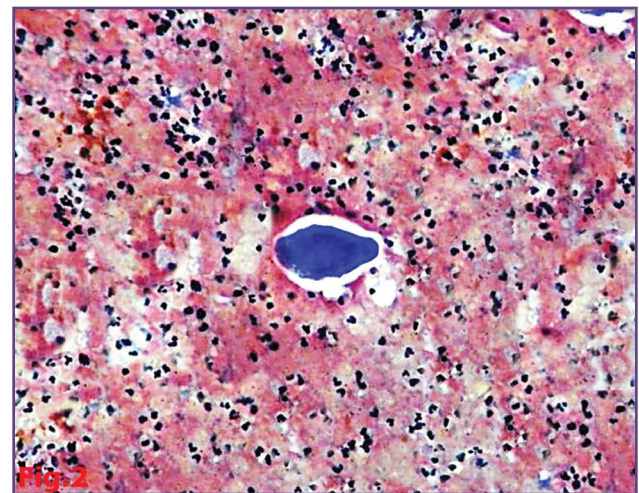


Fig. 2: Pleural fluid smear showing hydatid scolice with neutrophils in the background (H&E, 40x)

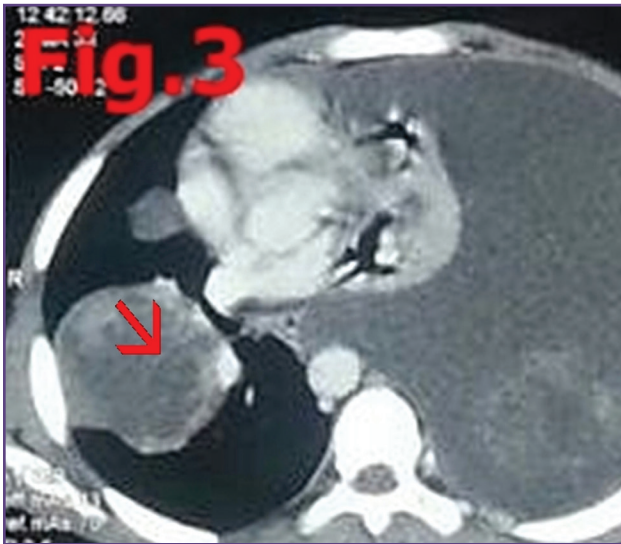


Fig. 3: CT scan showing massive left sided pleural effusion with shift of mediastinum to contralateral side with basal pleural thickening and floating lily sign (yellow arrow) and round well circumscribed fluid filled cystic lesion with multiple septations (red arrow) suggestive of multiple daughter cysts and basal hydatid sand on the right side.

Discussion

Cystic hydatid disease or Echinococcosis is a zoonotic disease affecting humans by ingestion of food or water contaminated with eggs of echinococcal species, or by direct contact with infected dogs or canines. Most common involved species is *Echinococcus granulosus*.^[2] Rarely infection can be caused by *Echinococcus multilocularis*, *Echinococcus oligarthus*, *Echinococcus vogeli*. Hydatid disease is endemic in Eurasia, North East Africa, Australia and South America.^[1] For *Echinococcus granulosus*, dogs act as definitive hosts which harbor adult tapeworm, and shed eggs containing larval stage (metacestode). Infection is transmitted to intermediate host (most commonly sheep) by ingestion of eggs and to humans as accidental intermediate hosts.

Disease in man is characterised by benign slowly growing cysts most commonly seen in liver (50-70%), lungs (20-30%), spleen, rarely in pleural cavity, kidney, spleen, bone, heart, CNS and other organs.^[4] Pulmonary hydatidosis is rare in adults and usually asymptomatic, though patients may present with cough, dyspnea, hemoptysis due to mass effect of the cysts exerting pressure on surrounding tissues. Appearance of new symptoms or exaggeration of existing ones may follow complications of the disease. Most often complicated by cyst rupture leading to flow of larval tissue fragments and protoscolices into bronchial tree causing chest pain, fever and hemoptysis. Rupture into

pleural cavity may occur causing pleural effusion, simple or tension pneumothorax,^[3] empyema and anaphylactic shock,^[5] due to release of antigenic material as in our case. Other complications can be secondary bacterial infections or development of secondary lesions in surrounding tissues. Ruptured and infected hydatid cysts are often confused with pneumonia, tuberculosis, lung abscess, tumor, or pneumothorax.^[3] But the radiological, cytological and serological tests can help us in confirming the diagnosis.

Diagnostic interventions include imaging, histopathological, cytological examination and confirmation by serology. A spectrum of cytomorphological features of hydatidosis can be seen on FNAC smears including scolices, lamellated wall, hooklets, eosinophils and sometimes charcot laden crystals.^[6] Present case was diagnosed with the help of FNAC, which is usually discouraged in suspected hydatid disease due to risk of anaphylaxis. On X-ray “meniscus sign”, spherical cyst, blunting of CP angle,^[7] and on CT scan “water lily sign”, large cystic lobulated structures containing multiple daughter vesicles or membranes, septa, hydatid sand,^[8] and recently discovered “air bubble sign” aids in establishing diagnosis of perforated pulmonary hydatid cyst, as also seen in our case. Release of parasitic antigens in presence of complications relate to positive serological diagnosis and supports clinical diagnosis of ruptured cystic echinococcosis. Quantitative serodiagnostic methods like Immunoglobulin G enzyme-linked immunosorbent assay (ELISA) test with sensitivity of 85.3% can be used which are commercially available.^[9] When feasible early surgery is the treatment of choice for pulmonary hydatidosis to prevent eventual rupture. In perforated cases medical therapy with albendazole is given as a complement to surgical treatment, to avoid recurrence, and in patients who cannot undergo surgery.^[10]

Conclusion

We report this case of ruptured pulmonary hydatid cyst in pleural cavity for its unusual presentation, usually rare in adults and to emphasize the role of FNAC as an extremely useful, cost effective and safe tool in diagnosing the disease. Thus hydatid cyst rupture should be suspected in patients presenting as pleural effusion, from areas where *Echinococcus* is endemic, as it represents the most endangered life threatening complication of hydatid disease.

Acknowledgements

nil

Funding

none

Competing Interests

None declared

Reference

1. S Gole, G Gole, V Satyanarayana. Unusual Presentation of Hydatid Cyst: A Case Series With Review of Literature. *The Internet Journal of Parasitic Diseases*. 2013; 6 (1).
2. Goyal P, Ghosh S, Sehgal S, et al. Primary Multilocular Hydatid Cyst of Neck with Unique Presentation: A Rare Case Report and Literature Review. *Head and Neck Pathology*. 2014;8:334-338.
3. Balci AE, Eren N, Eren S, and Ulka R. Ruptured hydatid cysts of the lung in children: clinical review and results of surgery. *Annals of Thoracic Surgery*. 2002; 74 (3): 889-892.
4. Gottstein B, Reichen J. Hydatid lung disease (echinococcosis/hydatidosis). *Clin. Chest Med*. 2002; 23 (2): 397-408.
5. Aribas OK, Kanat F, Gormus N and Turk E. Pleural complications of hydatid disease. *Journal of Thoracic and Cardiovascular Surgery*. 2002; 123 (3): 492-497.
6. Goyal P, Sehgal S, Ghosh S, Mittal D, Kumar A, Singh S. A Cytological Study of Palpable Superficial Nodules of Parasitic Origin: A Study of 41 Cases. *Pathology Research International*. 2014;2014:373472. doi:10.1155/2014/373472.
7. Rai SP, Panda BN, Ganguly D, Bharadwaj R. Pulmonary hydatid: diagnosis and response to hypertonic saline irrigation and albendazole. *Med J Arm Forces India*. 2005; 61 (1): 9-12.
8. Safioleas MC, Misiakos EP, Kouvaraki M, Stamatakos MK, Manti CP, Felekouras ES. Hydatid Disease of the Liver A Continuing Surgical Problem. *Arch Surg*. 2006; 141: 1101-8.
9. Niscigorska J, Sluzar T, Marczevska M, et al. Parasitic cysts of the liver: practical approach to diagnosis and differentiation. *Med Sci Monit*. 2001; 7: 737-41.
10. Fanne RA, Khamaisi M, Mevorach D, Leitersdorf E, Berkman N, Laxer U, et al. Spontaneous rupture of lung echinococcal cyst causing anaphylactic shock and respiratory distress syndrome. *Thorax*. 2006; 61: 550.