

Cytology: A Diagnostic Modality in Cryptococcal Lymphadenitis

Pooja Srivastava, Kusum Gupta, Rashmi Arora,

Department of Pathology VMMC and Safdarjung Hospital, New Delhi, India

Keywords: *Cryptococcus, Cytology, Lymphadenitis, Fungus*

ABSTRACT

Cryptococcosis is a common, life-threatening, opportunistic, fungal disease in human immunodeficiency virus (HIV) infected individuals. A prompt diagnosis is of utmost importance because disseminated cryptococcal infection is life-threatening. Different organs can be involved, but involvement of lymph node is a rare feature. We here present a case of cryptococcal lymphadenitis diagnosed on fine needle aspiration cytology.

***Corresponding author:**

Dr Pooja Srivastava, 270, Hauz Rani Malviya Nagar, New Delhi, India 110017

Phone: +91- 9015354141

E-mail: panacea.2417@gmail.com



Introduction

Cryptococcosis is a common opportunistic fungal disease seen in human immunodeficiency virus (HIV) infected individuals. It is caused by the encapsulated yeast *Cryptococcus neoformans*.^[1] Usually affected sites include respiratory and central nervous system. Lymph node involvement as a presenting feature is not a common manifestation of the disease.^[2] Disseminated cryptococcosis is a life-threatening disease^[3] hence a prompt and early diagnosis is mandatory. We report here a case of cryptococcal lymphadenitis that was diagnosed by fine-needle aspiration cytology (FNAC) of the involved cervical lymph node.

Case Report

A 25 year old male presented with complaints of fever, cough, generalized weakness and significant weight loss for 2 months duration. Patient was a known case of HIV infection and was on treatment. On examination, he was of thin built and had palpable cervical lymphnode measuring 1x1 cm. His systemic examinations, routine hematological as well as biochemical investigations were almost within normal limits. Based on these findings a presumptive clinical diagnosis of tuberculosis was made and fine needle aspiration from the enlarged lymphnode was performed. Giemsa stained smears demonstrated numerous spherical yeast cells of variable size surrounded by a clear halo [Figure 1] with few lymphocytes and histiocytes in a necrotic background. No epithelioid cells were seen. No acid-fast bacilli could be seen on Ziehl-Neelsen-stained smears. Periodic acid-Schiff (PAS) stain [Figure 2] was

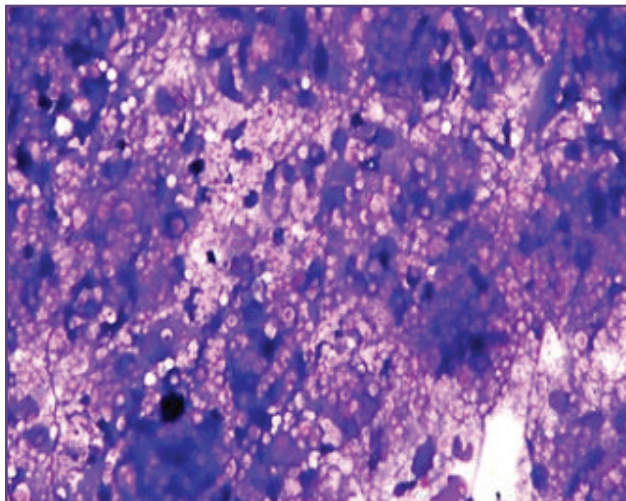


Fig. 1: Smear showing spherical, budding, encapsulated yeasts with thick (clear zone) capsule (Giemsa, 100x).

put which facilitated the identification of organism. Thus, possibility of cryptococcal infection was considered and patient was started on antifungal treatment to which he adequately responded. Patient was further followed up for two months after which he was lost to follow up.

Discussion

Cryptococcosis is a chronic opportunistic infection caused by the encapsulated yeast *Cryptococcus neoformans*.^[1] It was first described in the 1890s though its increased prevalence was reported in the early 1980s owing to HIV pandemic.^[4] *Cryptococcus* lymphadenitis is an unusual form of extrapulmonary cryptococcosis and is one of the 'AIDS defining criteria' as per Centre for Disease Control and Prevention (CDC) guidelines.^[3,5] Various cytological studies of HIV lymphadenopathy have indicated that tuberculosis is the most frequent infection occurring in HIV patients in India.^[6] The clinical presentation in the form of lymph node enlargement makes tuberculosis as the first differential diagnosis, especially because of its high prevalence in India.

The diagnosis of *Cryptococcus* can be made microscopically by demonstrating yeast cells in lymph node aspirate. The yeast cells are surrounded by a thick halo-like capsule measuring 5-15 μ m in diameter. Special stains like gomori's methanamine silver, PAS and mucicarmine can be used to facilitate the identification of organism.^[1] Although, culture is important for identification of the pathogen, diagnosis of cryptococcosis can be made on cytologically obtained smears when the mucopolysaccharide capsule is visualised with aid of special stains.^[3]

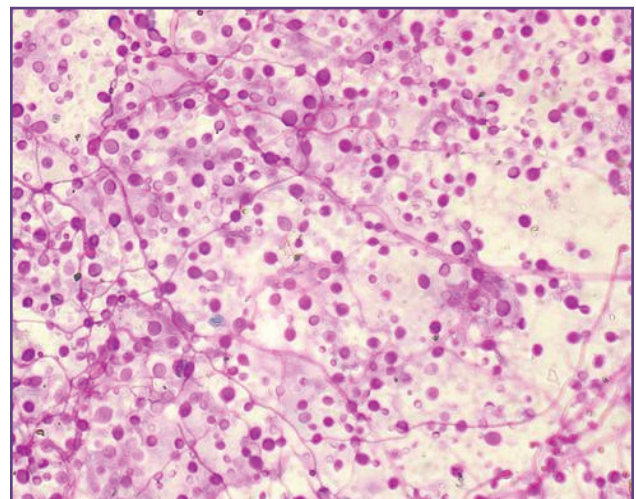


Fig. 2: Periodic acid-Schiff (PAS) stain highlighting the presence of *Cryptococcus neoformans* (PAS, 200x).

Conclusion

FNAC is a safe, simple and useful technique which can expedite an accurate and rapid diagnosis of cryptococcal lymphadenitis, thereby helping in timely initiation of treatment.

Acknowledgements

Nil

Funding

None

Competing Interests

None declared

Reference

1. Sainath AK, Ahuja M, Shaik I. Cryptococcal Lymphadenitis on Fine Needle Aspiration Cytology. People's Journal of Scientific Research 2012;5:33-5.
2. Bhuyan P, Pattnaik K, Kar A, Brahma RC, Mahapatra S. Cryptococcal lymphadenitis in HIV: a chance diagnosis by FNAC. Diagn Cytopathol 2013;41:456-8.
3. Suchita S, Sheeladevi CS, Sunila R, Manjunath GV. Fine needle aspiration diagnosis of cryptococcal lymphadenitis; A window of opportunities. Journal of Cytology 2008;25:147-9.
4. Philip KJ, Kaur R, Sangeetha M, Masih K, Singh N, Mani A. Disseminated cryptococcosis presenting with generalized lymphadenopathy. J Cytol 2012;29: 200-2.
5. Tahir M, Sharma SK, Sinha S, Das CJ. Immune reconstitution inflammatory syndrome in a patient with cryptococcal lymphadenitis as the first manifestation of acquired immunodeficiency syndrome. J Postgrad Med 2007;53:250-2.
6. Anvikar AR, Gosavi AV, Kulkarni MP, Lanjewar DN. Cytodiagnosis of coexistent cryptococcal and mycobacterial lymphadenitis in a case of AIDS. J Cytol 2011; 28:25-7.