

## Hydatid Cyst in Femur: - A Case Report

Shweta Chaturvedi\*<sup>1</sup>, Shubha Gupta<sup>1</sup>, Mansi Faujdar<sup>1</sup>, Gajendra Gupta<sup>1</sup>, Jaimini Patel<sup>1</sup>,  
Vishal Khandelwal<sup>2</sup>

<sup>1</sup>Department of Pathology, Santokba Durlabhji Memorial Hospital, Jaipur, India

<sup>2</sup>Department of Anaesthesia, JLN Medical College, Ajmer, India

**Keywords:** *Echinococcus, Hydatid Cyst, Osseous hydatidosis, Femur*

### ABSTRACT

Hydatid cyst is caused by the larva of *Echinococcus granulosus*. Its usual occurrence is in liver and lungs. Osseous hydatidosis is a rare event and is often a diagnostic challenge to the clinician. We report a case of 18 year old boy who presented with complaints of pain over left hip for past one year and subsequently whose MRI was done which suggested it the lesion to be either due to giant cell tumour or chondroblastoma. On the contrary, histopathological examination of the lesion stated it to be osseous hydatid cyst.

**\*Corresponding author:**

Dr Shweta Chaturvedi, Department of Pathology, Santokba Durlabhji Memorial Hospital, Jaipur, India

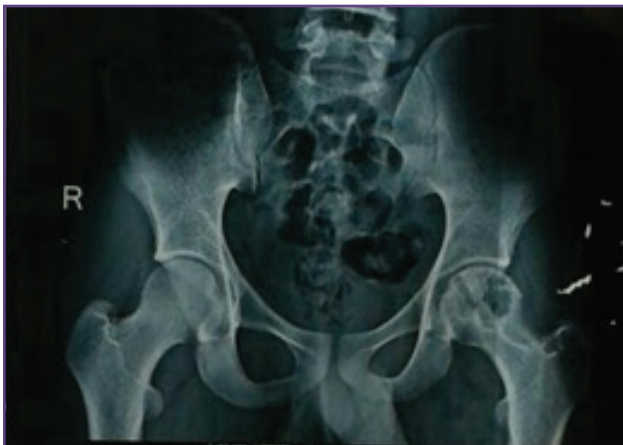## Introduction

Hydatidosis is an infectious disease caused by the parasitic tapeworm *Echinococcus*. The species most responsible for hydatid disease is *Echinococcus granulosus*, which is endemic especially in cattle raising countries. Liver (55-70%) is the most common site of hydatid disease followed by the lungs (18-35%). Bone involvement is very rare accounting for only less than 1% of the patients<sup>[1,2]</sup>, yet it is the most debilitating form of echinococcosis in humans. Intra-osseous lesions usually begin at the epiphysis and causes bone destruction through three mechanisms: compression, ischemia and osteoclast proliferation around the compressed bone tissue causing thinning and fracture and extension into soft tissues<sup>[1]</sup>.

The aim of our study is to spread awareness about the occurrence of osseous hydatid cyst so that prompt treatment could be individualized according to the site, extent and severity of involvement.

## Case Report

An 18 year old male patient presented with complaints of pain over left hip for the past one year which increased on walking and weight bearing. Clinically there was tenderness over left hip. X- Ray revealed an osteolytic lesion over neck and head of femur (fig.1).

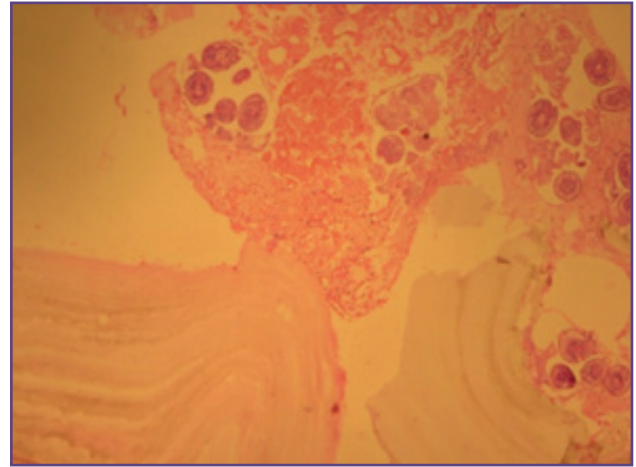


**Fig. 1: Plain radiograph showing lytic lesion over neck and head of left femur**

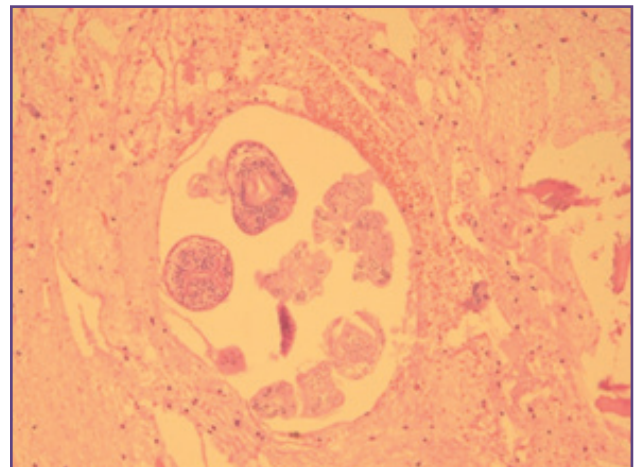
Further, MRI of hip joints was done which showed cystic / near fluid intensity areas in left femoral head and neck superolaterally with evidence of severe cortical thinning or breach along the inferolateral aspect of femoral head and superolateral aspect of neck suggesting a differential diagnosis of Giant cell tumour or chondroblastoma.

Hematological investigations showed mild eosinophilia, normocytic normochromic RBC(s) and an ESR of 8mm/hr. A Biopsy of the lesion over head of femur was done and

sent for histopathological examination which revealed a cystic lesion, with lamellated cyst wall and multiple scolex attached to the cyst wall (fig.2 & fig.3); thereby giving the final impression as hydatid cyst.



**Fig. 2: Microscopy revealing lamellated cyst wall and attached scolices (H&E, 40x)**



**Fig. 3: Higher magnification of scolex (H&E X 100).**

A sample of the lesion was also sent for microbiological examination and smears were prepared and stained with Gram Stain and Z-N stain. Gram stained smears showed few scolex of hydatid cyst while the smear of Z-N stain showed no acid fast bacilli. USG scan of abdomen was normal as well as SGOT/SGPT tests were within normal limits. Also to be noted that, Elisa test for detecting anti – *Echinococcus* studies was negative.

Patient was given a course of albendazole to subside the parasitic infection and after that surgical resection of the lesion was advised. After taking the prescribed treatment, he was operated and complete debridement of the lesion was done and the sample was sent for the

histopathological examination. Biopsy revealed fragments of mature bony tissue, lymphoplasmacytic cells and few foreign body giant cells. Also seen were fragments of a cyst wall showing lamellations suggesting the possibility of hydatid cyst.

## Discussion

Hydatid cysts caused by *Echinococcus* species can produce tissue cysts anywhere in the body. Skeletal involvement is rare, yet because of their unusual presentation diagnosis can be missed. Primary hydatid disease of the bone is infrequent because the parasites must pass the filters of the liver and lungs. The disease manifests itself differently in the bone due to the mechanical resistance that the bone offers to the growth of parasites and cysts. The lesion tends to present with pain or pathological fracture and occur in the thirty to fifty year old age group<sup>[3]</sup>. But in our case the patient was young.

The diagnosis of osseous hydatidosis is difficult and is easily overlooked unless there is a strong element of suspicion<sup>[4]</sup>. It may mimic tuberculosis, chronic osteomyelitis, simple bone cyst, sub-acute arthritis, giant cell tumours, osteosarcoma, malignant fibrous histiocytoma, myeloma and chondrosarcoma. Plain skiagram, CT, MRI remains the common modes of diagnostic tools. Fine- needle aspiration must be avoided because of the danger of spread, sensitization, and anaphylaxis<sup>[4,5,6]</sup>. However, despite all investigative measures, diagnosis is established only at surgery or biopsy of the lesions.<sup>[7],[8],[9]</sup>

The cyst microscopy shows cyst wall comprising of three layers. The innermost is the germinal layer which gives rise to brood capsules that are attached to the inner wall by a short stalk<sup>[10]</sup>. Protoscolices develop within the brood capsule and when they detach they are called daughter cysts. Cyst fluid content obtained at FNA consists of daughter cysts protoscolices. Second layer is the ectocyst which shows a laminated membrane that is avascular, eosinophilic, refractile and chitinous. The third layer is host derived and known as pericyst. It consists of dense fibrovascular tissue with inflammatory cells.

Hydatid disease in bone should be treated with radical resection, with a wide margin of the healthy tissue. This may be difficult, but incomplete removal results in recurrence.<sup>[4]</sup>

## Conclusion

The purpose of this article is to emphasize the fact that this disease should be suspected in cystic lesions affecting the bone, so that early diagnosis helps in eradication and salvage of the bone. Misdiagnosis and delayed diagnoses are always fraught with the danger of amputation, recurrence and sepsis.

## Acknowledgements

nil

## Funding

none

## Competing Interests

None declared

## References

1. Zlitini M, Ezzaoula K, Lebib H, Karray M, Kooli M, Mesteri M. Hydatid cyst of bone: diagnosis and treatment. *World J Surg*. 2001;25:75–82
2. Szypryt EP, Morris DL, Mulholland RC. Combined chemotherapy and surgery for hydatid cyst of bones. *J Bone Joint Surg Br*. 1987;69:141–4
3. Khandakar HH, Islam S, Begum B A, Khatun M, Alam M A. Hydatid disease in femur: A case report. *Dinajpur Med Col J* 2012;5:56-7.
4. Herrera A, Martinez AA. **Extraspinal bone hydatidosis**. *J Bone Joint Surg Am*. 2003;85 :1790–4.
5. Sapkas GS, Stathakopoulos DP, Babis GC, Tsarouchas JK. Hydatid disease of bones and joints. 8 cases followed for 4–16 years. *Acta Orthop Scand*. 1998;69:89-94
6. Papanikolaou A. Osseous hydatid disease. *Trans R Soc Trop Med Hyg*. 2008; 102: 233–8.
7. Tomak Y, Dabak N, Gulman B, Karaismailoglu TN, Basoglu T, Incesu L. Hydatid disease of the left femur: a case report. *Bull Hosp Jt Dis*. 2001-2002; 60:89-93.
8. Tuzun M, Hekimoglu B. CT findings in skeletal echinococcosis. *Acta Radiol*. 2002;43:533-8.
9. Yildiz K, Gurbuz Y, Buluc L, Cirpici Y. Diagnostic clues in fine needle aspiration biopsy of hydatid disease of bone. *Acta Cytol*. 2006; 50:353.
10. Goyal P, Ghosh S, Sehgal S, et al. Primary Multilocular Hydatid Cyst of Neck with Unique Presentation: A Rare Case Report and Literature Review. *Head and Neck Pathology*. 2014;8:334-8.