

Tumor or Gossypiboma

Pankaj Gupta*, Shruti Chaudhary, Noopur Gupta, Sanjay Deb, Sumedha Kotwal, Ramesh Dawar

Department of Pathology, Dharamshila Hospital and Research Centre, New Delhi, India

Dear Sir,

Surgical sponges are the most common type of retained foreign body.^[1] The condition is called Gossypiboma. The term Gossypiboma, derived from the Latin word “Gossypium” (cotton) and the Swahilli “Boma” (place of concealment) denotes retained surgical sponge.^[2] As this carries a medico legal implication, due care should be taken when diagnosing it and strict measures taken to prevent this complication from arising after surgery. Gossypiboma is most frequently diagnosed in the abdominal cavity and abdominal sponge is the most common foreign body reported.^[3,4] Its was first reported by Wilson et al in 1884 and since then it has been reported as 1 in 100 to 3000 for all surgical interventions and 1 in 1000 to 1500 of all intra-abdominal operations.^[4]

A 45 year old diabetic female presented with complaints of abdominal distension and dull aching pain. She gave a history of cholecystectomy seven years ago at another hospital. On examination there was a scar of cholecystectomy and a central huge abdominal mass. The mass had ill defined borders with restricted mobility. Routine investigations were Hb-12.8 gm %, TLC- 7,700/cumm, Platelets 1.84 lac/cumm. USG whole abdomen showed a large intra-abdominal mass without any clear organ of origin. Provisional diagnosis of ovarian mass was made. CA-125 levels were 57.20 U/ml (Normal <35 U/ml). CT scan was done and showed benign mesentric cyst measuring 16.65x16.93x11.75 cms with enlarged uterus having multiple fibroids. Patient underwent exploratory laparotomy. Transverse meso colectomy, mesentric cyst excision with total abdominal hysterectomy and bilateral salpingoophorectomy was performed, and the specimen

was sent to the pathology department. On gross examination there was a cystic mass measuring 19.0 x 18.0 x 13.0 cms (Fig 1). Outer surface showed attached mesentery with adherent blood clots. On cutting open cyst was filled with brownish fluid and there was a piece of gauze with surgical tape measuring 5 cms long attached to inner surface of cysts wall covered with yellow exudate(Fig 2). Uterus and cervix received separately measured 11.5 x 8.0 x 5.5 cm, endometrium 3.0 cm with myometrium showed multiple intramural fibroids varying in diameter from 0.4 cm to 3.0 cm. Right and left ovary showed multiple cysts filled with serous fluid. Bilateral fallopian tubes were unremarkable. Microscopic examination revealed a cyst wall formed by fibrocollagenous tissue, numerous multinucleate foreign body type giant cells with intracytoplasmic refractile foreign bodies. No atypia seen. Sections from mesentery were unremarkable. Diagnosis of gossypiboma was made. Cervix showed features of chronic cervicitis with squamous metaplasia, endometrium was in proliferative phase with myometrium showing multiple intramural fibroids. Bilateral ovaries showed follicular cysts and bilateral fallopian tubes were unremarkable.

Gossypiboma or a mass of cotton retained following surgical intervention is a rare clinical complication. The sponges are inert tissue and do not undergo decomposition. The clinical presentation of gossypiboma varies and depends on the location of the sponge and the type of reaction.

Body can respond to the retained sponge in two ways. The first type is an exudative, acute inflammatory response with the formation of abscess in proximity to the retained sponge. This response usually leads to early detection and

*Corresponding author:

Dr. Pankaj Gupta, Department of Pathology, Dharamshila Hospital and Research Centre, New Delhi-110096, India
Phone: +91-9827624626
E-mail: drpankaj9@gmail.com



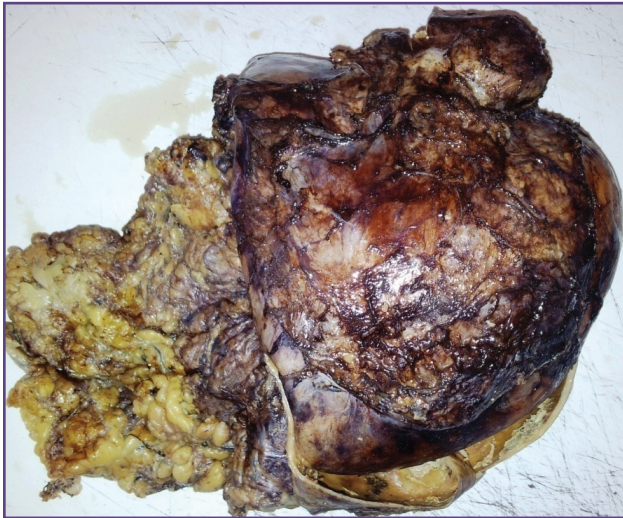

Fig. 1: Gross Specimen of Abdominal Lump

surgical removal. The second type is aseptic with fibrotic reaction to the cotton material and development of mass. This response usually presents with mass or abdominal pain or more commonly is an incidental finding.^[3] This case is peculiar as it has presented seven years after surgery and had elevated levels of CA 125 thus mimicking an ovarian tumor.

Gossypibomas are uncommon, mostly asymptomatic and hard to diagnose. Particularly, chronic cases do not show specific clinical and radiological signs for differential diagnosis. It should be included in the differential diagnosis of soft-tissue masses detected in patients with a history of a prior operation. Although human errors cannot be completely avoided, continuous medical training and strict adherence to rules of the operation room should reduce the incidence of Gossypiboma to a minimum.

Acknowledgements

None

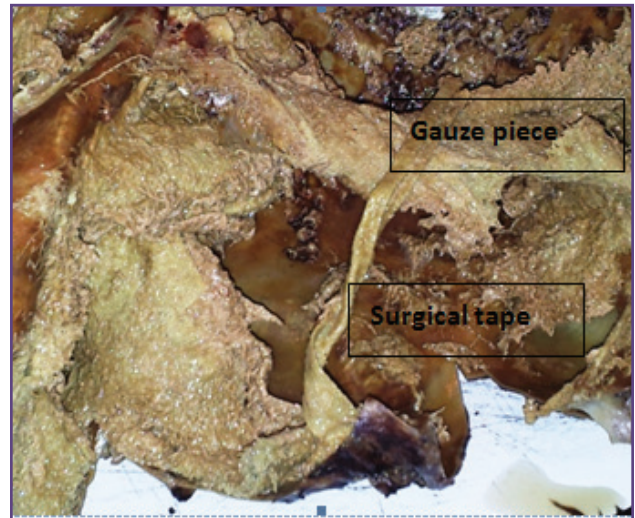


Fig. 2: Cut section showing Surgical tape and gauze piece

Funding

None

Competing interests

None declared

Reference

1. Aminian A. Gossypiboma: a case report. *Cases Journal* 2008;1:220
2. Ray S, Das K. Gossypiboma presented as abdominal lump seven years after open cholecystectomy. *J. Surg. case rep.* 2011:2.
3. Moyle H, Hines OJ, McFadden DW. Gossypiboma of the abdomen. *Arch Surg.* 1996; 131:566-8.
4. Kholi S, Singhal A, Tiwari B, Singhal S. Gossypiboma, Varied presentation: A Report of Two Cases. *J Clin Imaging Sci.*2013;3:11.