

Cytodiagnosis Of Sternocleidomastoid Pseudotumour In A Neonate Presenting As Lateral Neck Mass

Deepti Sukheeja*, Naresh N Rai, Neelu Vashist

Department of Pathology, Government Medical College, Kota, Rajasthan, India

Dear Sir,

Sternocleidomastoid pseudotumour (SCMP) is an uncommon clinical entity presenting as lateral neck mass in a neonate. It is known to regress spontaneously. FNAC plays an important role by helping in early diagnosis and preventing any unnecessary surgical intervention. A one month old male child presented with torticollis [Figure 1a]. He had a hard immobile swelling on lateral aspect of neck on left side measuring 3 × 2cm. His mother revealed history of prolonged labour. Post partum period went uneventful. His general physical examination was unremarkable. USG was done which showed thickened sternocleidomastoid muscle with a fusiform swelling [Figure 1b].

FNAC was performed from the swelling with 23G needle and 10 ml plastic disposable syringe. The wet smears were fixed in 95% ethanol and processed for Papanicolaou stain and the air dried smears were stained with May-Grunwald-Giemsa stain. Microscopy showed moderately cellular smear composed of oval to spindle shaped fibroblastic cells scattered singly or in loose cohesive clusters. Cells were having plump oval to spindle nuclei with wispy cytoplasm. Background showed focal areas of myxoid material [Figure 2]. Based on above cytological finding, a diagnosis of sternocleidomastoid tumor of infancy was suggested, and the patient was managed conservatively. The lesion resolved after five months.

SCMP is a benign and self-limiting disorder presenting in neonates with history of difficult labour. Mostly it disappears without any surgical intervention. The right side is more commonly affected than left and males are affected more than females. History of complicated delivery and birth injury are associated in more than 50% cases.^[1] Various theories proposed behind its development

are intramuscular hemorrhage due to complicated delivery. It is also suggested as hamartomatous process unrelated to any traumatic cause.^[2]

The cytological features of SCMP can show fibroblasts having bland nuclei, degenerated atrophic skeletal muscle fibres in a clear background without any inflammation. Muscle giant cells; numerous, plump fibroblasts; and collagen can be found along with bare nuclei in the background. According to a study done by Sharma et al on cytology of eight cases collagen was found in all cases.^[2] However it was not present in our case.

Other differential diagnosis of neonatal neck swellings are abscess, lymphadenitis, hematoma congenital lesions like cystic hygroma, branchial cleft cyst thyroglossal duct cyst, hemangiomas, teratomas, dermoid cysts or neoplastic lesions like lipomas, rhabdomyosarcoma fibrosarcoma, neuroblastoma and lymphoma^[2]. FNAC is a very fruitful procedure in excluding these causes. The key to prevent this deformity is early diagnosis and conservative management of the affected muscle, with only 5% of cases needing surgical intervention in a large prospective series^[4].

To conclude, Lateral neck mass in a neonate may mimic a neoplasm. An early FNAC is not only diagnostic but also prevents unnecessary surgical intervention. Conservative management is the key to prevent this disease.

Acknowledgements

none

Funding

None

Competing Interests

None declared

*Corresponding author:

Dr Deepti Sukheeja, H.N 1, Vigyan Nagar Special, Kota-5 Rajasthan, India

Phone: +91-8058010655

E-mail: deeptisukheeja2001@yahoo.co.in



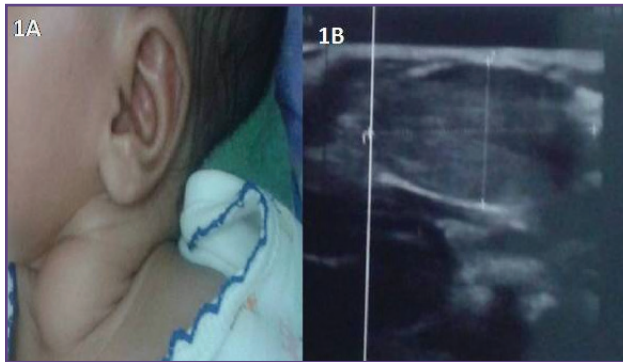

Fig. 1: 1a: Neonate presenting as left sided neck swelling. 1b: USG showing fusiform enlargement of SCM muscle.

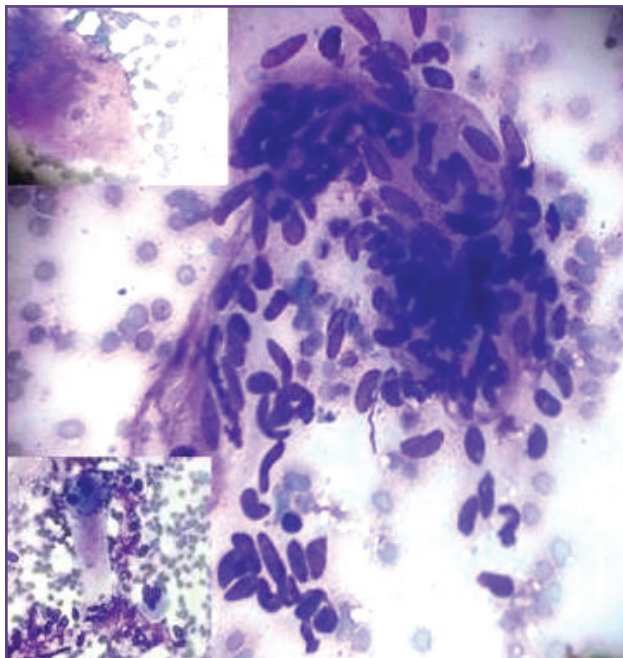


Fig. 2: MGG Stained smear (100X) showing cluster of bland spindle cells with inset showing myxoid stroma (upper left) and multinucleated giant cell (lower left)

Reference

1. Baisakh MR, Mishra M, Narayanan R, Mohanty R. Cytodiagnosis of sternocleidomastoid tumor of infancy. *J Cytol.* 2012; 29: 149–151.
2. Sharma S, Mishra K, Khanna G. Fibromatosis colli in infants- a cytologic study of eight cases. *Acta Cytol.* 2003;47:359–62.
3. Rajalakshmi V, Selvambigai G, Jaiganesh: Cytomorphology of fibromatosis colli. *J Cytol* 2009, 26:41-42
4. Cheng JC, Wong MW, Tang SP, Chen TMK, Shum SLF, Wong EMC. Clinical determinants of the outcome of manual stretching in the treatment of congenital muscular torticollis in infants. A prospective study of 821 cases. *J Bone Joint Surg Am* 2001; 83:679–687