

### Intraparotid schwannoma on cytology

Lakshmi Agarwal, Deepti Sukheeja\*, Vinny Gupta, Swati Namdev, Naresh N Rai

Department Of Pathology, Government Medical College & Associated Group of Hospitals, Kota, Rajasthan, India

#### Dear Sir,

Schwannomas are ectodermally derived benign, encapsulated tumours arising from the schwann cells of the neural sheath of motor and sensory peripheral nerves. It is difficult to diagnose preoperatively because of the low incidence rate, lack of classical sign of facial nerve palsy and clinically it mimics benign parotid parenchymal tumor. But fine needle aspiration cytology (FNAC) if done properly can help in diagnosing this lesion which is further confirmed by histopathology. A 40 years old male presented with painless swelling of the right parotid region. The swelling was firm, and mobile measuring 1x1 cm. There was no lymphadenopathy. Oral cavity was normal. USG showed a small hypo-echogenic solid tumor in the deep part of parotid gland. Based on the above investigations, clinical diagnosis of pleomorphic adenoma was made.

FNAC was performed. Cytosmears revealed large, cohesive fragments of wavy nuclei with pointed nuclear

ends. Verocay bodies, Antony A and Antony B areas were evident. Background showed abundant fibrillary materials. Mitosis and necrosis were not seen. The diagnosis of benign nerve sheath tumor most probably schwannoma was made. Excision biopsy and histopathology was done which revealed the characteristic features of schwannoma and final diagnosis of intra parotid schwannoma of facial nerve was made.

The intraparotid facial nerve schwannoma was first described by Ibrah in 1927. Most of the tumor arises from the intratemporal part of facial nerve. A few cases have been described originating from the intraparotid facial nerve (10%).<sup>[1,2,3]</sup> Most of these arise from the eighth nerve sheath but are relatively uncommon from seventh nerve.<sup>[4]</sup> The role of (FNAC) in diagnosis of parotid lesions is uncertain and often misleading. Inohara H et al., in 2008 had concluded that the accuracy of FNAC in diagnosis of parotid lesions was 80% and 62% for benign and malignant

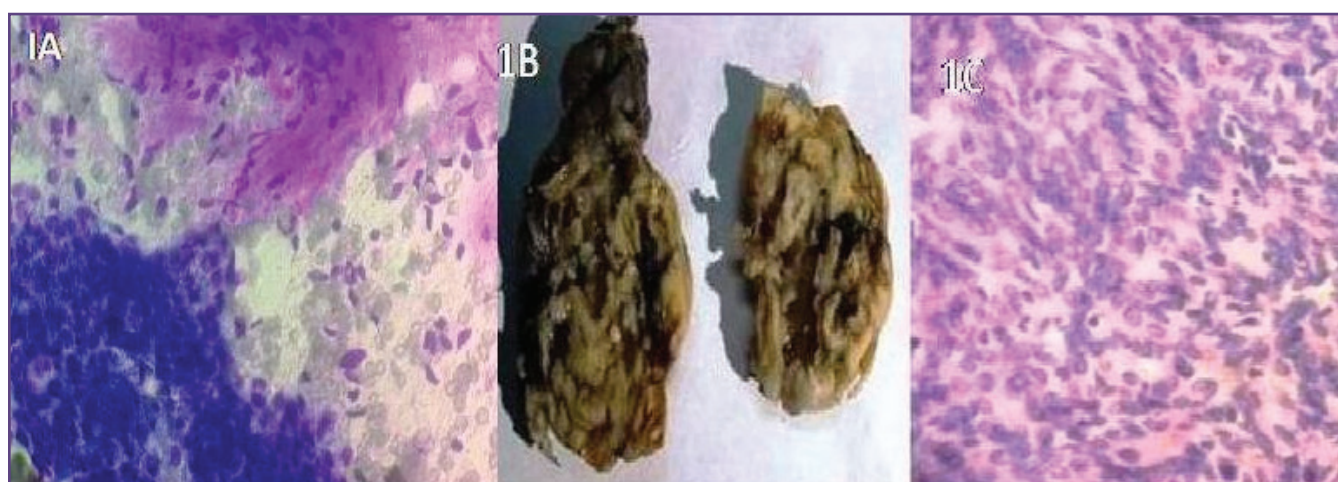


Fig. 1: 1A: Cytology showing spindle cells along with myxoid background matrix. A cluster of parotid ductal cells also seen. 1B: Gross picture of schwannoma. 1C: Tissue section showing spindle cells with palisading nuclei.

#### \*Corresponding author:

Dr Deepti Sukheeja, House No 1, Vigyan Nagar Special, Kota-5, Rajasthan, India  
Phone: +91 - 8058010655  
E-mail: deeptisukheeja2001@yahoo.co.in

lesion, respectively. So FNAC of parotid lesion are rarely asked for. [5] So it becomes difficult to arrive at the diagnosis of intraparotid schwannoma pre operatively and can be easily misdiagnosed. The definite diagnosis of facial nerve schwannoma is usually confirmed by histopathology. Intra parotid schwannoma can be confused with spindle cell myoepithelioma on cytology. But it can be differentiated on the basis of strong positivity for S100, whereas negative reaction for P63, vimentin and cytokeratin.

To conclude, intra parotid schwannoma can be diagnosed by FNAC if done properly. This will also help the surgeons in deciding the treatment of patient preoperatively.

### **Funding**

None

### **Competing Interests**

None Declared

### **Reference**

1. Oncel S, Onal K, Ernete M. Schwannoma (neurilemoma) of the facial nerve as a parotid mass. *J Laryngol Otol.* 2002; 116: 642–3.
2. Kumar BN, Walsh RM, Walter NM. Intraparotid facial nerve schwannoma in child. *J Laryngol Otol.* 1996; 110: 1169–70.
3. Liu R, Fagan P. Facial nerve Schwannoma: surgical excision versus conservative management. *Ann OtolRhinolLaryngol* 2001;110(11):1025-9.
4. Kyriakos M., Pathology of selected soft tissue tumors of the head & neck. In: Thawley S.E, Panje WR, Batsakis JG, and Lindberg RD, Eds. *Comprehensive management of head and neck tumors* .1st Ed. Philadelphia: WB Saunders, 1987:1254-1256.
5. Inohara H, Akahani S, Yamamoto Y, et al. The role of fine-needle aspiration cytology and magnetic resonance imaging in the management of parotid mass lesions. *Acta Otolaryngol* 2008;128(10):1152-8.