

# Adenoid Cystic Carcinoma of Floor of The Mouth with Periumbilical Cutaneous Metastasis

Reena Sinha, Pallavi Agrawal\*, Akash Kumar Singh

Department of Pathology, Mahavir Cancer Institute & Research Centre Patna (Bihar), India

**Keywords:** Adenoid Cystic Carcinoma, Cutaneous Metastasis, Differential Diagnosis, Immunohistochemistry

### ABSTRACT

Cutaneous metastasis from salivary gland adenoid cystic carcinoma (ACC) is extremely rare. We report a rare case of cutaneous metastasis from ACC of floor of the mouth. The presentation of cutaneous metastasis is nonspecific. Fine needle aspiration cytology becomes a quick and effective tool for the diagnosis in such cases. The clinical, histopathological differential diagnosis and immune-histochemical features are described and discussed. This brief report highlights the importance of clinical awareness of cutaneous metastasis after a long time lag which may mimic adnexal lesions.

**\*Corresponding author:**

Dr. Pallavi Agrawal, Department of Pathology, Mahavir Cancer Sansthan, Phulwarisharif, Patna – 801505 (Bihar), India

Phone: +91 7739165410

E-mail: dr.pallavimamc@gmail.com



## Introduction

Adenoid cystic carcinoma (ACC) is a salivary gland tumor characterized by slow and infiltrative growth with a relatively favorable survival rate of 5 years, but poor long term prognosis due to frequent late, local and distant recurrences<sup>[1]</sup>. Distant metastasis involves mainly the lungs followed by bone, liver and brain<sup>[2]</sup>. Cutaneous metastasis is very rare. This case highlights the importance of detailed clinical and dermatological examination in patients treated for salivary gland adenoid cystic carcinoma.

## Case Report

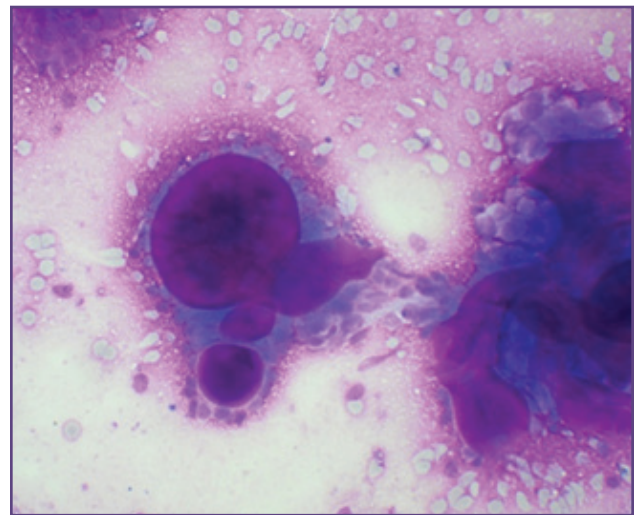
A 45-year old female presented with a painless swelling in the floor of the mouth for past one year. It was gradually progressive. There was no cervical lymphadenopathy or any other complaints. Fine needle aspiration cytology (FNAC) was performed which revealed moderately cellular smears with groups of monomorphic cells associated with round to oval globules of matrix material (Fig 1). The background showed scattered single cells. Based on this morphology a diagnosis of adenoid cystic carcinoma was considered.

The patient underwent segmental mandibulectomy with extended supra-omohyoid dissection (SOHD) with composite resection of tumor. Gross examination revealed a poorly circumscribed and non-capsulated solid mass measuring 4×4×3cm. Cut section was solid and grey white in color. On microscopic examination the tumor cells showed cribriform pattern with islands of basaloid cells surrounding variably sized cyst like spaces (Fig 2). Individual tumor cells were angulated with hyperchromatic nucleus and scant amount of eosinophilic cytoplasm. Perineural invasion was not observed.

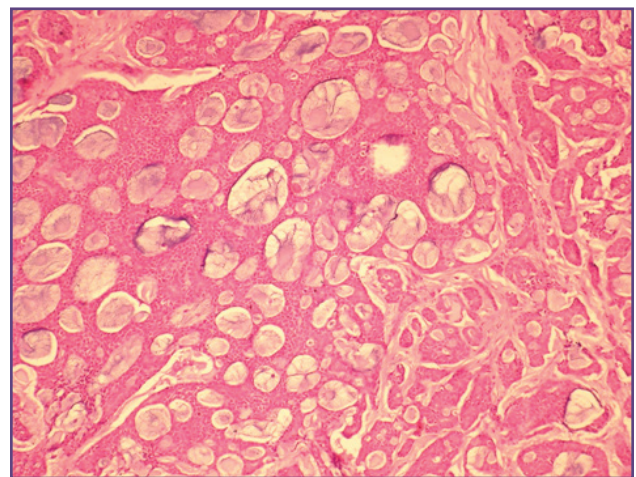
Immuno-histochemical analysis revealed diffuse immunoreactivity for cytokeratin 7 and c-kit (CD117) in the epithelial cells and p63, S-100 and calponin in the myoepithelial cells. Based on these findings a final diagnosis of adenoid cystic carcinoma was attained. She was given external beam radiation therapy and was on regular follow up for two years. The disease was locally controlled except for few side effects of radiation therapy like mucosal dryness of mouth. The patient assumed to be cured was lost to follow up. She presented 3 years later with a periumbilical nodule (Fig 3). FNAC from the nodule revealed the features of adenoid cystic carcinoma. In view of cutaneous metastasis further work up was done. Computerized tomography thorax and abdomen revealed multiple nodules in lungs and liver. The patient was given palliative chemotherapy. She is alive at present without any clinical and radiological evidences of tumor recurrence.

## Discussion

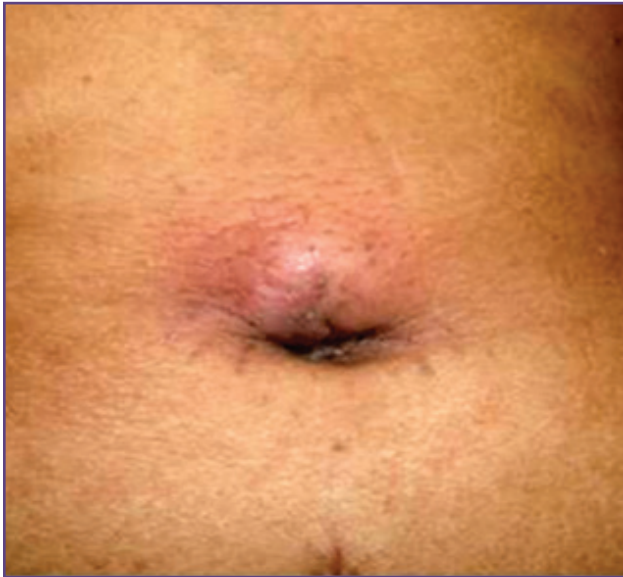ACC is one of the commonest malignant salivary gland tumors representing approximately 7.5% of the salivary gland malignancies<sup>[3]</sup>. It is characterized by an indolent clinical course and poor long term prognosis. The incidence of distant metastasis varies between 24% and 52%<sup>[4]</sup>. The most common sites for distant metastasis are lungs, liver and brain however subcutaneous metastasis is extremely rare. The incidence of subcutaneous metastasis is 2% in men and 1% in women<sup>[5]</sup>. Sometimes subcutaneous tissue may be involved due to direct extension of the tumor. The exact mechanism of cutaneous metastasis in ACC of salivary gland is incompletely understood. Several hypotheses have been postulated. The cutaneous



**Fig. 1: Cytomorphological photograph of the cutaneous nodule showing round to oval globules of matrix material; (MGG, 40X).**



**Fig. 2: Histopathological section showing basaloid cells in cribriform pattern, surrounding gland like spaces; (H&E, 40X).**



**Fig. 3: Clinical picture of the metastatic peri-umbilical nodule.**

metastasis may evolve through three possible mechanisms including direct spread, local spread and distant spread [6]. Direct extension is due to contiguous spread via tissue planes. Local spread can be ascribed to spread through dermal lymphatics with resultant implantation in the skin. Distant metastasis is the result of hematogenous spread. This route of hematogenous spread could be either through pulmonary circulation or bypassing pulmonary circulation via azygous and vertebral venous plexus [7].

The common differential diagnoses of ACC includes tumors that exhibit tubular and cribriform pattern such as polymorphous low grade adenocarcinoma (PLGA), tumors with basaloid cellular morphology such as basal cell adenoma, basal cell adenocarcinoma, basaloid squamous cell carcinoma with adenoid cystic pattern and tumors with dual population of ductal and myoepithelial cells such as pleomorphic adenoma. Pleomorphic adenoma can be identified by cells with plasmacytoid appearance and abundant cytoplasm. In contrast most ACC show little cytoplasm. Hyaline spherical globules are seen in both the neoplasms. Basal cell adenoma can be identified by the presence of a capsule and lack of stromal and perineural invasion. Adenoid basal cell carcinoma should be differentiated by the presence of peripheral nuclear palisading, stromal retraction clefts, epidermal connection and absence of perineural spread. They are usually CEA and S-100 negative. PLGA occurs almost exclusively in the minor salivary gland and has overlapping histopathologic features with ACC having ductal, tubular or cribriform pattern. Perineural invasion is also common. However,

the presence of cuboidal or columnar cells with pale and ovoid nuclei and eosinophilic cytoplasm is in contrast with the hyperchromatic and angulated cells of ACC. In addition PLGA lacks a dual population of ductal and myoepithelial cells and typically has negative or low (less than 50% of cells) expression of c-KIT compared with the high c-KIT expression in ACC. Basaloid squamous cell carcinoma with adenoid cystic pattern shows well demarcated nests of basaloid tumor cells invested by hyaline basement membrane material often creating cyst-like spaces between the cells, to simulate a cribriform pattern. On immunohistochemistry these are positive for high molecular weight cytokeratins while ACC is positive for cytokeratin 7 and myoepithelial markers like actin, p63, calponin and S-100. This immunoprofile was seen in the present case as well [4,8]. Another close mimicker of cutaneous ACC is mucinous carcinoma of the skin which typically shows islands of basaloid eccrine cells embedded in lakes or pools of mucin separated by fibrous septa. The mucin is hyaluronidase resistant and sialidase labile, indicating that it is a sialomucin, as opposed to the hyaluronic acid seen in cutaneous ACC. Primary cutaneous cribriform apocrine carcinoma should also be included in the differential diagnosis as it is a non-encapsulated dermal tumor with an extensive cribriform pattern formed by multiple interconnected basophilic epithelial cells that are arranged in solid nests or tubular structures, and many small round spaces in between. As opposed to cutaneous ACC, basophilic aggregations as well as spaces within are often more varied in size and shape, cells are more interconnected, true elongated tubules, but no deposition of basement membrane material, are observed, and neoplastic cells contain pleomorphic rather than monomorphic nuclei. No perineural or intravascular invasion is seen.

When ACC arises directly in the skin it is considered as primary cutaneous adenoid cystic carcinoma (PCACC) which has to be differentiated from a metastasis or direct extension of a salivary gland ACC to the skin. Cutaneous ACC is a rare tumor with histological features closely resembling ACC of the salivary glands. Therefore, cutaneous and metastatic ACC can only be distinguished based on clinical grounds and the diagnosis of cutaneous ACC can only be established by a lack of any history or current evidence of ACC from an extracutaneous source. It is important to differentiate between primary and metastatic ACC as the ACC of salivary glands is an aggressive tumor in which local recurrence and widespread metastases result in death in the majority of patients; whereas cutaneous ACC tends to run an indolent course despite a high tendency for local recurrence. PCACC is characterized by an indolent

but progressive course, frequent involvement of the scalp, perineural infiltration, a tendency to recur locally, and rare nodal or metastatic spread. Cutaneous ACC often presents as a firm, slow-growing, ill-defined nodule or tumor that may be asymptomatic, or with symptoms including tenderness, pruritus, and secondary alopecia<sup>[9]</sup>.

Treatment of patients with distant metastasis remains unresolved. ACC is unresponsive to anti-neoplastic drugs generally used for chemotherapy. A transmembrane receptor tyrosine kinase has been found in ACC which is the product of the proto-oncogene c-kit. It has been hypothesized that a high percentage of c-KIT positive ACC suggest that this proto-oncogene could be associated with the development of the tumor<sup>[10]</sup>. Recently, a specific inhibitor of the bcr-abl autophosphorylation, platelet-derived growth factor receptor (PDGFR), and c-KIT tyrosine kinases, named imatinib mesylate has been proved to show good results in cases of unresectable or metastatic ACC that overexpresses CD117. If there is isolated metastasis surgical resection is considered generally<sup>[11]</sup>.

### Conclusion

Both primary and metastatic cutaneous ACC are very rare. The clinical presentation of cutaneous metastasis is non-specific and may mimic benign lesions. Subcutaneous nodules that are rapidly progressive, eruptive, firm, painful and have non-healing ulceration should remind the clinicians the possibility of cutaneous metastasis of ACC. Since there is no histological difference between primary and cutaneous ACC metastasis so a complete clinical history is very important in such cases. To avoid delay in the treatment of such cases FNAC becomes a quick and effective tool for the early diagnosis and treatment.

### Conflict of interest

The authors declare that they have no conflict of interest related to the publication of this manuscript.

### FUNDING

NIL

### References

1. Khan AJ, DiGiovanna MP, Ross DA, Sasaki CT, Carter D, Son YH, Haffty BG: Adenoid cystic carcinoma: a retrospective clinical review. *Int J Cancer* 2001;96:149-158
2. Spiro RH: Distant metastasis in adenoid cystic carcinoma of salivary origin. *Am J Surg* 1997;174:495-498
3. Ellis GL, Auclair P: Tumors of the salivary glands: Atlas of Tumor Pathology. Washington, DC: Armed Forces Institute of Pathology, 3rd Series, Fascicle 17, 1996
4. Perez DE, Magrin J, de Almeida OP, Kowalski LP. Multiple cutaneous metastases from a parotid adenoid cystic carcinoma. *Pathol Oncol Res.* 2007;13(2):167-9. Epub 2007 Jul 3.
5. Schwartz RA: Cutaneous metastatic disease. *J Am Acad Dermatol* 1995;33:161-182
6. Kmucha ST, Troxel JM. Dermal metastasis in epidermoid carcinoma of the head and neck. *Arch Otolaryngol Head Neck surg.* 1993;119:326-30
7. Batson OV. The role of the vertebral veins in metastatic processes. *Ann Intern Med.* 1942;16:38-45
8. Jaso J, Malhotra R. Adenoid cystic carcinoma. *Arch Pathol Lab Med.* 2011;135:511-5. doi: 10.1043/2009-0527-RS.1.
9. Dores GM, Huycke MM, Devesa SS, Garcia CA. Primary cutaneous adenoid cystic carcinoma in the United States: incidence, survival, and associated cancers, 1976-2005. *J Am Acad Dermatol.* 2010; 63(1): 71-78.
10. Holst VA, Marshall CE, Moskaluk CA and Frierson HF Jr: KIT protein expression and analysis of c-kit gene mutation in adenoid cystic carcinoma. *Mod Pathol* 1999;12:956-960
11. Hotte SJ, Winkquist EW, Lamont E, MacKenzie M, Vokes E, Chen EX, Brown S, Pond GR, Murgo A, Siu LL: Imatinib mesylate in patients with adenoid cystic cancers of the salivary gland expressing c-kit: A Princess Margaret Hospital phase II consortium study. *J Clin Oncol* 2005; 23:585-90