

# Chorangioma with Chorangioma, Placenta: A Rare Entity of Clinical Significance

Swati Singla, Ankit Kaushik, Charanjeet Ahluwalia, Gaurav Singla\* and Ashish Kumar Mandal

Department of Pathology, Vardhman Mahavir Medical College and Safdarjung Hospital, New Delhi, India

*Keywords: Chorangioma, Placenta, Chorangioma*

### ABSTRACT

Placental chorangiomas are benign vascular tumours of placenta arising from chorionic tissue with an average incidence of 0.5-1%. Hypertension and diabetes are found more often in combination with chorangiomas than they are in otherwise normal pregnancies. It is often associated with adverse clinical outcome like preeclampsia, IUD.

Chorangioma is characterized by an increase in number of small sized vascular channel with in chorionic villi. Chorangioma is considered as hypoxia related angiogenesis mainly associated with numerous maternal, foetal and placental disorders.

Though both of the conditions have been described separately in literature we present a case with both these conditions.

**\*Corresponding author:**

Dr. Gaurav Singla, Department of pathology, Safdarjung Hospital and Vardhman Mahavir Medical College, New Delhi-110029, INDIA

Phone: +91 9811989652 Fax: 011-26198455

E-mail: gauravjency1987@gmail.com



## Introduction

Chorangioma also known as placental hemangioma is a benign tumor of the placenta that occurs in 0.5 – 1 % of carefully examined placentas. Their frequency rises in women over 30 years old. They are often found in primipara and twin pregnancies. Hypertension and diabetes are found more often in combination with chorangiomas than they are in otherwise normal pregnancies.<sup>[1]</sup> They are more common in high altitudes and are also associated with preeclampsia which suggest that low oxygen tension may play a role in their development. Chorangiomas are a placental change characterized by hypervascular terminal chorionic villi without stromal hypercellularity.<sup>[2]</sup> It occurs in 5 – 6% of placentae and have been associated with high mortality (42%) and major congenital malformations (39%).<sup>[2]</sup> Both of these entities have been described in the literature separately. We present a case report where both the findings were present in the same placenta.

## Case History

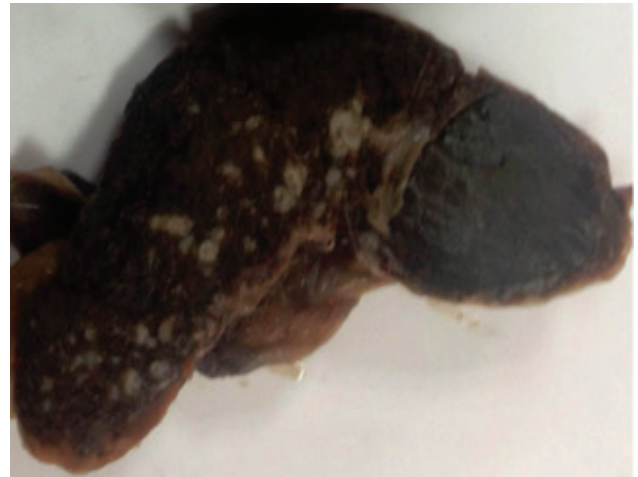
A 25 year old G<sub>2</sub>P<sub>1</sub>L<sub>1</sub> presented at term with fetal distress. A Lower segment Cesarean section was performed and was uneventful. The weight of the baby was 2.8 kg at birth. Haematological, echocardiographic and abdominal ultrasound of the baby were normal.

The placenta was sent to the histopathology department for pathological examination. Grossly placenta measured 17x13x3 cm and weighed 550 gm. Membranes were intact. Maternal surface showed 15 cotyledons and fetal surface was unremarkable. Serial sections of placenta showed a well circumscribed reddish-brown area at placental margin measuring 5x3x2 cm (Fig.1).

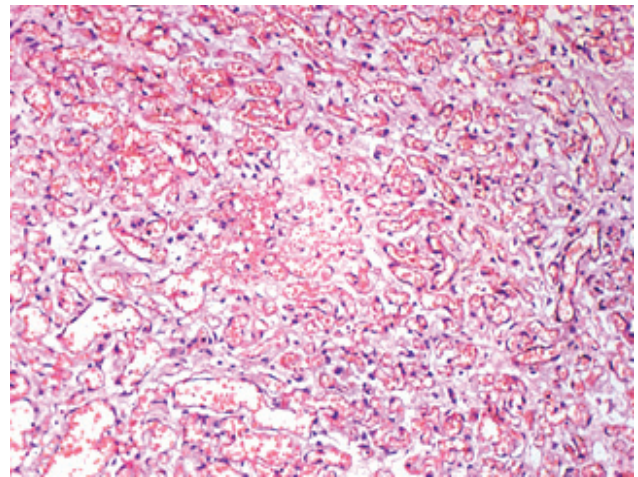
On microscopy the well circumscribed reddish brown area of placenta showed numerous small capillary sized channels (Fig.2) with occasional large sized vascular spaces and focal areas of calcification. Section from the surrounding normal placenta showed increased number of capillary sized vascular channels varying in number from 10-12/ villi in ten different regions (Fig.3). Immunohistochemistry for smooth muscle actin was negative showing absence of pericytes (Fig.4). Hence the final diagnosis of chorangioma with chorangiomas, placenta was made.

## Discussion

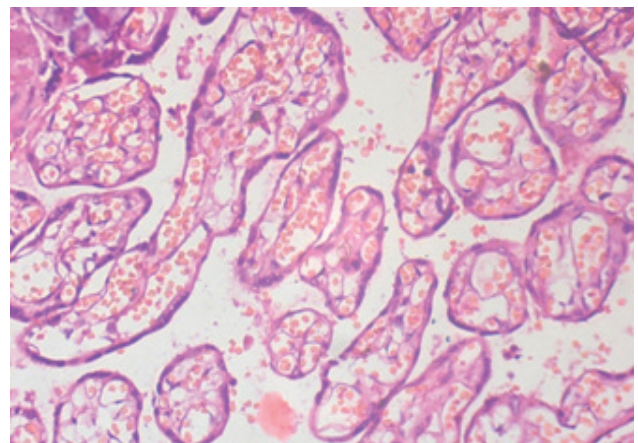
Chorangioma is a non trophoblastic tumour characterized by abnormal vascular development within the placental parenchyma. It is most commonly observed in the third, and less frequently in the second trimester of pregnancy. It may either present as a solitary nodule or, less frequently, as multiple nodules.<sup>[3]</sup> It is most commonly found on the fetal surface of the placenta, often in the vicinity



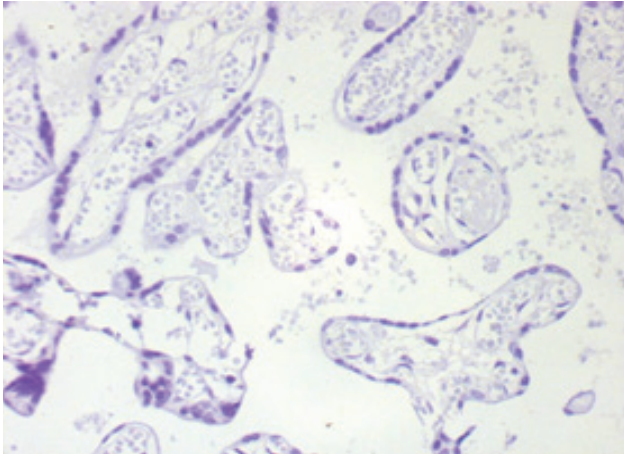
**Fig. 1:** Shows reddish brown area (chorangioma) at placental margin



**Fig. 2:** Shows numerous small capillary sized channels with occasional large sized vascular spaces (200x) (H & E)



**Fig. 3:** Shows increased number of capillary sized channels per villi (400x) (H&E)



**Fig. 1: IHC for SMA is negative showing absence of pericytes (400x)**

of umbilical cord insertion, with larger tumors being usually attached to the chorion. The clinical significance of chorangioma is size-dependent. Small chorangiomas possess no clinical significance. On the contrary, clinically significant chorangiomas, greater than 5 cm or multiple, may be associated with hydroamnios, hemorrhage, premature delivery, premature placental separation and placenta previa.

[4] These manifestations may result in severe fetal distress and intrauterine death. They may also lead to nonimmune hydrops fetalis. [4] Anaemia, thrombocytopenia or congestive cardiac failure may be seen in a neonate. The normal terminal chorionic villi should contain no more than five vascular channels, even when the same vessel is present in more than one plane of section. [5] The diagnostic criteria of chorangiomas was established by Altshuler [2] in 1984 as the presence of 10 villi, each with 10 or more vascular channels in 10 or more areas of 3 or more of random, non infarcted placental areas. Chorangiomas is considered as hypoxia related angiogenesis mainly associated with numerous maternal, foetal and placental disorders. [2,6,7] The maternal complications consist of pregnancy induced hypertension (PIH), pre-eclampsia, abruptio placentae, diabetes mellitus, severe anaemia and syphilis while fetal complications consist of fetal intrauterine growth retardation and intra uterine fetal death. Placentomegaly and chronic villitis may occur in placenta.

Chorangiomas has to be differentiated from chorangiomatosis. Chorangiomatosis is seen before 32 weeks of gestation and involve more proximal elements of villous tree, show increased stromal cellularity and stromal collagenisation. [7] Chorangiomas is more common after 37 weeks of pregnancy, is a diffuse process involving the tips of terminal villi and has numerous closely approximating capillaries with intact basement membrane. [7, 8]

In chorangiomatosis, villous capillaries are also numerically increased, but unlike chorangiomas, they are accompanied by

pericytes, involve stem villi, and usually occur in immature placentas of less than 32 weeks. The case we present here is unusual because even though the size of hemangioma was large it did not cause any abnormalities in the fetus, and the pregnancy was uneventful. We also observed associated chorioangiomas in the placental villi. This possibly resulted from a compensatory mechanism because of the reduction of the functional parenchyma. [9] Chorangiomas also has an important potential clinical significance and should be mentioned in the pathology report so that the patient should be investigated for associated conditions like diabetes, anaemia, syphilis, pre-eclampsia etc.

### Acknowledgement

All authors have contributed significantly, and that all authors are in agreement with the content of the manuscript.

### Declaration

Funding - None

The author(s) have no potential conflicts of interest with respect to the research, authorship, and/or publication of this article. The authors have no conflicts of interest to declare.

### References

1. Guschmann M, Henrich W, Entezami M, Dudenhausen JW. Chorangioma – new insights into a well-known problem I. Results of a clinical and morphological study of 136 cases. *J Perinat Med.* 2003;31:163–169.
2. Altshuler G. Chorangiomas: an important placental sign of neonatal morbidity and mortality. *Arch Path Lab Med* 1984; 108 : 71-74
3. Lež C, Fures R, Hrgovic Z, Belina S, Fajdic J, Münstedt K. Chorangioma placentae. *Rare Tumors* 2010; 2.:67
4. D’Ercole C, Cravello L, Boubli L, [Stanko Belina, Josip Fajdic, Karsten Münstedt](#) . Large chorioangioma associated with hydrops fetalis: prenatal diagnosis and management. *Fetal Diagn Ther.* 1996;11:357–60.
5. De La ossa MM, Cahello-Inchausti B, Robinson M.J. Placental chorangiomas. *Arch Path Lab Med* 2001; 125 : 1258-58.
6. Ogino S, Redline RW. Villous capillary lesions of the placenta: Distinction between chorangioma, chorangiomatosis and chorangiomas. *Hum Pathol* 2000; 31 : 945-54.
7. Caldarella A, Buccoliero AM, Taddei GL. Chorangiomas: report of three cases and review of the literature *Pathol Res Pract* 2003; 199 : 847-50.
8. Bittencourt AL, Chagas K, Calabrick VAT .Large placental hemangioma diagnosed by ultrasonography - a case report. *Sao Paulo Med. J.*1995;113:6.