

Diagnostic Dilemma at Preoperative Biopsy Diagnosis of Oral Cavity Lesions with Recommendations

Madhu I Chaturvedi* and Arshad K Pathan

Pathology department, LTM Medical College and General hospital Sion , Mumbai, India

Keywords: Biopsy, Oral Cavity, Pitfalls, Problems

ABSTRACT

Background: Oral cavity lesions of varied nature present in varying patterns from a plaque to a proliferative growth. Biopsy is an important preoperative diagnostic tool for the diagnosis of lesions ranging from simple tumour like lesions to malignancies and deciding the treatment and extent of surgery. At times it becomes difficult for a pathologist, to decide exact nature of the growth at biopsy. The authors share their experience and dilemma during reporting and views to solve them.

Methods: All the punch biopsies and subsequent surgical resections of oral cavity received in department of pathology were reviewed over a period of two years. They were subjected to routine tissue processing in automatic tissue processor, 4-5 microns section cutting and routine H& E staining. Histopathology was evaluated. All the tumours were classified according to WHO classification of Head and Neck tumours. Tumour like lesions was evaluated on the basis of features described by various authors in the literature. Specificity, sensitivity, accuracy, percentage of false negative and false positive, and positive and negative predictive value of the oral cavity biopsy was evaluated.

Result: Majority of the oral cavity lesions irrespective of nature, presented as exophytic proliferative growth (83.9%). The diagnostic accuracy of biopsy for evaluating oral cavity lesions was 95.1%. There were 6.9% false negative reports. Sensitivity and positive predictive value of the method to detect malignant and premalignant lesions was 93.1% and 100% respectively, whereas, specificity and negative predictive value was 100% and 85 %. In total 19 cases, problem of histopathology assessment was encountered.

Conclusion: To prevent problems and pitfalls in assessing the nature of oral cavity lesion prior to surgery, the reporting pathologist should take utmost care in proper orientation and processing of the tiny oral cavity biopsies, be aware of accurate definitions , characteristic features and criteria of malignancy and should have a close co-ordination with the treating surgeon.

***Corresponding author:**

Dr Madhu I Chaturvedi, Associate Professor , Second floor ,Pathology department, College building, LTM Medical college and General hospital , Sion,Mumbai. 400022.

Phone: + 91 9820322802

Email: madhu_chaturvedi@yahoo.co.in



Introduction

Oral cavity is subjected to broad spectrum of agents leading to changes in oral mucosa. The changes inflicted by these varied agents in oral mucosa may range from a white patch, a plaque, an ulcer or a growth. These changes can be the cause of anxiety in an individual as they raise the suspicion of cancer. All the oral cavity lesions are first biopsied before proceeding to the final surgical procedure of local excision or wide local excision or radical resection surgery, depending on the pathological assessment of the biopsy. Therefore, pathologists play an important role to differentiate them and their judgment is crucial in deciding to adopt an adequate treatment strategy. Tissue specimens from the oral cavity are often small in size and many tissue alterations can occur at various stages: during surgical removal and tissue processing, interfering with the pathologist's ability to provide an accurate diagnosis. Therefore, the present study was conducted to evaluate the role of biopsy in the assessment of true nature of oral cavity lesions and its problems and pitfalls.

Materials and Methods

The present analytical type of cross-sectional study was conducted in a 1400 bedded tertiary care hospital. This hospital caters to the health problems of lower and middle income group population from the area in near vicinity as well as patients referred from nearby suburbs. Approval of the institutional ethics committee was taken to conduct this study.

To minimize misclassification errors and for the purpose of evaluation, the extent of oral cavity was defined according to American Joint Committee on Cancer Staging [1]. The oral cavity extends from the skin- vermilion junction of the lips to the junction of the hard and soft palate above and to the line of the circumvallate papillae of the tongue below. Thus, the lesions arising from lips, buccal mucosa, upper and lower alveolar ridge, retromolar trigone, floor of the mouth, hard palate and anterior two third of tongue were included in the present study.

All the punch biopsies and subsequent surgical resections received in department of pathology, were reviewed over a period of two years. They were subjected to routine tissue processing in automatic tissue processor, 4-5 microns section cutting and routine H& E staining. Histopathology was evaluated. All the tumours were classified according to WHO classification of Head and Neck tumours. [2]

Tumour like lesions were evaluated on the basis of features described by various authors in the literature [3, 4, 5, 6]

Specificity, sensitivity, accuracy, percentage of false negative and false positive, and positive and negative

predictive value of the oral cavity biopsy was evaluated using formulas as follows: [7]

1. Specificity: $\frac{\text{True negative}}{\text{True negative} + \text{False positive}} \times 100$
2. Sensitivity: $\frac{\text{True positive}}{\text{True positive} + \text{False negative}} \times 100$
3. Positive predictive value: $\frac{\text{True positive}}{\text{True positive} + \text{False positive}} \times 100$
4. Negative predictive value: $\frac{\text{True negative}}{\text{True negative} + \text{False negative}} \times 100$
5. Accuracy: $\frac{\text{True positives} + \text{True negatives}}{\text{True positive} + \text{False positive} + \text{False negative} + \text{True negative}}$

Result

Total number of specimens of tumours and tumour like lesions received over a period of two years were 1911, of which, 152(8%) were from oral cavity.

Oral cavity lesions presented as many growth patterns like plaque, ulcer, and cyst. Majority of the oral cavity lesions irrespective of nature, presented as exophytic proliferative growth (83.9%) that caused high suspicion of malignancy especially in elderly patients. Behaviour wise distribution of growth patterns is shown in Table 1

The diagnostic accuracy of biopsy for evaluating oral cavity lesions was 95.1%. There were 6.9% false negative reports but no false positive reports. Sensitivity and positive predictive value of the method to detect malignant and premalignant lesions was 93.1% and 100% respectively, whereas, specificity and negative predictive value was 100% and 85 % respectively.

Problems and Pitfalls of Biopsy of Oral Cavity Lesions:

In total 19 cases, problem of histopathological assessment was encountered as follows:

1. **Inconclusive due to superficial biopsy (9 cases) (figure 1):** Punch biopsy was not of sufficient size and depth to include part of the advancing front of the tumour. Reorientation was asked for in all the cases but even the recut slides showed only benign keratinised stratified squamous epithelium with no underlying stroma.
2. **Interpretation dilemma due to proliferative lesion with no sufficient adjacent normal mucosa and underlying stroma (2 cases): Verrucous hyperplasia vs. verrucous carcinoma:** Section from punch biopsy showed on histology tortuous hyperplastic squamous epithelium with parakeratosis, hyperkeratosis, minimal cytologic atypia (figure 2a) and inter anastomosing broad rete ridges (figure 2b). Biopsy was not of

sufficient size and depth to include part of the advancing front of the tumour or adjacent normal mucosa. Therefore, a descriptive report was issued and inadequacy of the tissue to opine on malignant nature of the growth was stated. The laboratory received a wide local excision specimen of the patient. Histopathology of wide local excision revealed broad pushing blunt squamous epithelial downgrowths, and thus diagnosis of verrucous carcinoma was confirmed.

3. **Interpretation dilemma due to proliferative lesion with superficial invasion surrounded by dense inflammation (1 case): pseudoepitheliomatous hyperplasia verses well differentiated squamous cell carcinoma with superficial invasion:** Section from the biopsy showed predominantly hyperplastic squamous epithelium with dense lymphocytic inflammation in the underlying stroma and intact basement membrane. A keratin pearl and a focus of subtle disruption in basement membrane with few atypical squamous epithelial cells were noted superficially in the stroma surrounded by dense inflammation (figure 4). The diagnosis of suspicion of malignancy was conveyed to the surgeon. Wide local excision revealed unequivocal invasion in other focus.

4. **No precise histological categorisation (2 cases):** Verrucous hyperplasia was described as hyperplastic squamous epithelium with no atypia and a case of fibroepithelial polyp was described as normal squamous epithelium with fibrocollagenous connective tissue stroma.
5. **Interpretation error (5 cases): Hyperplastic and hyperkeratotic squamous epithelium vs. Well-Moderately differentiated squamous carcinoma :** Sections from punch biopsy of proliferative growths showed either inter- anastomosing thick bands of well differentiated squamous epithelium with minimal atypia and entrapped fibrovascular connective tissue and keratin pearls. There was no basement membrane breach (figure 4a) or islands of well differentiated squamous epithelium with intact basement membrane in the submucosa (figure 4b). These islands were considered as tangential cuts of hyperplastic rete ridges. The Cases were diagnosed as hyperplastic and hyperkeratotic squamous epithelium with no evidence of malignancy. Resection specimen was received in all cases. Sections showed unequivocal invasion and well differentiated squamous cell carcinoma.

Table 1: Site wise and behavior wise distribution of all tumour and tumour like lesions of the oral cavity (in number and percentages)

Site	Malignant (n=85, 59.4%)	Benign (n=21, 14.7%)	Premalignant (n=17, 11.9%)	Tumour like (n=20, 14%)	Total (n=143, 100%)
Lip	8(36.4%)	4(18.2%)	2(9.1%)	8(36.4%)	22(15.4%)
Buccal mucosa	31(58.5%)	8(15.1%)	10(18.9%)	4(7.5%)	53(37.1%)
Tongue	24(63.2%)	8(21.1%)	3(7.9%)	3(7.9%)	38(26.6%)
Gingivo- buccal sulcus	13(81.3%)	1(6.2%)	1(6.2%)	1(6.2%)	16(11.2%)
RMT	5(71.4%)	0	0	2(28.6%)	7(4.9%)
FOM	5(62.5%)	0	1(12.5%)	2(25%)	8(5.6%)
Hard palate	1(100%)	0	0	0	1(0.7%)

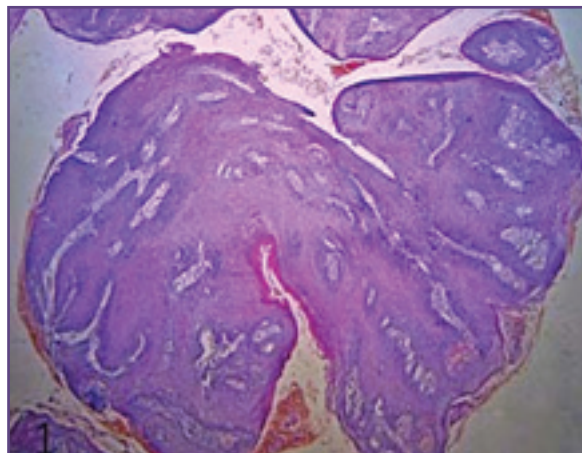


Fig. 1: Inconclusive biopsy from proliferative growth of buccal mucosa, due to superficial nature with no underlying stroma(H&E,400X)

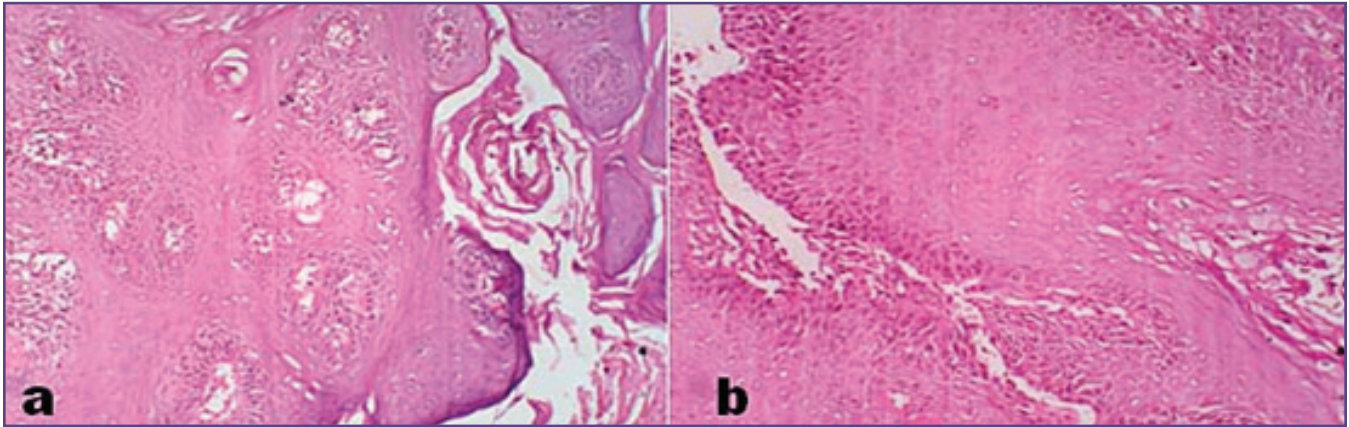


Fig. 2: Interpretation dilemma: verrucous hyperplasia vs. verrucous carcinoma. Biopsy shows (a) hyperplastic, hyperkeratotic squamous epithelium and (b) interanastomosing broad rete ridges but no normal adjacent mucosa or advancing front in underlying stroma (H&E, 400X).

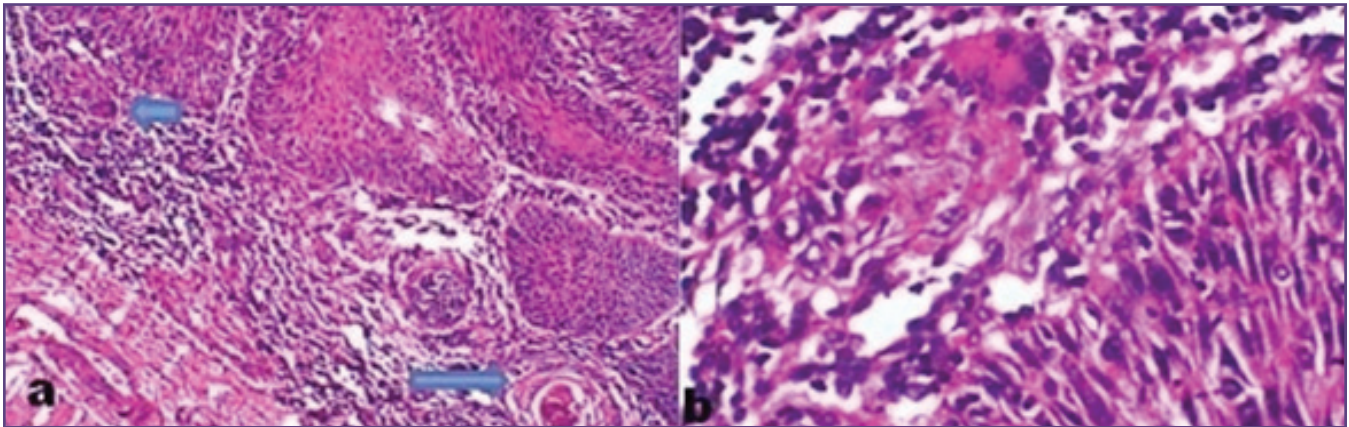


Fig. 3: Interpretation dilemma: pseudoepitheliomatous hyperplasia versus well-differentiated SCC with minimal invasion (a) predominantly hyperplastic rete ridges with intact basement membrane, dense inflammation in underlying stroma, subtle focus of atypical squamous cells (short arrow), keratin pearl in superficial stroma (long arrow), H&E, 100X. (b) Subtle focus of disrupted basement membrane and atypical squamous epithelial cells (H&E, 400X).

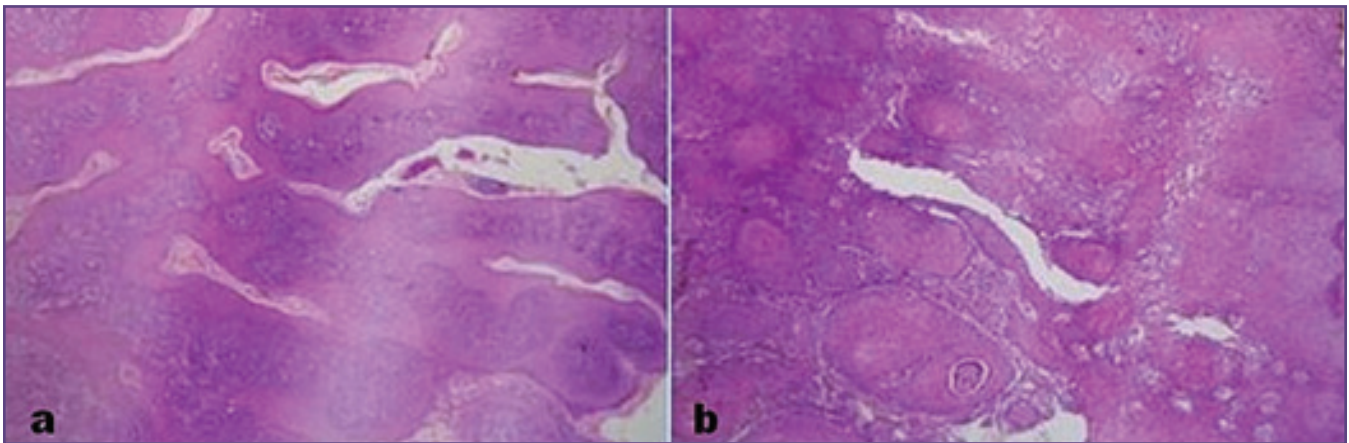


Fig. 4: Hyperplastic and hyperkeratotic squamous epithelium versus well-differentiated squamous carcinoma: (a) interanastomosing thick bands of well-differentiated squamous epithelium with minimal atypia (b) islands of well-differentiated squamous epithelium with intact basement membrane in the submucosa (H&E, 400X).

Discussion

Both benign and malignant lesions predominantly present as exophytic proliferative growth. This develops suspicion of cancer and causes apprehension in the minds of both patients and clinicians. Problems may occur at all stages of the histopathological diagnosis from the collection and orientation of specimen by the surgeon, processing of received tissues and interpretation.^[8]

In a superficial/inconclusive biopsy, the problem could be insufficient sampling by the surgeon. The biopsy taken may be of insufficient size and depth. It may be due to poor orientation of the tissue within the block. Therefore, utmost care should be taken right at the time of taking biopsy and subsequent processing. Generally, larger is the sample greater is the chance of an accurate diagnosis. Fixation causes shrinkage. Preferably, we suggest that the biopsy size should be 4-5 mm and not less than 2 mm. The greater size of tissue biopsy, allows for the shrinkage and permits the pathologist to better orient and cut the specimen avoiding tangential sectioning. Biopsy should be visualized under magnifying lens, to identify mucosa and underlying tissue accurately, and then wrapped in a filter paper with proper orientation so that both mucosa and underlying tissue remain parallel to the surface of paraffin block and are exposed to cutting edge of knife. All samples should be coloured by using eosin or bouin's fluid that impart pink or yellow colour respectively and chances of loss of tissue during processing are minimized.^[8,9]

Interpretation dilemma often occurs in distinguishing verrucous hyperplasia and verrucous carcinoma if incisional biopsy is not of sufficient depth and does not include adjacent normal epithelium. Therefore, surgeon should be asked to collect biopsy from the edge of the tumour, so that the sample includes normal adjacent tissue as well. Multiple biopsies should be collected in single sitting which will minimize the chances of insufficient sampling and will not develop the need of re-biopsy that will cause trouble to patient. For smaller, discrete lesions, an excisional biopsy may be more ideal.^[9,10]

Pathologists should be aware of the fact that Verrucous hyperplasia simulates Verrucous carcinoma, but are entirely exophytic, superficial and lack the downward proliferation of the rete pegs beyond the level of the adjacent squamous epithelium. Unlike this, verrucous carcinoma exhibits both upward and downward hyperplastic growth with orderly maturation and typically downgrowth is made up of bulbous, blunt rete pegs with pushing and well differentiated edges, and shows presence of neutrophils in the form of small intraepidermal abscesses. These are important diagnostic clues.^[11,12]

The precise histological categorisation or misinterpretation of mucosal lesions that include an exophytic growth component is a difficult and often encountered experience. Awareness of accurate definitions, clinical and histological characteristics can alleviate such problems and errors. For this pathologist need to keep their knowledge up to date by frequent reading and attending dermatopathology CME.

The diagnosis of OSCC is usually straight forward when island or cords or isolated malignant squamous epithelial cells are seen in between the submucosa connective tissue or skeletal muscle fibres or fat lobules or salivary gland lobules. This is unequivocal invasion. But interpretational error in the diagnosis of well differentiated squamous cell carcinoma may occur as section from incision biopsy may show on histology, tortuous centrally-keratinising columns of proliferated squamous epithelium with minimal cytologic atypia or unequivocal / submucosal invasion cannot be established or suspicion that whether 'Islands' of epithelium within the lamina propria, represented tangential cuts of rete processes, especially if these were long and bulbous as in some reactive conditions. Subepithelial brisk inflammatory reaction may cause difficulty in the assessment of breach in the continuity of the basement membrane and in turn compromise assessment of the invasive front.

In such cases If there is uncertainty whether or not invasion has occurred in a background of severe dysplasia, proliferative or not, the histology should be reported as lacking unequivocal evidence of invasion. Re-biopsy should be considered and surgeon should be informed of the dilemma.^[8]

In his review article Bruce M Weing also considered sampling as a major issue in the evaluation of SCC of the upper aerodigestive tract. He has stated that in the absence of adequate representative tissue including epithelial-to-stroma interface, one should be circumspect relative to a diagnosis of SCC. He has considered few benign lesions as diagnostic pitfalls in the diagnosis of SCC that include pseudoepitheliomatous hyperplasia, necrotizing sialometaplasia, juxtaoral organ of Chievitz, and radiation atypia. About verrucous carcinoma (VC) author has discussed that the pathologic diagnosis of VC may be extremely difficult. Both clinician and pathologists should be aware of this fact. To this end, adequate biopsy material is critical to interpretation and should include a good epithelial-stromal interface. The pathologist should not overinterpret a verrucoid lesion as a carcinoma without seeing the relationship to the underlying stroma.^[13]

Conclusion

Histopathology evaluation determines the accurate diagnosis and nature of the various exophytic proliferative lesions of the oral cavity.

To alleviate all problems of histopathology assessment, proper sampling, orientation of biopsy within the block, proper trimming of block, awareness of precise histopathology definitions, characteristic features of various entities, differential diagnosis and diagnostic algorithms provided by dermatopathologists is must, as accurate diagnosis carries prognostic implications.

Acknowledgements

Dr. A.D. Kalgutkar, Professor and HOD Pathology, LTMMC and LTMGH for her general support

Funding

None

Competing Interests

None declared

Reference

1. Stephen BE., David RB., Carolyn CC., April GF., Frederick LG., Andi T (Eds.): AJCC Cancer Staging Manual. Lip and Oral Cavity. 7th ed. Springer Verlag, New York 2009:29-41.
2. Barnes L., Everson J.W., Reichart P., Sidransky D. (Eds.): World Health Organization Classification of Tumors. Pathology and Genetics of Head and Neck Tumors. IARC Press: Lyon 2005:168.
3. Peter AH, Louis PD, John DP (Eds.): Washington manual of Surgical Pathology. Oral cavity and oropharynx. 1st ed. Lippincott Williams and Wilkins: USA 2008.
4. Noel W., Kurt M., Richard J.C., Suster S., Lawrence MW. (Eds.): Modern Surgical Pathology. Head and Neck. 2nd ed. (1). WB Saunders: Philadelphia 2009:1.
5. Crispian S., Oslei PA, Jose B, Pedro DD, Adalberto MT (Eds.): Oral Medicine and Pathology at glance. Swellings: reactive lesions. 1st ed. Wiley Blackwell: UK 2010.
6. Barnes L (Ed.): Surgical Pathology of Head and Neck. Benign and non neoplastic disease. 2nd ed. (1). Marcel dekker inc.: New York 2001: 239.
7. Glaros AG, Kline RB. Understanding of the accuracy of tests with cutting scores: The sensitivity, specificity, and predictive value model. Journal of clinical psychology, 1988;44(6); 1013-24.
8. Woolgar JA, Triantafyllou A. Pitfalls and procedures in the histopathological diagnosis of oral and oropharyngeal squamous cell carcinoma and a review of the role of pathology in prognosis. Oral Oncol, 2009;45; 361-85. doi: 10.1016/j.oraloncology.2008.07.016. Epub 2008 .Available from <http://www.ncbi.nlm.nih.gov/pubmed/18849188>.
9. Kumaraswamy K L, Vidhya M, Rao PK, Mukunda A. Oral biopsy: Oral pathologist's perspective. J Can Res Ther, 2012;8(2):192-8. Doi: 10.4103/0973-1482.98969 Available from <http://www.cancerjournal.net/text.asp?2012/8/2/192/98969>.
10. Poh CF, Ng S, Berean KW, Williams PM, Rosin MP, Zhang L. Biopsy and histopathologic diagnosis of oral premalignant and malignant lesions. J Can Dent Assoc 2008;74(3):283-8.
11. Mills SE, Carter D.(Eds): Sternberg's diagnostic surgical pathology. The jaws and oral cavity. 5th ed. (1). Wolters Kluwers/ Lippincot Williams &Willkins, Philadelphia 2010;789-90.
12. Santoro A, Pannone G, Contaldo M, Sanguedde F, Esposito V, Serpico R et al. A Troubling Diagnosis of Verrucous Squamous Cell Carcinoma ("the Bad Kind" of Keratosis) and the Need of Clinical and Pathological Correlations: A Review of the Literature with a Case Report. Journal of skin cancer, 2011. Available from <http://dx.doi.org/10.1155/2011/370605>
13. Weing BM. Squamous cell carcinoma of the upper aerodigestive tract: precursors and problematic variants. Mod Pathol 2002;15(3):229-54.