

Overexpression of Her2/Neu in Gastric Carcinoma: Association with Histological Type, Tumor Grade and H. Pylori Infection

Piyali Ghosh¹, Indranil Chakrabarti², Sourav Bhowmick³, Mimi Gangopadhyay², Mamata Guha Mallick Sinha⁴ and Sudip Bhattacharya⁵

¹Department of Pathology, Calcutta National Medical College, West Bengal, India

²Department of Pathology, North Bengal Medical College, Darjeeling, India

³Department of Pathology, Ruby General Hospital, West Bengal, India

⁴Department of Pathology, SSKM Hospital, West Bengal, India

⁵Department of Orthopedics, Habra State General Hospital, West Bengal, India

Keywords: Gastric Carcinoma, HER2, Helicobacter Pylori

ABSTRACT

Introduction: Gastric cancer is the second leading cause of cancer mortality in the world and its management, especially in advanced stages, has evolved relatively little. In particular, no targeted modality has so far been incorporated for treatment. HER2 over-expression is increasingly recognized as a frequent molecular abnormality, driven as in breast cancer by gene amplification. There is mounting evidence of the role of HER2 over-expression in patients with gastric cancer, and it has been strongly correlated to poorer outcomes and a more aggressive disease.

Aims and objective: The purpose of this study is to establish the clinicoepidemiological, histopathological and immunohistochemical particularities of the gastric carcinomas, and to identify the factors with a prognostic value.

Materials and methods: The present study included 54 cases of gastric carcinoma, who had undergone endoscopy guided biopsy or gastrectomy. Expression of HER2 oncoprotein by immunohistochemistry and detection of Helicobacter pylori was done using modified Giemsa stain. Expression of HER2 was correlated with patient's clinicopathological parameters.

Results: HER2+ rates were 22.22% (12/54). HER2 over-expression was associated with poorly differentiated carcinoma ($P = 0.0159$) and intestinal type of gastric carcinoma ($P=0.0245$).

***Corresponding author:**

Dr. Indranil Chakrabarti, Department of Pathology, North Bengal Medical College Sushrutnagar, District: Darjeeling, West Bengal, India-734012

Phone: + 91 9433187448

Email: drinch@rediffmail.com



Introduction

Gastric cancer is the fourth most commonly diagnosed malignancy and the second most common cause of cancer related death worldwide.^[1,2,3] Although there has been great improvement in the early diagnosis of gastric cancer, in combination with the recent progress of surgical techniques and comprehensive use of chemotherapy and radiotherapy, the 5-year survival rate for gastric cancer remains as low as 20% to 30%.^[4] In regard to gastric cancer, molecularly targeted therapy is also gaining status. There is mounting evidence of HER2 expression in gastric carcinoma correlating with poor outcomes and a more aggressive disease.^[5] According to the ToGA clinical trial reported in 2010^[6,7], patients with HER2 overexpression receiving chemotherapy and trastuzumab had a significant longer median overall survival without any additional adverse side effects. So, targeted therapy has great potential in improving the treatment of gastric cancer.

Helicobacter pylori (*H. pylori*), previously named *Campylobacter pyloridis*, is a Gram-negative, microaerophilic bacterium found in the stomach. It has been known that *H. pylori* have a major role in EGFR receptor expression in gastric mucosal cells.^[8] Changes like growth, proliferation and differentiation are observed with EGF receptor expression. This overexpression may cause development of gastric cancer. There are studies, which have indicated that EGF and EGFR levels were decreased in cells with *H. pylori* eradication.^[8]

The limited number of studies in the literature has investigated HER2 status both in gastric and its metastatic tissues. However, after extensive search the relationship of this status with *H. Pylori* has been found only in one recent study in this year. So, this study will be helpful for assessment of prognostic significance of HER2 in gastric carcinoma along with the role of anti *H. Pylori* medication in Her2 positive cases.

Aims and Objective: The present study was undertaken to evaluate the pattern and intensity of HER2/neu expression in different histomorphologic variants as well as grades of gastric carcinoma and to find out the frequency of *H pylori* infection in HER2/neu positive gastric carcinoma patients.

Materials and Methods

The study was carried out during the time period of one year from June 2011 to May, 2012 after obtaining the permission of Institutional Ethics Committee. A total of 54 histologically diagnosed cases of gastric carcinoma were included. All the relevant history was recorded. After conventional processing, paraffin sections of

5µm thickness were stained by haematoxylin and eosin (H and E) for histopathological study and modified Giemsa for detection of *H.pylori*. In addition, 4µm sections were cut from paraffin blocks of tumour tissue and taken on a glass slide coated with poly L lysine for immunohistochemistry (IHC) to detect HER2 overexpression. The technique for IHC included antigen retrieval in Tris-EDTA buffer by pressure cooker method, blocking endogenous peroxidase with 3% hydrogen peroxide, incubating with primary mouse monoclonal antibody against HER2 protein (CB11), linking with secondary antibody, enzyme labelling with streptavidin-horseradish peroxidase, developing chromogen with di-amino benzidine (DAB) and counterstaining with haematoxylin. Positive and negative controls were checked with each batch of slides. Statistical analysis was performed using Microsoft Excel and SPSS software version 11.5. The results were considered statistically significant if $p < 0.05$.

Results and Analysis

After data accumulation they were analysed and the following results were obtained.

A total number of 54 cases were included in the study and were morphologically classified as per Lauren classification of gastric carcinomas (Figure 1)

Regarding immunohistochemical staining for HER2/neu following data were obtained: 30 cases out of 54 cases (55.56%) showed negative staining (score 0 and 1+). Intense complete staining (score 3+) were detected in 12 cases (22.22%). The remaining 12 cases (22.22%) showed moderate partial membranous staining (2+) in >10% cells. (Table -1) (Figure 2)

Overexpression of HER2 oncoprotein was seen predominantly in patients over 50 years of age and male population.(Table -2&3)

Most of the cases showing HER2 over expression were intestinal type ($P= 0.0245$) except two cases where diffuse type showed positivity. No other histological variant (mixed and indeterminate type) showed positivity.(Table-4)

HER2 over expression was seen in 8 cases ($P=0.0159$) of high grade gastric carcinomas. (Table -5)

Among the 12 cases which showed positive staining of HER2 oncoprotein, *H. pylori* was detected in 2 cases (P value= 1) using modified Giemsa stain. (Table -6) (Figure 1D)

Discussion

In this study out of 54 gastric carcinoma only 12 cases were HER2 positive and HER2 status was correlated with

Table 1: Distribution of study population depending on the pattern of staining-

Pattern and intensity of staining of HER2 oncoprotein	No. of cases	Percentage (%)
No membrane staining or <10% of cells stained (score 0)	12	22.22
Faint/barely perceptible membranous reactivity In 10% of cells or higher or reactivity in only part Of the cell membrane (score 1+)	18	33.33
Weak to moderate complete or basolateral membranous reactivity in 10% of tumor cells or higher (score 2+)	12	22.22
Strong complete or basolateral membranous Reactivity in 10% of tumor cells or higher (score 3+)	12	22.22
Total	54	100

Table 2: Correlation of HER2 over expression with the age of the patients in this study population

Age of the patients	Pattern of HER2 overexpression (positive)	Pattern of HER2 overexpression (negative)	Analytical statistics
>50 years	9	26	Fisher exact probability test, P-value=0.5061 Df=1
≤50 years	3	16	

Table 3: Correlation of HER2/NEU over expression with the sex of the patients in this study population

Sex of the patients	Pattern of HER2 overexpression (positive)	Pattern of HER2 overexpression (negative)	Analytical statistics
Male	7	35	Chi-square test value= 0.05 with P-value 0.8229
Female	5	7	

Table 4: Correlation of HER2/NEU over expression with the histological type of the tumor in this study population-

Histological types	Pattern of HER2 overexpression (positive)	Pattern of HER2 overexpression (negative)	Analytical statistics
Intestinal	10	19	Fisher exact probability test, P value=0.0245 Df=1
Diffuse & others	2	23	

Table 5: Correlation of HER2/NEU over expression with the histological grade of the tumor in this study population-

Histological grade	Pattern of HER2 overexpression (positive)	Pattern of HER2 overexpression (negative)	Analytical statistics
Poorly differentiated	8	11	Fisher exact probability test, P value=0.0159 Df=1
Well & moderately differentiated	4	31	

Table 6: Correlation of HER2/NEU over expression with the active H. pylori infection in this study population-

Detection of H. pylori by modified Giemsa	Pattern of HER2 overexpression (positive)	Pattern of HER2 overexpression (negative)	Analytical statistics
Yes	2	9	Fisher exact probability test, P value=1 Df=1
No	10	33	

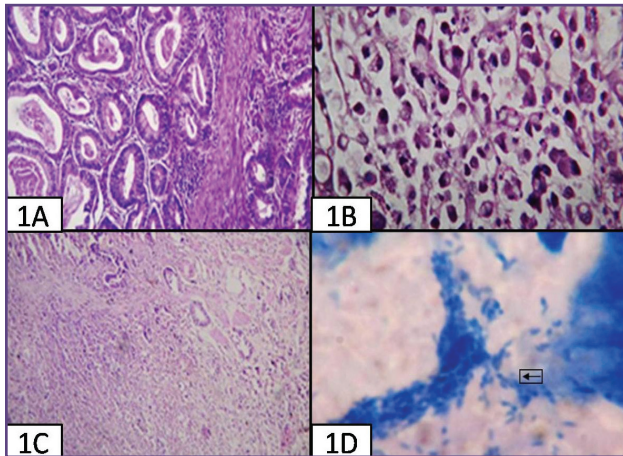


Fig. 1: Gastric carcinomas (A) Intestinal type (H&E stain; 100X). (B) Diffuse type with signet ring cells (H&E stain; 400X). (C) Mixed type with well differentiated glands and diffuse sheets of signet ring Cells. (D) H. Pylori in a case of gastric carcinoma (arrows) (Modified Giemsa Stain ; 1000X).

sex, being more frequent in men, with age at diagnosis (>50 years), more frequent in older patients which was similar to findings of previous studies by Yu G Zet al in 2009^[9], Moelans CB et al in 2011^[10] and Alina Bădescu et al in 2012.^[11] But Sekaran A et al in 2012 and Federica Grillo et al in their study in 2013 showed that there was no significant difference noted in HER2 overexpression or amplification when compared to age or sex of the patient or tumor site.^{[12],[13]}

Positive membranous staining (score 3+) was observed in 12 cases (22.22%). Sekaran A et al in their study in 2012 in Indian population showed that results of HER2 overexpression in Indian population were quite high (44.2%).^[12] Slesak B et al in 1998^[14], Takehana T^[15] in 2002 and many other studies reported that HER2 was over-expressed in gastric carcinomas at a range of 8% to 56%.

In 30 cases (55.56%) of our study there was negative staining (score 0 and 1+). The remaining 12 cases (22.22%) showed moderate partial membranous staining (2+). Study of Federica Grillo et.al. in 2013^[13] showed only 24% of IHC-positive (score 3+). These findings have also been described by Kim et al in 2011.^[16]

Most of the cases (10 cases; 83.33%) of HER2 over expression were intestinal type. The remaining two cases were diffuse type. These associations were found to be statistically significant with a P value of 0.0245. No other histological variant (mixed and indeterminate type) showed positivity. Jan Trøst Jørgensen et al in their study in 2012^[17]

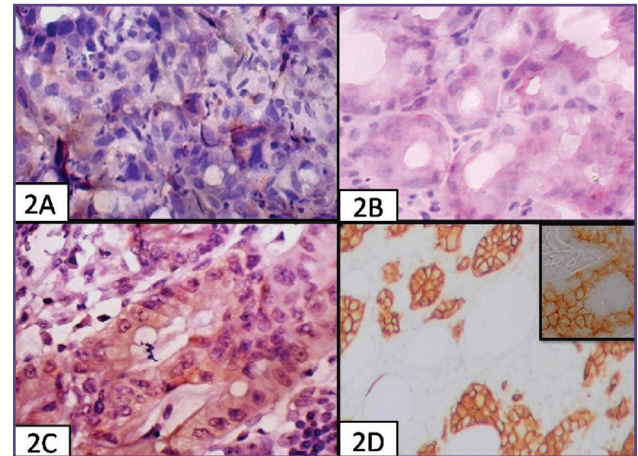


Fig. 2: HER2/neu positivity of gastric carcinomas A: HER2 Score 0 (400X) (B) HER2 Score 1+ (400X) (C)HER2 Score 2+ (400X) (D) HER2 Score 3+ (100X)

observed that in the current review that based on the Lauren classification in relation to HER2, a higher level of overexpression or amplification was found in the intestinal phenotype compared to the diffuse or mixed types.

M. Tanner et al in their study in 2012^[18] told that HER2 over expression was strongly associated with the intestinal type as defined according to Lauren's classification (21.5% versus 2.2% in the diffuse type, $P = 0.0051$). Alina Bădescu et al in their study in 2012^[11], observed that the overexpression of Her2 was more frequent in intestinal type than diffuse (66.67% vs.20%), with a statistical significance difference between the two histological types ($p=0.01$), the picture also reflecting in other studies of previous years like study of Park DI et al in 2006^[19] and Zhang XL in 2009^[20]. Sekaran et al in 2012^[12] studied HER2 expression in 52 patients of gastric adenocarcinoma in Hyderabad, India. Twenty three of 52 patients showed HER2 over-expression. They found similar overexpression of HER2 in both intestinal and diffuse histological types.

In this study HER2/neu over expression was positive in 8 cases of poorly differentiated gastric carcinomas among 12 positive cases with a statistical significance difference between the two histological grade (poorly differentiated versus well and moderately differentiated) ($p=0.0159$). Most studies have shown that it is more common in cases of well-differentiated gastric carcinomas like the study of Zhang XL et al in 2009^[20], Cidon EU et al in 2011^[21], Alina Bădescu et al in 2012^[11] But they added that positive staining was also found in poorly differentiated carcinomas

indicates that HER2 is not uniquely linked to a specific differentiated type.

In this study among 12 cases (which showed positive staining for HER2) 2 cases showed active H. pylori infection which were detected using modified Giemsa stain with P value of 1. So, in our study correlation between H. pylori and HER2 over-expression was found to be statistically insignificant. After extensive search of the literature, we have found no other study stating the correlation between H. pylori and HER2 over-expression. But in one study **Fatih Selcukbiricik et al in 2013 proposed the fact that H. pylori positive cases may have poor prognosis due to possible HER2 positivity metastasize in lymph nodes in gastric carcinoma patients.**^[8]

Conclusion

In this study, HER2 expression was seen more in intestinal type of gastric carcinoma as compared to the diffuse type involving mostly poorly differentiated cases. Regarding H. pylori, we found no correlation between its presence and the over-expression of HER2. So, the results of this study may contribute to a better knowledge of the efficacy of trastuzumab-based therapy in HER2 positive gastric cancers but the outcome of anti H. pylori medication in HER2 positive cases still remain inconclusive.

Acknowledgements

None

Funding

None

Competing Interests

None declared

References

1. Hu B, El Hajj N, Sittler S, Lammert N, Barnes R, Meloni-Ehrig A. Gastric cancer: Classification, histology and application of molecular pathology. *J Gastrointest Oncol* 2012;3(3):251-61
2. Parkin DM. International variation. *Oncogene* 2004; 23:6329-40.
3. Ferlay J, Shin HR, Bray F, Forman D, Mathers C, Parkin DM. Estimates of worldwide burden of cancer in 2008: GLOBOCAN 2008. *Int J Cancer* 2010; 127:2893-917.
4. Wang S, Zheng G, Chen L, Xiong B. Effect of HER-2/neu Over-expression on Prognosis in Gastric Cancer: A Meta-analysis. *Asian Pacific J Cancer Prev*; 12:1417-23.
5. Meza-Junco J, Sawyer MB. Metastatic gastric cancer - focus on targeted therapies. *Biologics* 2012; 6:137-46.
6. Han HS, Lauwers GY. Gastric Carcinoma. Available from- [http://www.dako.com/28830_14dec10_connection15_HER2 in Gastric cancer.pdf](http://www.dako.com/28830_14dec10_connection15_HER2_in_Gastric_cancer.pdf).
7. Bang YJ, Van Cutsem E, Feyereislova A, Chung HC, Shen L, Sawaki A, et al. Trastuzumab in combination with chemotherapy versus chemotherapy alone for treatment of HER2-positive advanced gastric or gastro-oesophageal junction cancer (ToGA): a phase 3, open-label, randomised controlled trial. *Lancet* 2010;376:687-97.
8. Selcukbiricik F, Tural D, Erdamar S, Buyukunal E, Demirelli F, Serdengeci S. Is Helicobacter pylori a poor prognostic factor for HER-2 SISH positive gastric cancer? *Asian Pac J Cancer Prev*. 2013;14(5):3319-22.
9. Yu GZ, Chen Y, Wang JJ. Overexpression of Grb2/HER2 signaling in Chinese gastric cancer: their relationship with clinicopathological parameters and prognostic significance. *J Cancer Res Clin Oncol*, 2009, 135(10):1331-39.
10. Moelans CB, Milne AN, Morsink FH, Offerhaus GJ, van Diest PJ. Low frequency of HER2 amplification and overexpression in early onset gastric cancer. *Cell Oncol* 2011; 34: 89-95.
11. Bădescu A, Georgescu CV, Vere CC, Crăițoiu S, Grigore D. Correlations between HER2 oncoprotein, VEGF expression, MVD and clinicopathological parameters in gastric cancer. *Rom J Morphol Embryol* 2012; 53(4):997-1005.
12. Sekaran A, Kandagaddala RS, Darisetty S, Lakhtakia S, Ayyagari S, Rao GV, et al. HER2 expression in gastric cancer in Indian population-An immunohistochemistry and fluorescence in situ hybridization study. *Indian J Gastroenterol*. 2012; 31(3):106-10.
13. Federica Grillo, Matteo Fassan, Chiara Ceccaroli, Cinzia Giacometti, Monica Curto, Vittorina Zagonel et al. The reliability of endoscopic biopsies in assessing HER2 status in gastric and gastroesophageal junction cancer: a study comparing biopsies with surgical samples. *Translational Oncology*, 2013;6(1):10-16.
14. Slesak B, Harlozinska A, Porebska I, Bojarowski T, Lapinska J, Rzeszutko M, et al. Expression of epidermal growth factor receptor family proteins (EGFR, c-erbB-2 and c-erbB-3) in gastric cancer and chronic gastritis. *Anticancer Res* 1998;18:2727-32.
15. Takehana T, Kunitomo K, Kono K, Kitahara F, Iizuka H, Matsumoto Y et al. Status of c-erbB-2 in gastric adenocarcinoma: a comparative study of immunohistochemistry, fluorescence in situ hybridization and enzyme-linked immuno-sorbent assay. *Int J Cancer* 2002;98:833-7.

16. Kim KC, Koh YW, Chang HM, Kim TH, Yook JH, Kim BS et al. Evaluation of HER2 protein expression in gastric carcinomas: comparative analysis of 1,414 cases of whole-tissue sections and 595 cases of tissue microarrays. *Ann Surg Oncol* 2011; 18, 2833–40.
17. Jan Trøst Jørgensen, Maria Hersom. HER2 as a Prognostic Marker in Gastric Cancer - A Systematic Analysis of Data from the Literature. *Journal of Cancer* 2012; 3: 137-44.
18. Tanner M, Hollmen M, Junttila TT, Kapanen AI, Tammola S, Soini Y et al. Amplification of HER-2 in gastric carcinoma: association with Topoisomerase II alpha gene amplification, intestinal type, poor prognosis and sensitivity to trastuzumab. *Ann Oncol* 2005; 16:273–78.
19. Park DI, Yun JW, Park JH, Oh SJ, Kim HJ, Cho YK, et al. HER-2/neu amplification is an independent prognostic factor in gastric cancer. *Dig Dis Sci.* 2006;51(8):1371-9
20. Zhang XL, Yang YS, Xu DP, Qu JH, Guo MZ, Gong Y et al. Comparative study on overexpression of HER2/neu and HER3 in gastric cancer. *World J Surg.* 2009 Oct;33(10):2112-8.
21. Cidon EU, Centeno RG, Lagarto EG, Peral JI. HER-2 Evaluation in a Specific Gastric Cancer Population with the Highest Rate of Mortality in Spain, *J Oncol* 2011; 2011:391564.