

Histopathological Analysis of Unusual Findings in Appendectomy Specimens: A Retrospective Study and Literature Review

Dhiraj B. Nikumbh^{1*}, Rajesh Y. Thakur², Sudhir Singhavi³ and Shirish Gondane¹

¹Dept of Pathology, JMF'S ACPM, Medical college, Dhule, India

²Dept of Pathology, SBH, GMC, Dhule, India

³Consultant Pediatric Surgeon, Dhule, India

Keywords: *Appendicitis, Unusual Findings, Carcinoid Tumor, Histopathological Analysis.*

ABSTRACT

Background: Acute appendicitis has remained a clinical entity and an ongoing diagnostic challenge. Appendicitis is one of the commonest surgical emergencies. However, histopathological studies are the gold standards for diagnosis of acute appendicitis. Though faecoliths are the usual cause of obstruction, other unusual findings can be the cause too, ranging from inflammatory conditions to malignancies.

Aims and Objectives: To document and compare unusual histopathological findings in appendectomy specimens in our center.

Methods: The clinicopathological records of resected appendices submitted to histopathology department over the period of 4 years from January 2012 to December 2015 were reviewed retrospectively. From accumulated information from 790 appendectomies, 44 appendectomy specimens had unusual histopathological findings were included in the study. Patient who underwent incidental appendectomy during other surgeries were excluded from the study.

Results: Out of 790 appendectomy specimens, acute appendicitis accounted for 302(38.2%) with peak occurrence in the age group 11-20 years (38.9%) and 21-30 years (27.7%) with male predominance (2.34:1). Unusual findings were noted in 44 (5.6%) cases by histopathology. Most common findings included obliterative appendicitis (77.3%), followed by eosinophilic appendicitis (6.8%) and granulomatous appendicitis (4.5%). Other unusual findings include diverticulum, mucocele, carcinoid and signet ring adenocarcinoma of the appendix.

Conclusion: The gross examination at the time of surgery cannot detect all the abnormalities of the appendix. Although unusual or co-existing pathologies can be rarely seen during appendectomy, all the appendectomy specimens should be sent for routine histopathological examination to avoid missing of any clinically important and treatable condition.

***Corresponding author:**

Dr Dhiraj B Nikumbh, Associate Professor,
Dept of Pathology, JMF'S ACPM, Medical College, Dhule, Maharashtra, India.
Email: drdhirajnikumbh@rediffmail.com

Introduction

Appendicitis is one of most common acute surgical conditions of the abdomen and an appendectomy is one of the most frequent performed operations worldwide. [1] The life time risk for appendicitis is 7% commonly occurring in adolescent and young adults. In developing countries like India, the incidence is increasing in most urban centers, probably due to adoption of western diet. [2]

Despite of advances in technology and imaging modalities, there is dilemma in the clinical diagnosis of acute appendicitis. Histopathological examination still remains the gold standard method for confirmation of appendicitis. [2] Obstruction of lumen is the dominant factor in acute appendicitis and although faecoliths and lymphoid hyperplasia are the usual cause of obstruction, some unusual factors could be involved. [3] Unusual causes of obstructions are enterobiasis, ascariasis, tuberculosis, carcinoid tumor ,primary or secondary adenocarcinoma, lymphoma, dysplastic changes, mucocele, gastro-intestinal stromal tumor, eosinophilic granuloma etc. [3] Even though , there are many case reports in English written medical literature, reports with meticulous analysis of all cases with appendicitis are small in number. [4-8]

The aim of the present study is to determine the various histological diagnoses of surgically removed appendices and to find out unusual factors for appendicitis and compare them with other researchers.

Material and Methods

The present study was conducted in Hi-Tech Diagnostic center, Dhule and GMC, Ambajogai. Total of 790 specimen of appendices were received in the histopathology department during a period of 4 years from January 2012 to December 2015 and were reviewed retrospectively, with special reference to age , sex, operative and histology reports.

All the surgically resected appendices submitted to the department of Pathology were included in this retrospective study. Patient who underwent incidental appendectomy during other surgeries and negative appendectomies were excluded from the study. Histopathological reports were analyzed according to diagnosis and unusual findings were noted and data was compared.

Results

Total of 790 specimens of appendices were received in the histopathology department during the period of 4 years from January 2012 to December 2015. Out of 790 appendicitis (clinically diagnosed on the physical and

laboratory examination), 44 specimens (5.6%) were with unusual histopathological findings after final pathological evaluation. The peak age incidence of appendicitis was found in the age group 11-20 years with 38.9% (Table No. 1).

Table 1: The distribution of acute appendicitis cases according to age group.

Sr.No	Age group	No. Of cases	Percentage (%)
1	0-10	68	8.6
2	11-20	307	38.9
3	21-30	218	27.7
4	31-40	118	14.9
5	41-50	69	8.7
6	>51	10	1.2
	Total	790	100

There were 554(70.1%) males and 236 (29.9%) females among 790 cases of appendicitis with male: female ratio 2.36:1 (Table No. 2).

Table 2: The distribution of acute appendicitis cases according to sex

Gender	No. Of cases	Percentage (%)
Male	554	70.1
Female	236	29.9
Total	790	100

After the final histopathological analysis in 790 cases of appendicitis, majorities were acute appendicitis (38.9%) and unusual findings were noted in 44 (5.6%) cases. (Table No. 3).

Table 3: The varied spectrum of histopathological diagnoses of appendicitis.

Sr.No	HPE diagnosis	No. Of cases	Percentage (%)
1	Acute nonspecific appendicitis	302	38.2
2	Acute perforative/obliterative appendicitis	78	9.9
3	Acute suppurative/necrotizing appendicitis	63	7.9
4	Recurrent /follicular appendicitis	75	9.5
5	Chronic nonspecific appendicitis	225	28.5
6	Gangrenous appendicitis	03	0.4
7	Unusual appendicitis	44	5.6
	Total	790	100

In Unusual findings of appendicitis on histology, acute on chronic obliterative appendicitis was observed in majority of the cases (77.3%) followed by acute eosinophilic appendicitis (6.8%) and granulomatous appendicitis (4.5%).

In rare histopathological findings, we found single case of diverticulum of appendix, carcinoid tumor and mucocele (2.3%) respectively. The signet ring adenocarcinoma was seen in 2 cases (4.5%) (Table No.4). There were no unusual findings like *E.vermicularis*, *T.saginata* and Non Hodgkin's lymphoma (NHL) in our study.

Table 4: Unusual findings on histology

Sr. No.	Unusual/rare finding	No. Of cases	Percentage (%)
1	Chronic obliterative appendicitis	34	77.3
2	Acute eosinophilic appendicitis	03	6.8
3	Granulomatous appendicitis	02	4.5
4	Diverticulum appendicitis	01	2.3
5	Mucocele appendix	01	2.3
6	Carcinoid appendix	01	2.3
7	Signet ring adenocarcinoma	02	4.5
8	<i>E.vermicularis</i> and parasites	Nil	-
9	NHL	Nil	-
10	Leiomyoma of appendix	Nil	-
	Total	44	100

Discussion

Acute appendicitis is the most common surgical emergency for a number of decades and the appendectomy is the most frequently performed abdominal operation.^[9] Obstruction of the lumen seems to be the essential for developing an appendiceal infection. Although faecoliths and lymphoid hyperplasia are the usual causes of the obstruction, some unusual factors could also be involved.^[10-14]

The present study on unusual findings of appendix on histology(5.6%) is compared with Abdul rehman Salem Al Mulnin^[11], Emre A et al.^[13] and Menon I et al.^[14] Duzgun AP et al.^[10] and Akbulut S et al.^[12] found 0.7% and 1% respectively. (Table No.5).

Table 5: Comparison of Unusual HPE findings

Sr. No.	Authors (year)	Period of study (years)	No. of cases	Unusual findings on HPE	Percentage (%)
1	Duzgun AP et al. ^[10] (2004)	6	2458	19	0.70
2	Abdul rehman Salem Al Mulhim ^[11] (2011)	3	1324	67	5.10
3	Akbulut S et al. ^[12] (2011)	4.8	5262	54	1.02
4	Emre A et al. ^[13] (2013)	4	1255	88	7.00
5	Menon I et al. ^[14] (2014)	7	2157	138	6.40
6	Present study (2015)	4	790	44	5.60

We encounter mostly chronic obliterative appendicitis as unusual finding (77.3%) due to faecoliths (Fig 1a &2a). Lymphoid hyperplasia was noted mostly in first decades of the life. Development of the luminal obstruction, regardless of etiology has been proposed as the most significant factor in the etiopathogenesis of acute appendicitis. The most common cause of unusual findings by Emre A et al.^[13] was fibrous obliteration (64.8%) due to neurogenic proliferation. Such findings were not seen in our study.

The histological criterion for the diagnosis of acute appendicitis is polymorphonuclear leucocytic infiltration of the muscularis mucosa. The incidence of primary chronic appendicitis as a pathologic or clinical entity has been greatly disputed. Much more frequently recurrent acute attacks may be inappropriately referred to as chronic appendicitis. Extensive fibrosis of the appendiceal architecture implies a chronic inflammatory reaction within the wall, supports the diagnosis of chronic obliterative appendicitis. The appendectomy resolves the chronic appendicitis. Recurrent appendicitis especially in children occurs due to hyperplasia of lymphoid follicles in the wall, some other causes in the adults are due to excess mucin production.^[10-14] The diagnosis of chronic and recurrent is clinically important due to its different causes. Recurrent right iliac fossa pain in mainly females may be due to many other gynecology causes including chronic appendicitis. The complications and follow up of varied diagnosis is different.

Acute eosinophilic appendicitis was noted in 3 cases in present study (Fig 1b&2b). Same was comparable with Emre A et al.^[13] in one case only. Specifically eosinophilic appendicitis may be presented as obliterative appendicitis due to fibrosis.^[15] Tally et al.^[16] given the strict criteria for eosinophilic appendicitis as-Presence of gastrointestinal

symptoms, biopsies demonstrating eosinophilic infiltration of one or more cases of GIT and no evidence of parasitic or extrinsic disease. All the criteria's were fulfilled by our cases. Postoperatively, Stool examination was negative for ova, cyst or worm infestation on three separate occasions. Granulomatous appendicitis was observed in two cases (4.5%) in our study. Tuberculosis is known to be a disease of developing countries. The GI system is ranked sixth among all extrapulmonary involvements.^[12] The appendix may be affected secondary to ileocecal tuberculosis but appendicular tuberculosis may occur in an even rarer primary form without any evidence of the disease elsewhere.^[12] The reported incidence of appendicular tuberculosis varies from 0.1 to 3% among all appendectomies performed.^[12] An accurate diagnosis is usually established after histopathological examination of specimen. Histopathologically, submucosal caseating granuloma and Langhans giant cells suggesting tuberculosis of the appendix (Fig 1c&2c). The transmural inflammation was not there in our case with no fissure formation. Ziehl Neelsen stain (20%) showed few acid fast bacilli in our case. Histologically we are able to differentiate the other differential such as Crohns disease or malignancy.

Appendicular diverticula are very rare and the reported incidence in appendectomy specimen has ranged from 0.004 to 2.1%^[17,18]. It may be single or multiple, congenital or acquired and usually smaller than 0.5 cms located within the distal third of appendix on the mesenteric border.^[13] Acquired diverticulum is more prevalent than congenital consisting of mucosa and subserosa herniated through vascular cleft in the muscular layer.^[13] It usually asymptomatic, but the most common complications such as perforation and infection can cause abdominal pain that mimics acute appendicitis.^[17,18] We found only one case (2.3%) of appendicular diverticula as compared with Emre A et al.^[13] (Fig 1e)

We found one case of mucocele of appendix was presented with eosinophilic appendicitis.^[19] First described in 1842, mucocele is an obstructive dilatation of appendix resulting from intraluminal accumulation of mucoid material.^[19] (fig 1d). The incidence of this condition in appendectomy specimens has been described as retention cyst, mucosal hyperplasia, mucinous cystadenoma and cystadenocarcinoma.^[13] Emre A et al^[13] also found only one case of mucocele, comparable with our study.

An appendiceal carcinoid tumor is considered the most common type of appendiceal primary malignant lesion and accounts for almost 60% of all appendiceal tumors.

^[20] An appendiceal carcinoid tumor is found in 0.3 – 2.27 % of patients undergoing an appendectomy.^[13] It is rare for carcinoids to be diagnosed preoperatively, they are usually found incidentally during appendectomy.^[12,20]; as in our case. The 13 years female patient presented with acute appendicitis with perforation with tiny nodule of 0.6 cms at tip of appendix (fig .1f).

In 70-85% of cases, the carcinoid tumors are less than 1cm and are located at the tip of appendix.^[12] The majority of appendiceal carcinoids are benign and metastasis is rare. A near zero rate, of calculated risk of metastasis from tumor less than 1 cm allow for management by simple appendectomy as in our case. However greater than 2cms are associated with increased risk of metastasis, usually managed by right hemicolectomy.^[10,12,20] Histologically comprises of nest of uniform monotonous cells with salt and pepper chromatin (fig 2d&e). Akbulut S et al.^[12] and Emre A et al.^[13] found 5 and 11 cases of carcinoid tumors in view of larger studies.

In present study, we found 2 cases of signet ring adenocarcinoma in older patients with characteristic histology of signet ring cells in mucoid background (Fig 2f). Primary adenocarcinoma of appendix is an extraordinary rare tumor and its incidence was 0.01% as per Akbulut S et al.^[12]. It behaved aggressively hence oncologic resection with right hemicolectomy is the treatment of choice.^[10,12] Our both cases were secondarily involved adenocarcinoma from colon on further exploration. There was no unusual findings like E.vermicularis, Non Hodgkin's Lymphoma, Neuroma, Leiomyoma in our study and comparable with Akbulut S et al.^[12] and Emre A et al.^[13]

Conclusion

Right iliac fossa pain has the many differentials depends on the age group. Obstruction of the lumen is the dominant factor in acute appendicitis and although faecoliths and lymphoid hyperplasia are the usual causes of obstructions, some unusual factors could also be involved. Most appendiceal carcinoids and primary adenocarcinoma are diagnosed incidentally during surgery for acute appendicitis.

Certainly early diagnosis of cancer and initiation of treatment is extremely beneficial for patient's survival. Hence, even when appendectomy specimen shows normal macroscopic features, complete histopathological analysis may provide clinically useful insights into patient's condition and help to improve patient outcome by revealing a previously unrecognized disease.

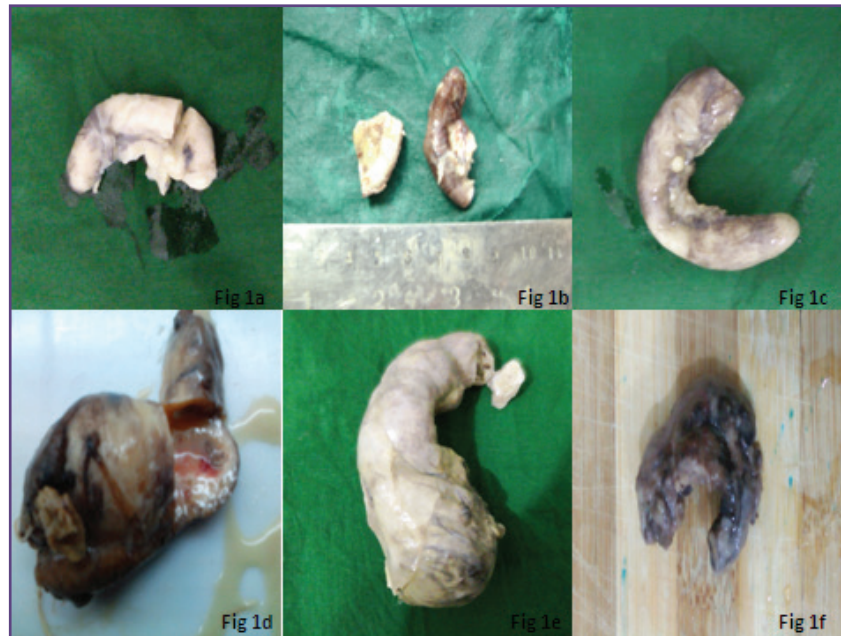


Fig. 1: Gross features of unusual findings in appendectomy specimens.
 a) Obliterative appendicitis with lumen completely obliterated by faecoliths
 b) Eosinophilic appendicitis also presented with fibrosed and occluded lumen
 c) Granulomatous appendicitis with tiny whitish tubercle on serosal aspect
 d) Mucocele on cut section with dilated lumen and thick wall with mucoïd fluid exudation
 e) Diverticulum of appendix with large, dilated lumen and congested blood vessels on serosal aspect
 f) Carcinoid tumor at tip of appendix presented with perforative appendicitis covered with brown exudation

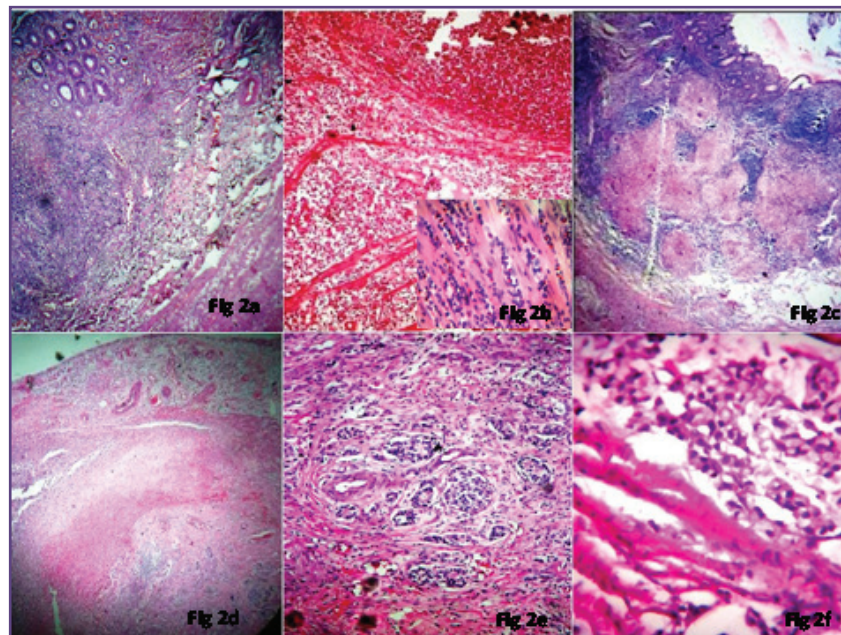


Fig. 2: Unusual histopathological findings.
 a) Chronic obliterative appendicitis with fibrous obliteration and lymphocytic infiltration (H&E, x100).
 b) Eosinophilic appendicitis. The muscularis propria of appendix with dense and diffuse infiltration by eosinophils (H & E, x100) , Inset(H & E, x400).
 c) Granulomatous appendicitis. Submucosal granuloma with caseation necrosis (H & E, x100).
 d) Carcinoid tumor presenting ulceration of the mucosa with submucosal tumor (H & E, x100)
 e) Nests of uniform tumor cells with salt and paper chromatin in submucosa (H & E, x400)
 f) Signet ring adenocarcinoma with characteristics signet ring cells with eccentric nucleus and vacuolated cytoplasm (H & E, x400)

Acknowledgements

None

Funding

None

Competing Interests

None Declared

References

1. Turner JR. The Gastrointestinal tract, In: Kumar, Abbas, Fausto (eds). Robins and Cotran Pathologic basis of disease. 8th edn. Saunders: Philadelphia; 2010. pp870-1.
2. Oguntola AS, Adeoti ML, Oyemolade TA. Appendicitis: Trends in incidence, age, sex, and seasonal variations in South-Western Nigeria. *Ann Afr Med* 2010;9:213-7.
3. Agarwala N, Liu CY. Laparoscopic appendectomy. *J Am As-soc Gynecol Laparosc* 2003; 10: 166-168
4. Ojo OS, Udeh SC, Odesanmi WO. Review of the histopathological findings in appendices removed for acute appendicitis in Nigerians. *J R Coll Surg Edinb* 1991;36:245-8.
5. Ross E, Ruiz ME. Pathology of the cecal appendix in our country. An analysis of 936 surgical specimens of appendectomy. *GEN* 1995;49:140-4.
6. Blair NP, Bugis SP, Turner LJ, MacLeod MM. Review of the pathologic diagnoses of 2,216 appendectomy specimens. *Am J Surg* 1993;165:618-20
7. Royes CA, DuQuesnay DR, Coard K, Fletcher PR. Appendectomy at the University Hospital of the West Indies (1984-1988). A retrospective review. *West Indian Med J* 1991;40:159-62.
8. Butler C. Surgical pathology of acute appendicitis. *Hum Pathol* 1981;12:870-8.
9. Shrestha R, Ranabhat SR, Tiwari MHistopathologic analysis of appendectomy specimens. *Journal of Pathology of Nepal* (2012) Vol. 2, 215 - 219
10. Duzgun AP, Moran M, Uzun S, Ozmen MM, Ozer VM, Seckin S et al. Unusual findings in appendectomy specimens: Evaluation of 2458 cases and review of the literature. *Indian J Surg* 2004; 66: 221-226
11. Abdulrahman Saleh Al-Mulhim. Unusual findings in appendectomy specimens: Local experience in Al-Ahsa region of Saudi Arabia. *Journal of Clinical Pathology and Forensic Medicine*. 2011; 2(1): 40-41.
12. Akbulut S, Tas M, Sogutcu N, Arikanoglu Z, Basbug M, Ulku A. Unusual histopathological findings in appendectomy specimens: a retrospective analysis and literature review. *World J Gastroenterol*. 2011;17(15):1961-1970
13. Emre A, Akbulut S, Bozdag Z, Yilmaz M, Kanlioz M, Emre R et al. Routine Histopathologic Examination of Appendectomy Specimens: Retrospective Analysis of 1255 Patients *Int Surg*. 2013 Oct-Dec; 98(4): 354-362
14. Memon I, Moorpani K, Rehman S. Unusual histopathological findings of appendectomy specimens. *Pak J Med Dent* 2014; 3(3):3-7.
15. Kanthikar SN, Nikumbh DB, Desale SS. Primary Eosinophilic Obliterative Appendicitis. *Online J Health Allied Scs*. 2014;13(1):6.
16. Talley NJ, Shorter RG, Phillips SF, Zinsmeister AR. Eosinophilic gastroenteritis: A clinicopathological study of patients with disease of the mucosa, muscle layer, and subserosal tissues. *Gut*. 1990;31:54-8.
17. Manzanares-Campillo Mdel C, Pardo-García R, Martín-Fernández J. Appendicular pseudodiverticula and acute appendicitis. Our 12-year experience. *Rev Esp Enferm Dig*. 2011;103(11):582-585
18. Coulier B, Pierard F, Malbecq S. Appendicular diverticulitis in an Amyand's hernia. *JBR-BTR*. 2010;93(2):114.
19. Sunil V Jagtap, Dhiraj B Nikumbh, Ashok Y Kshirsagar, Sujata R Kanetkar, Ashish Bohra. Eosinophilic appendicitis presented as mucocele: a rare clinical entity. *IJHSR*. 2012;2(2):99-103.
20. Shapiro R, Eldar S, Sadot E, Venturero M, Papa MZ, Zippel DB. The significance of occult carcinoids in the era of laparoscopic appendectomies. *Surg Endosc* 2010; 24: 2197-2199