

Cyodiagnosis of Schwannoma of Parotid Gland: A Rare Entity in a Child

Nishat Afroz¹, Shagufta Qadri*¹, Sunanda Chauhan¹ and S Abrar Hasan²

¹Department of Pathology, Jawaharlal Nehru medical College, Aligarh Muslim University, Aligarh, U.P., India

²Department of Otorhinolaryngology, Jawaharlal Nehru medical College, Aligarh Muslim University, Aligarh, U.P., India

Keywords: *Intra-parotid, Schwannoma, FNAC, Cytological Findings*

ABSTRACT

Schwannoma of parotid gland in a child is rare. We report a rare case of schwannoma in parotid gland in a 10-year-old child who presented with a gradually enlarging swelling in parotid region for the last 1 year. Color doppler study showed increased vascularity in the lesion with venous return pattern, suggestive of a hemangioma. However, fine needle aspiration cytology showed features consistent with schwannoma, comprising of sheets of uniform spindled cells with nuclei having tapering ends and exhibiting subtle nuclear palisading within a hypocellular fibrillary stromal background. The parotid mass was then excised. Histopathological and immuno- histochemical examinations further yielded the diagnosis of schwannoma, confirming the cytological diagnosis. This case report emphasizes that the cyodiagnosis of schwannoma is difficult due to many pitfalls encountered in fine needle aspirate. Therefore, schwannoma should always be considered in differential diagnosis of spindle-cell lesion in salivary glands even in children for early diagnosis and appropriate treatment. Unless schwannoma is included in the cytologic differential diagnosis, the surgeon may fail to recognize it at operation and may inadvertently transect the facial nerve.

***Corresponding author:**

Dr Shagufta Qadri, Assistant Professor , Department of Pathology, Jawaharlal Nehru medical College (JNMC), Aligarh Muslim University (AMU), Aligarh, U.P., India PIN: 202002

Phone: +91 9897532879

E-mail: qadridrshagufta@gmail.com



Introduction

Schwannomas (neurilemmomas) are common benign peripheral nerve sheath tumors composed of a relatively uniform spindle cells showing schwannian differentiation. Occurrence of schwannoma in parotid gland is extremely rare, accounting for only 0.2–1.5 % of all parotid tumors.^[1] The cytological diagnosis of schwannoma in parotid gland is rarely reported in literature and is difficult usually due to low yield of cells or paucicellularity in fine needle aspirates, combined with its varied cytomorphology, contributing to its wide differential diagnosis, mimicking a reactive or inflammatory process with spindle cell morphology or even a malignant spindle cell neoplasm.^[2,3,4] This case is being reported for its rare occurrence at unusual site in a child and its distinctive cytological appearance.

Case report

A 10-year old boy presented with a slow growing painless swelling in the left parotid region from the last 1 year. There was no significant family history or hereditary predisposition. No history suggestive of systemic infection, any autoimmune disease or trauma at the site of swelling was present. Clinical examination revealed an ill-defined, firm, non-tender, mobile mass, measuring 3 × 3 cm in size and extending from the zygomatic arch to short of angle of mandible and from pre-auricular region to anterior border of masseter in vertical and horizontal planes, respectively (Figure 1a). Facial nerve functions were found to be normal. Ultrasound imaging of the mass showed a well-defined heterogenous lesion in the left parotid gland. Color Doppler study revealed increased vascularity with multiple vascular channels showing venous flow pattern (Figure 1b), suggestive of a hemangioma. Fine

needle aspiration (FNA) smears were obtained with a 22 gauge needle and stained with Hematoxylin and Eosin (H&E) and Papanicolaou (Pap) stains. The FNA cytology revealed high cellularity smears, comprising of sheets of uniform spindle cells with nuclei having tapering ends and exhibiting subtle nuclear palisading within a hypocellular fibrillary stromal background (Figure 2a and 2b). There was no significant nuclear atypia, mitoses or any evidence of necrosis. The diagnosis of schwannoma was made on cytomorphological features. The mass was then excised and submitted for histopathological examination, which showed features consistent with schwannoma, comprising of well-circumscribed, encapsulated tumor with cells having morphology varying from round, oval-to-spindle shape with slender wavy nuclei, and exhibiting prominent nuclear palisading (Verocay bodies) focally (Figure 2c), without necrosis and infiltrative growth pattern. The tumor sections showed strong immuno-histochemical positivity to S-100 (Figure 2d), and non-reactivity to cytokeratin, smooth muscle actin (SMA), calponin, P-63, desmin, neurofilament and CD-34, further affirming the diagnosis of schwannoma. The post-operative recovery of patient was uneventful. No recurrence of the tumor was seen during the follow-up period of past 8 months.

Discussion

Schwannomas are slow growing solitary, firm, well-circumscribed, encapsulated round or ovoid

tumors, located in the head, neck, and flexor surfaces of the extremities and usually seen in adults with age ranging from 2nd to 5th decade.^[5] Occurrence of schwannoma in intraparotid location in a child is rare and reported to arise from the intraparotid branches of the facial nerve.^[6]

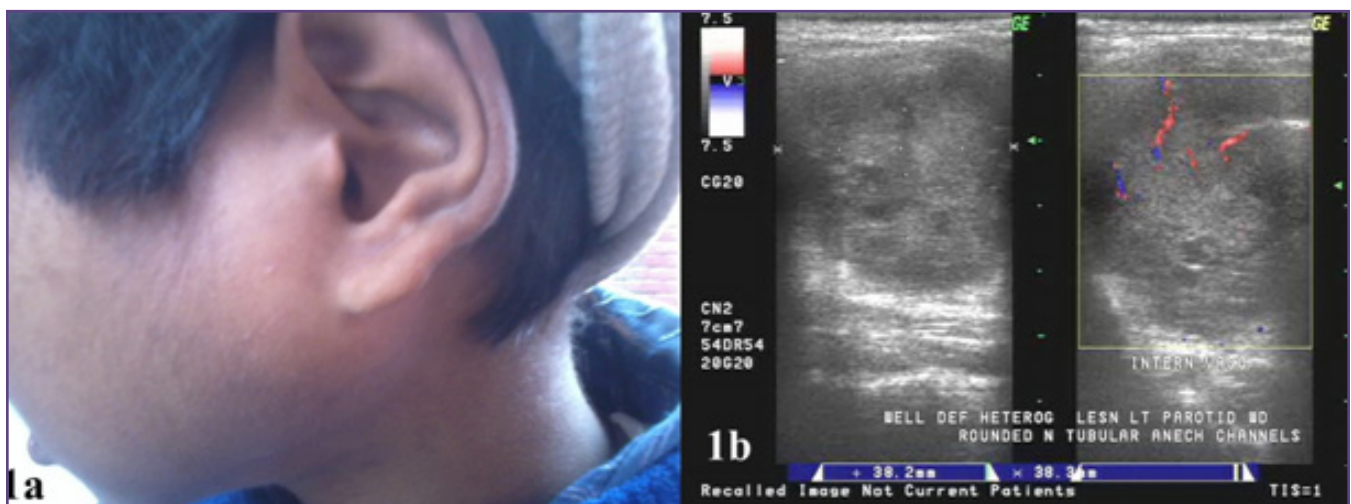


Fig. 1: 1a) showing mass (3 x 3 cm) in left parotid region in a child, 1b) color doppler image of the mass showing increased vascularity with vascular channels showing venous flow pattern.

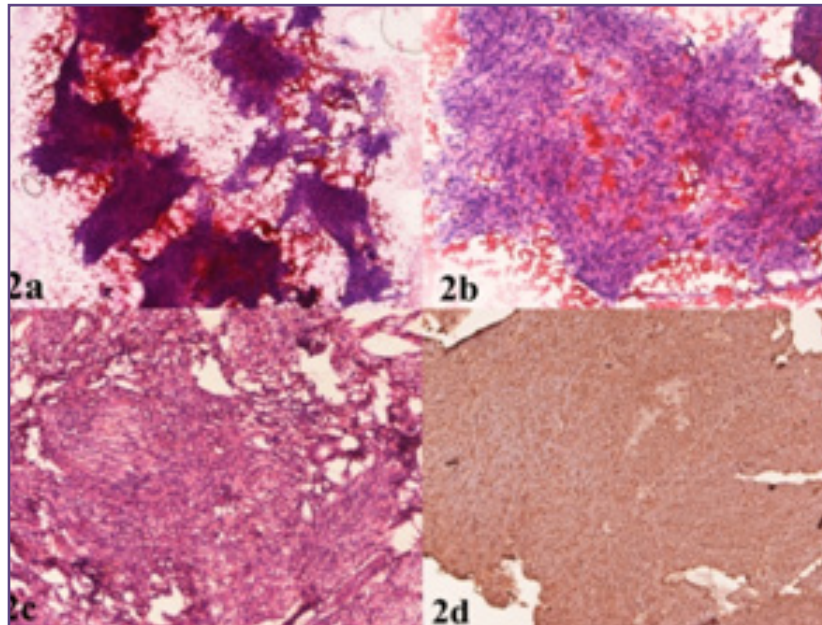


Fig. 2:2a) and 2b) FNA of parotid mass showing high cellularity smears comprising of uniform spindled cells with tapered nuclei, exhibiting subtle nuclear palisading within a fibrillary stromal background (a x H&E x 50, b x H&E x 125), 2c) histological section showing cellular areas comprising of palisaded spindled cells with tapered nuclear end (H&E x 125), 2d) showing strong S-100 positivity of tumor cells (x 50).

Several pitfalls may be encountered in FNA smears for the diagnosis of neural lesions due to varied cytomorphological appearance of different variants, associated with usually a low yield of cells or paucicellularity.^[3] The differential diagnosis in the present case included other spindle-cell lesions of parotid gland including myoepithelial tumors like myoepithelioma, cellular pleomorphic adenoma, benign lesions like nodular fasciitis, fibromatosis, solitary fibrous tumor, neurofibroma, leiomyoma and hemangioma.

The most common diagnostic pitfalls in the evaluation of spindle cell aspirates of the salivary gland are myoepithelial tumors. Myoepitheliomas are also encapsulated tumors and have been occasionally reported in children.^[7] They show varied cell population like plasmacytoid, epithelioid, stellate or clear cells, but it is the spindled-cell form of myoepithelioma that pose a diagnostic challenge. However, the myoepithelial cells in the spindle cell type myoepithelioma can be distinguished morphologically as they are elongated with uniform ovoid to fusiform nuclei with rounded ends in contrast to schwannoma which have wavy nuclei with pointed ends. The fibrillary stroma and subtle nuclear palisading, (Verocay body) can be characteristically identified in FNA smears of schwannoma and is scant or absent in myoepitheliomas. Moreover, cells of myoepithelioma show cytokeratin, SMA and calponin immuno-expression in contrast to schwannoma.^[8] Cellular

or myoepithelial predominant pleomorphic adenoma may resemble a schwannoma clinically as it also presents as gradually enlarging painless mass. However, cytologically, the cells show similar features as that of myoepithelioma i.e. have spindle nuclei with rounded ends. While cellular pleomorphic adenomas can very rarely exhibit nuclear palisading causing confusion, but the presence of focal nuclear palisading associated with fibrillar areas, favors a diagnosis of schwannoma.

Neurofibroma may closely resemble schwannoma on FNA. It is unencapsulated and can be distinguished cytologically as it shows cells with heterogenous pattern of oval and wavy nuclei, lacking palisading. Immunohistochemically, it shows the presence of scattered neurofilament positive axons.

Nodular fasciitis is another pitfall in the diagnosis of spindle-cell lesions of salivary gland.^[9] It is a reactive myofibroblastic proliferative lesion, characterized by loosely cohesive groups of spindle-shaped and stellate myofibroblasts admixed with collagen. Cells have plump oval to elongate nuclei and wispy, tapering bipolar cytoplasmic processes in mucoid background. Positive SMA immuno-expression and non-reactivity to S-100, distinguishes nodular fasciitis from schwannoma.^[10]

Fibromatosis can occur in head and neck region in young individuals. FNA shows uniform polygonal to elongate

plump fibroblasts admixed within myxoid or collagenous tissue.^[11] Immunohistochemically, the fibroblasts and myofibroblasts comprising the lesion are positive for SMA and sometimes desmin.

Solitary fibrous tumor is another rare neoplasm that occurs in the head and neck, and occasionally involving the parotid gland. Aspirates from SFT show hypercellular cohesive groups of haphazardly arranged monotonous tapered spindle cells. Immunohistochemically, it is distinguishable from schwannoma by its non-reactivity to S-100 and reactivity to CD-34 immuno-marker.^[12] Similarly aspirates from a leiomyoma show loose fascicular groups of spindle cells with moderate amounts of eosinophilic cytoplasm, and elongated, blunt-ended “cigar-shaped” nuclei that lack atypia and mitotic activity. Immunohistochemically, leiomyoma show reactivity to SMA and desmin.^[13]

Another pitfall in the diagnosis of schwannoma is granulomatous inflammation. Epithelioid histiocytes may sometimes resemble cells of spindle-cell tumor. However, the background shows suppuration or necrosis in infective conditions.

Also, rarely schwannomas may show increased vascularity on ultrasonography, as was seen in the present case and hence can mimic a vascular neoplasm. However, distinct cytomorphological features distinguish schwannoma from hemangioma or other vascular neoplasms.

The malignant tumors like myoepithelial carcinoma, spindle cell-carcinoma and spindled malignant melanoma demonstrates substantial nuclear atypia, prominent nucleoli in cells, significant mitotic figures, and tumor necrosis, and thus can be excluded with ease on cytologic grounds.

Conclusion

Intraparotid schwannoma in a child is a rare entity. The cytological diagnosis of schwannoma pose diagnostic challenge as several pitfalls may be encountered in FNA smears due to its varied cytomorphological appearance simulating other spindle-cell lesions of salivary gland. However, meticulous close examination of FNA smears can exclude other closely resembling spindle-cell lesions of salivary gland, leading to early diagnosis and appropriate treatment.

Conflicts of interest

Nil - No conflict of interest with any.

References

1. Oncel S, Onal K, Ermete M, Uluc E. Schwannoma (neurilemmoma) of the facial nerve presenting as a parotid mass. *J LaryngolOtol* 2002;116:642-3.
2. Jain R, Gupta S, Borkataky S, Agarwal R, Singh S, Gupta K et al. Rare Diagnosis on aspiration cytology of parotid gland schwannoma. *ActaCytol* 2010;54:112-4.
3. Henke CA, Salomao DR, Hughes JH. Cellular schwannoma mimics a sarcoma: an example of a potential pitfall in aspiration cytodiagnosis. *DiagnCytopathol* 1999;20:312-6.
4. Chhieng DC, Cohen JM, Cangiarella JF. Fine-needle aspiration of spindle cell and mesenchymal lesions of the salivary glands. *DiagnCytopathol* 2000;23:253-9.
5. Hui-Chi KU, Chi-Wei Yeh. Cervical Schwannoma. A case report and eight years review. *Journal of Laryngology and Otology* 2000;114(6):414-7.
6. Falcioni M, Russo A, Taibah A, Sanna M. Facial nerve tumors. *OtolNeurotol* 2003;24:942-7.
7. Yaman H, Gerek M, Tosun F, Deveci S, Kiliç E, Arslan HH. Myoepithelioma of the parotid gland in a child: a case report. *J PediatrSurg*2010;45:E5-7.
8. Politi M, Toro C, Zerman N, Mariuzzi L, Robiony M. Myoepithelioma of the parotid gland: Case report and review of literature. *Oral Oncology Extra* 2005;41:104-8.
9. Saad RS, Takei H, Lipscomb J, Ruiz B. Nodular fasciitis of parotid region: a pitfall in the diagnosis of pleomorphic adenomas on fine-needle aspiration cytology. *DiagnCytopathol*2005;33:191-4.
10. Peng WX, Kudo M, Yamamoto T, Inai S, Fujii T, Teduka K et al. Nodular fasciitis in the parotid gland: a case report and review of the literature. *DiagnCytopathol*2013;41:829-33.
11. Iyer VK. Cytology of soft tissue tumors: Benign soft tissue tumors including reactive, nonneoplastic lesions. *J Cytol* 2008;25:81-6
12. Bauer JL, Miklos AZ, Thompson LD. Parotid gland solitary fibrous tumor: a case report and clinicopathologic review of 22 cases from the literature. *Head Neck Pathol*2012;6:21-31
13. Tao LC, Davidson DD. Aspiration biopsy cytology of smooth muscle tumors. A cytologic approach to the differentiation between leiomyosarcoma and leiomyoma. *ActaCytol* 1993;37:300-8.