

An Extremely Rare Distant non Communicating Uterine Horn Mimicking Parasitic Leiomyoma: A Diagnostic Dilemma

Abhijit Das¹, Nidhi Verma^{1*}, Sompal Singh¹, Namrata Nargotra¹ and Rakesh Kumar Deepak²

¹Department of Pathology, North Delhi Municipal Corporation Medical College & Hindu Rao Hospital, Delhi, India

²Department of Pathology, All India Institute of Medical Sciences, New Delhi, India

Keywords: Unicornuate Uterus, Mullerian Anomaly, Pedunculated Leiomyoma, Parasitic Leiomyoma.

ABSTRACT

Unicornuate uterus is a rare congenital anomaly which occurs due to partial development of mullerian duct system. Patient with unicornuate uterus usually present with dysmenorrhoea, hematometra and endometriosis during their reproductive period. In the absence of these symptoms, proper identification and diagnosis of mullerian anomaly becomes difficult. Sometimes during laparoscopy it can mimic parasitic leiomyoma, another rare benign condition, originated from a subserosal pedunculated leiomyoma. Even on imaging study it becomes difficult to differentiate a rudimentary uterine horn from a parasitic leiomyoma. We present here a case of a patient with a rare distant non communicating uterine horn, mimicking parasitic leiomyoma, which needed proper clinical history, radiological evaluation and histopathological examination to arrive at a correct diagnosis.

***Corresponding author:**

Dr Nidhi Verma, Department of Pathology, North Delhi Municipal Corporation Medical College & Hindu Rao Hospital, Delhi, India

Phone: +91 8527271104

E-mail: drnidhikamal@gmail.com



Introduction

Utero-vaginal anomalies are uncommon findings, among which unicornuate uterus is an extremely rare congenital anomaly, comprising 2-10% of all types of utero-vaginal anomalies.^[1] Partial development of mullerian duct system causes various degrees of uterine horn, either connected or separated from the opposite horn. Rudimentary cavity non communicating horn represents the A1b variants by class II of unicornuate uterus and it comprises of 7-40% of unicornuate uterus with rudimentary horn.^[2] Subserosal leiomyomas are present beneath the endometrial surface. They may be sessile or pedunculated or exophytic. When these leiomyomas disseminate from the uterus and develop an auxiliary blood supply and lose their original attachment from the uterus, they are called parasitic leiomyoma. Rarely may they also be iatrogenic,^[3] and they become torsive causing an acute abdomen.^[4] Sometimes these wandering leiomyomas may be confused with distant non-communicating rudimentary horn of uterus. We present here a case of distant non-communicating rudimentary horn of uterus which mimicked parasitic leiomyoma.

Case Report

A 22 year female presented with chronic pelvic pain and dysmenorrhoea. Per abdomen examination showed diffuse tenderness in the right lower abdomen however no definite mass was palpable. Her routine investigations were within normal limits. MRI was performed and on the basis of findings a possibility of rudimentary non communicating uterine horn was kept, however a differential diagnosis of parasitic leiomyoma was also kept because the mass was quite away from the uterus (Fig 1). Patient was planned

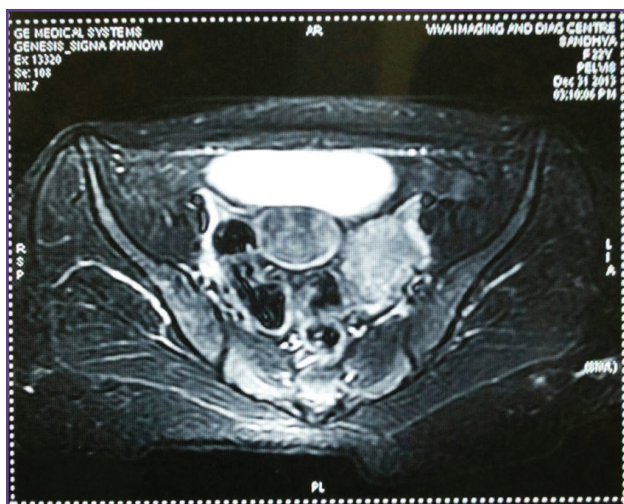


Fig. 1: MRI of pelvis shows a well circumscribed mass completely separated from the uterus.

for surgery and laparoscopy showed a well circumscribed globular mass completely separated and 3cm away from uterus (Fig 2). The mass was completely excised and sent for histopathology. Grossly the mass was 4.5x3x2.5 cm in size, well circumscribed, firm and globular with smooth external surface (Fig 3a). Cut sections showed myometrium like tissue with a central small cavity (? rudimentary endometrial cavity) measuring 0.8x0.5x0.5 cm in size, filled with blood clots. Myometrium also showed multiple brownish black areas (?adenomyotic foci) ranging in size from 0.1 to 0.3 cm (Fig 3b). Microscopy showed endometrial cavity lined by functional endometrium and normal myometrium with thick walled blood vessels (Fig 4 and 5). Sections taken from the brownish black foci showed areas of adenomyosis (Fig 6). Presence of endometrial cavity lined by functional endometrium and absence of well circumscribed areas with long interlacing fascicles and presence of thick walled blood vessels ruled out the possibility of a parasitic leiomyoma. Thus a final diagnosis of distant non communicating rudimentary horn of uterus with extensive adenomyosis was given. The post operative recovery was uneventful and the patient was relieved of her complains. At 4 months follow up patient was absolutely well.

Discussion

Abnormalities of embryogenesis of mullerian duct system resulting in various female congenital anomalies are relatively common, however exact incidence is difficult to ascertain, as they are not always clinically symptomatic.^[5] Their prevalence could be higher among women with infertility or obstetric complications.^[6]

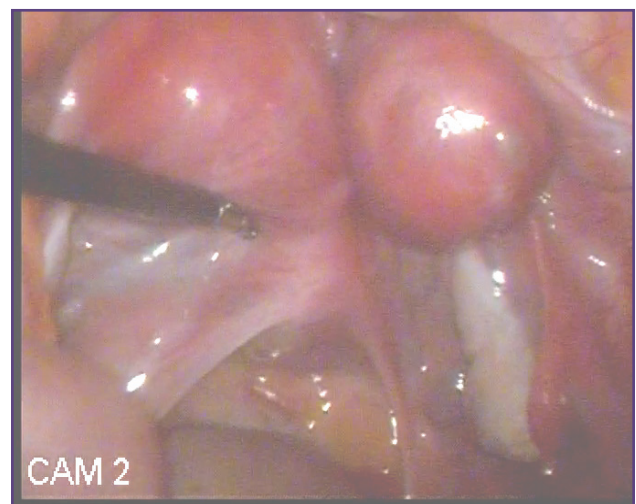


Fig. 2: Laparoscopy shows same distant well circumscribed globular mass.

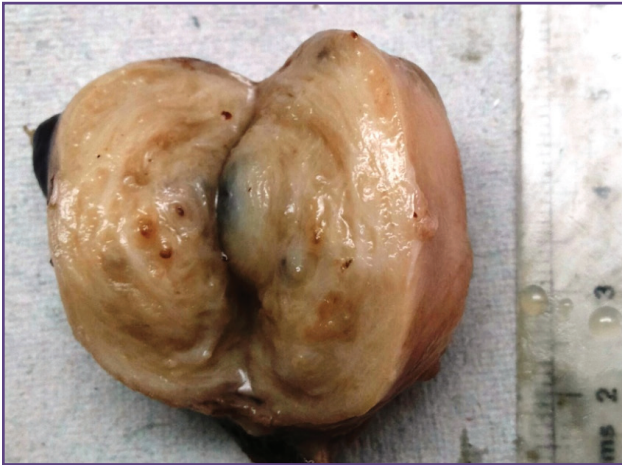

Fig. 3a: Grossly circumscribed globular tissue with smooth external surface.

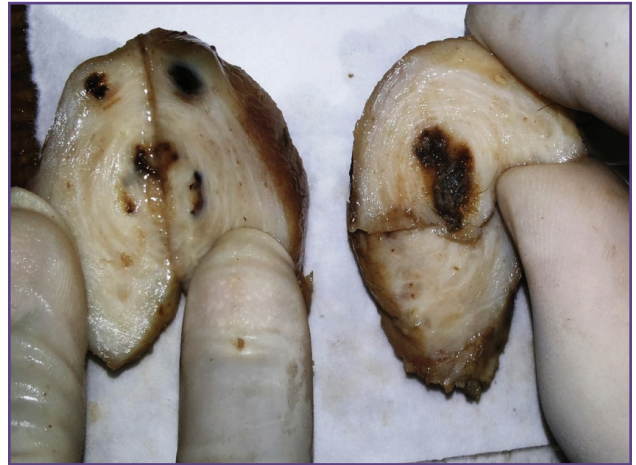

Fig. 3b: Cut section of the specimen shows an atrophic cavity filled with blood clot. Myometrium shows numerous adenomyotic foci of variable sizes.

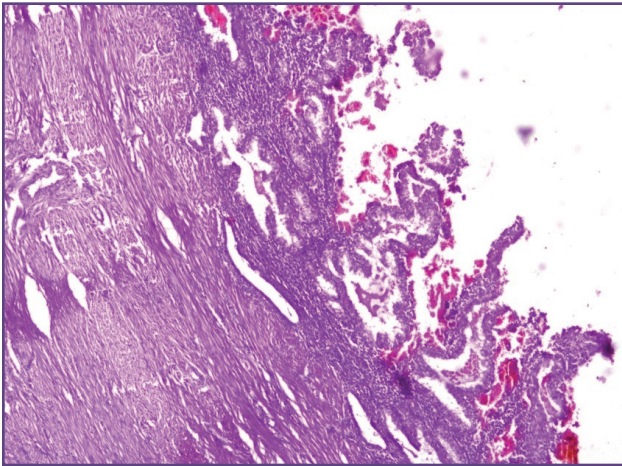


Fig. 4: Microscopy from the cavity area shows myometrium lined by functional endometrium (H&E,100X).

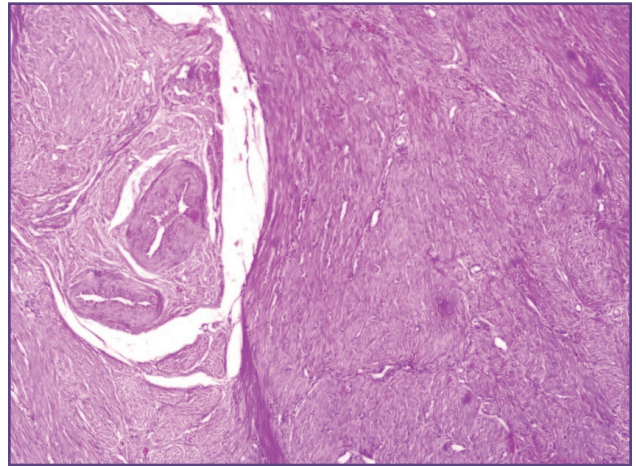


Fig. 5: Microsection from the myometrium shows many thick walled vessels (H&E,100X).

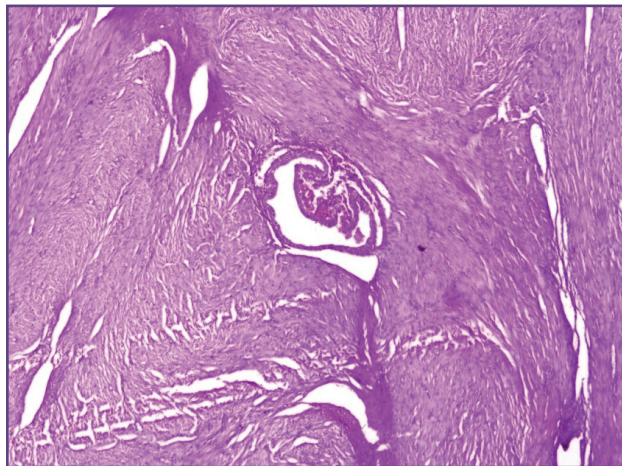


Fig. 6: Microsection from the myometrium shows many adenomyotic foci (H&E,100X).

Unicornuate uterus is a type II mullerian anomaly according to the American Fertility Society classification system^[5] that occurs due to complete or partial failure of development of one mullerian duct and incomplete fusion with the contralateral side. In complete failure, failed mullerian duct leads to formation of an isolated hemiuterus without a contralateral structure,^[7] whereas in partial failure it causes various degrees of rudimentary uterine horn. Again rudimentary horn is sub classified into communicating or non communicating with or without uterine cavity.^[5-7] This rare condition is often related to poor reproductive function with greater incidence of primary infertility, preterm labor and pregnancy loss.^[8] Various gynaecological conditions which are associated with unicornuate uterus include dysmenorrhoea (in 70% cases), hematometra (in 50% cases) and adenomyosis (in 20-40% cases).^[9] Presence of dysmenorrhoea and adenomyosis are not very helpful in the diagnosis of rudimentary horn as these are frequently encountered in women of reproductive ages. However presence of hematometra in association with dysmenorrhoea and adenomyosis is an important clue to the diagnosis of mullerian anomaly.

Proper preoperative identification and diagnosis of mullerian anomaly is important to decide the right surgical approach, because surgical procedure is extremely influenced by the specific subtype and at the same time by the anatomical architecture of the uterus.^[10] In our case MRI of pelvis showed a completely separated hypoechoic mass that was quite consistent with leiomyoma, focally a hyperintense area is noted on T2 weight imaging suggesting endometrial tissue. For these reasons it became difficult to arrive at a correct diagnosis and possibility of both uterine horn and parasitic leiomyoma were kept on imaging. Since parasitic leiomyomas are separated from the uterus they can be easily mistaken for an adnexal tumor. An ultrasonographic diagnosis of pedunculated leiomyoma can be established if a pedicle is demonstrated between leiomyoma and uterus. A parasitic leiomyoma where pedicle gets detached from the uterus may have the clinical and radiological presentation just like any other adnexal tumors. In our case the correct diagnosis was given only after histopathological examination. Identification of normal myometrium with presence of thick walled vessels and absence of long fascicles of smooth muscles with cigar shaped nuclei exclude the possibility of leiomyoma. Presence of well formed endometrial cavity with functional endometrial lining along with numerous adenomyotic foci established the diagnosis of rudimentary horn of uterus with adenomyotic foci.

Conclusion

In conclusion besides rarity, there are several interesting aspects of this case, firstly it mimicked parasitic leiomyoma on imaging and during laparoscopy it appeared quite away from the uterus unlike usual rudimentary horn. Another rare thing was the presence of adenomyosis in this distant non communicating rudimentary horn of uterus. Histopathology was helpful in reaching the correct diagnosis. One should keep a differential diagnosis of rudimentary horn of uterus in patients of reproductive age group presenting with dysmenorrhoea along with hematometra. Proper clinical history, investigations and histopathology may be helpful to arrive at a correct diagnosis.

Acknowledgements

We would like to thank our consultants from the department of Pathology, NDMCMC & HRH for their guidance, otherwise it would have been difficult to work on this topic.

Funding

None

Competing Interests

None Declared

Reference

1. Fenton AN, Singh BP. Pregnancy associated with congenital abnormalities of the female reproductive tract. *Am J Obstet Gynecol.* 1952 Apr;63(4):744-55.
2. Buttram VC Jr, Gibbons WE. Müllerian anomalies: a proposed classification. (An analysis of 144 cases). *Fertil Steril.* 1979 Jul;32(1):40-6.
3. G Ravichandra , B Harishchandra, Upadhyaya K Krishnaraj, Acharya Devdas, Madhurkar Rohit. Parasitic uterine leiomyoma; years after hysterectomy: a case report. *International journal of medical and applied sciences.* 2013; 2(3): 222-225.
4. Yeh HC, Kaplan M, Deligdisch L. Parasitic and pedunculated leiomyomas: ultrasonographic features. *J Ultrasound Med.* 1999;18(11):789-94.
5. R. Iverson, A. DeCherney, and M. Laufer, "Clinical manifestations and diagnosis of congenital anomalies of the uterus," Uptodate, 2012.
6. Chopra S, Keepanasseril A, Rohilla M, Bagga R, Kalra J, Jain V. Obstetric morbidity and the diagnostic dilemma in pregnancy in rudimentary horn: retrospective analysis. *Arch Gynecol Obstet.* 2009; 280 (6): 907-10.

7. Reichman D, Laufer MR, Robinson BK. Pregnancy outcomes in unicornuate uteri: a review. *Fertil Steril.* 2009 May; 91(5): 1886-94.
8. Morelli M, Venturella R, Mocciano R, Lico D, Zullo F. An unusual extremely distant noncommunicating uterine horn with myoma and adenomyosis treated with laparoscopic hemihysterectomy. *Case Rep Obstet Gynecol.* 2013; 2013:160291.
9. Heinonen PK. Unicornuate uterus and rudimentary horn. *Fertil Steril.* 1997; 68(2): 224-30.
10. Fedele L, Bianchi S, Zanconato G, Berlanda N, Bergamini V. Laparoscopic removal of the cavitated noncommunicating rudimentary uterine horn: surgical aspects in 10 cases. *Fertil Steril.* 2005 Feb; 83(2): 432-6.