

An Unusual Case of Bladder Tumour with Diagnostic Dilemma: A Rare Case Report

Jayaprakash Shetty K^{1*}, Kishan Prasad HL¹, Rajeev TP², Nigi Ross Philip¹,
Anitha Chakravarthy¹ and Prajwal Ravinder²,

¹Department of Pathology, K S Hegde Medical Academy of Nitte University, Mangalore, Karnataka, India.

²Department of Urology, K S Hegde Medical Academy of Nitte University, Mangalore, Karnataka, India.

Keywords: *Bladder, Leiomyosarcoma, Nonurothelial Neoplasm, ALK 1*

ABSTRACT

Urinary bladder tumours rank ninth in the worldwide cancer incidence. Urothelial carcinomas are the fourth most common malignancy in men. It is very rare in younger age group, but it can occur at any age group. We report a case of a 28 yr old male who presented with dysuria and suprapubic pain with Contrast enhanced computerised tomography revealed polypoidal lesion arising from the dome of the urinary bladder. In light microscopy showed, pleomorphic spindle tumours cells arranged in fascicles with increased atypical mitosis along with scattered chronic inflammatory cells. The possibility of leiomyosarcoma or inflammatory myofibroblastic tumor was considered in differential diagnosis. The immunohistochemistry was positive for Vimentin, Desmin, Smooth muscle actin, Ki 67 and myo D1 and negative for Cytokeratin, ALK 1, H-Caldesmon, S 100 and CD 34. Hence a diagnosis of leiomyosarcoma was made. This case highlights the unusual tumour with its diagnostic dilemma of the case.

***Corresponding author:**

Dr. Jayaprakash Shetty K, Professor and Head, Department of Pathology, K S Hegde Medical Academy of Nitte University, Deralakatte, Mangalore, Karnataka, India.

Phone: +91 9845085182

E-mail: drjpsheetty9@yahoo.com



Introduction

Nonurothelial neoplasms of the bladder account for <5% of all bladder tumors with leiomyosarcoma comprising 0.1% of all bladder cancers.^[1,2] Due to its low incidence rate very little is known about the natural history and prognosis of the tumour and there is a lack of the consensus of the standard treatment. While on the other hand Inflammatory myofibroblastic tumor (IMFT) of the urinary bladder is also a very uncommon spindle cell tumor that is said to have undetermined malignant potential. Differentiating between these two lesions is important as the treatment modality varies. We encountered a similar case with histology and immunohistochemistry closely mimicking causing diagnostic dilemma.

Case Report

A 28 year old male, presented with dysuria and suprapubic pain since 3 months. Past, family and personal history was unremarkable. The per rectal examination revealed Grade I prostatomegaly. The ultrasound abdomen has showed a hypoechoic polypoidal lesion measuring 6.7x6.9x7.2cm in the urinary bladder. A Contrast enhanced computerised tomography [CECT] was also done which showed a polypoidal mass arising from the dome of the bladder (Fig1A&B). Cystoscopy revealed a large pedunculated mass arising from the left superolateral wall of the urinary bladder. Biopsy of the same showed inflammatory lesion favouring chronic cystitis. This was followed by a partial cystectomy that included the excision of the tumour along with the pedicle and attached bladder wall. On Gross examination, the mass was measuring 7x5cm and the outer surface was smooth with whorled appearance on cut surface as shown in the Fig 1C&D. On microscopy, in H&E stain, the bladder growth with the pedicle and bladder wall showed infiltrative tumour composed of spindly cells in fascicles[Fig 2A] and sheets having mild to moderate eosinophilic cytoplasm with increased N:C and pleomorphic hyper chromatic nucleus.[Fig 2B] Many binucleated and multinucleated tumour giant cells were seen. Atypical mitosis-1-2/hpf. Also noted admixed chronic inflammatory cells. The tumour cells were invading the bladder wall and at places, reached the perivesicle fat. Tumour cell near the bladder wall has epitheloid cell morphology having polygonal appearance with hyperchromatic nucleus.[Fig 2C, D] Focal tumour necrosis was also seen. The perivesicular tissue shows thick walled blood vessels with pleomorphic tumour cells surrounding these. Masson Trichrome stain shows tumour cells with muscle differentiation. Right and lateral pelvic wall were free tumor. A diagnosis of low grade pleomorphic sarcoma probably leiomyosarcoma versus inflammatory

myofibroblastic tumour was made. For further confirmation of the diagnosis, immunohistochemistry was suggested. The immunohistochemistry was positive for vimentin[Fig 3A], desmin[FIG 3B], smooth muscle actin[Fig 3C], Ki 67 and myo D1[Fig 3D] while it was not negative for Cytokeratin, ALK 1[Fig 3E], H-Caldeson, S 100 and CD 34 confirming the above diagnosis. Patient was closely observed and on regular follow up since 6months without any recurrence or metastasis.

Discussion

Urinary bladder leiomyosarcoma is relatively rare, with few large series reported in the literature. According to Rosseret al., the most common clinical presentation is gross hematuria(81%) followed by frequent micturition at day time referred to as pollakiuria (28%) and dysuria(19%).^[2-5] Our case had symptoms of dysuria and suprapubic pain. The Inflammatory myofibroblastic tumor (IMFT) is a rare spindle cell neoplasm of the urinary bladder which is characterized by atypical spindle cell proliferation accompanied by inflammatory cell infiltrate comprised primarily of lymphocytes and plasma cells. The first case was reported by Roth in 1980.^[4-6] It is also known as pseudo sarcoma, atypical fibromyxoid tumor, atypical myofibroblastic and plasma cell granuloma.^[5] The morphologic and immunophenotypic features of IMFT overlaps with that of malignant spindle cell tumors of the urinary bladder and hence a diagnostic distinction from these tumors can create a dilemma. The other differentials include pseudosarcomatous appearing transitional cell carcinoma, leiomyosarcoma, rhabdomyosarcoma, angiosarcoma and osteosarcomas.^[12] Immunohistochemical staining useful in such cases are for Anaplastic lymphoma kinase (ALK), vimentin, cytokeratin. Leiomyosarcomas show a fascicular growth pattern and myofibrillar elements. Pseudosarcomatous transitional cell carcinoma is a neoplasm in which an in situ or superficially invasive transitional cell carcinoma is associated with a bizarre sarcoma-like, reactive stromal response which can be easily misdiagnosed as carcinosarcoma. Although necrosis is described in 30% or more of IMFTs, the presence of necrosis at the tumor–detrusor muscle interface in muscle-invasive cases was one criterion present in sarcoma that distinguished it from inflammatory pseudotumor.^[6] Some leiomyosarcomas of the bladder display myxoid zones and can also express cytokeratin. The histopathological features like lack of a delicate vascular network, interspersed inflammatory cells, and red blood cells are usually observed in IMT while the marked cytologic atypia, nuclear hyperchromasia, and atypical mitoses are present in leiomyosarcomas that help in the differential

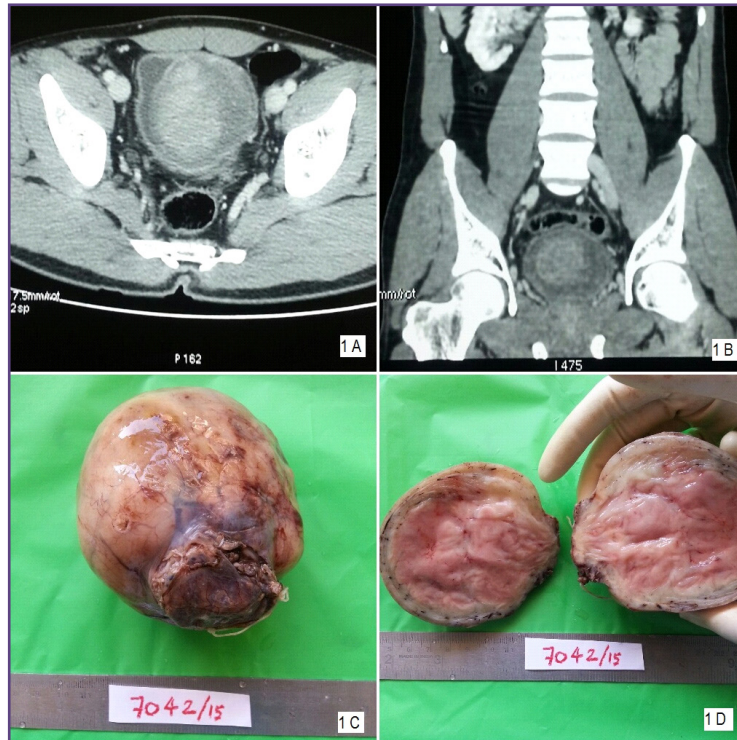


Fig. 1: A&B] CECT showing polypoidal mass lesion arising from the dome of bladder[Coronal and sagittal view] 1C&D- Gross examination of the bladder mass showing grey white tumour with smooth outer surface and the cut surface with whorled appearance.

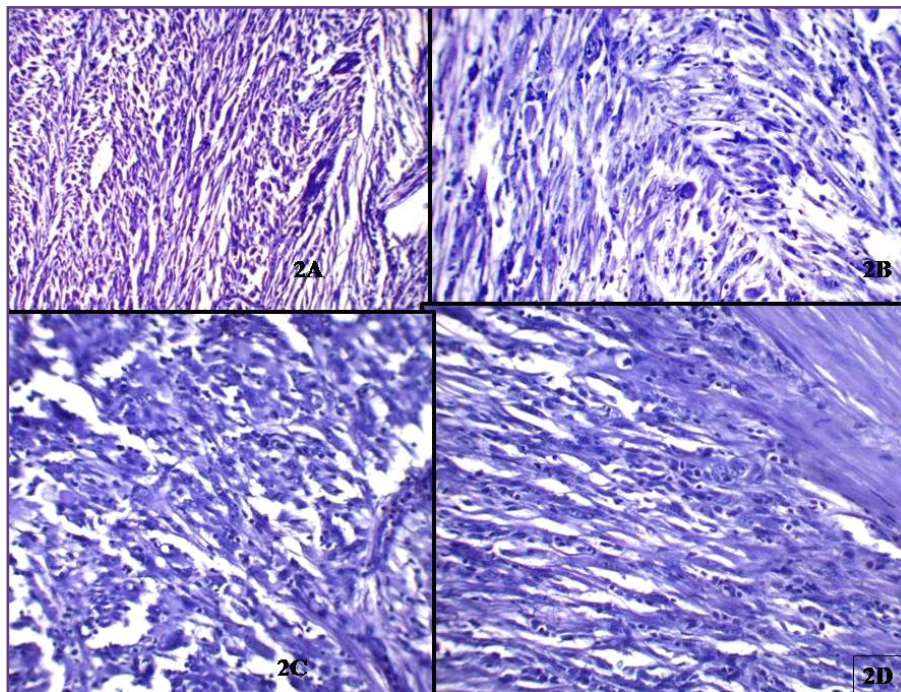


Fig. 2A: Histopathology of the Infiltrative tumour showing spindle cells in fascicles[H&E, X100]; 2B- Histopathology showing tumour cells with mild to moderate eosinophilic cytoplasm and pleomorphic hyper chromatic nucleus. [H&E, X100]; 2C&D- Histopathology showing epithelioid cell morphology having polygonal appearance, hyperchromatic nucleus.[H&E, X400].

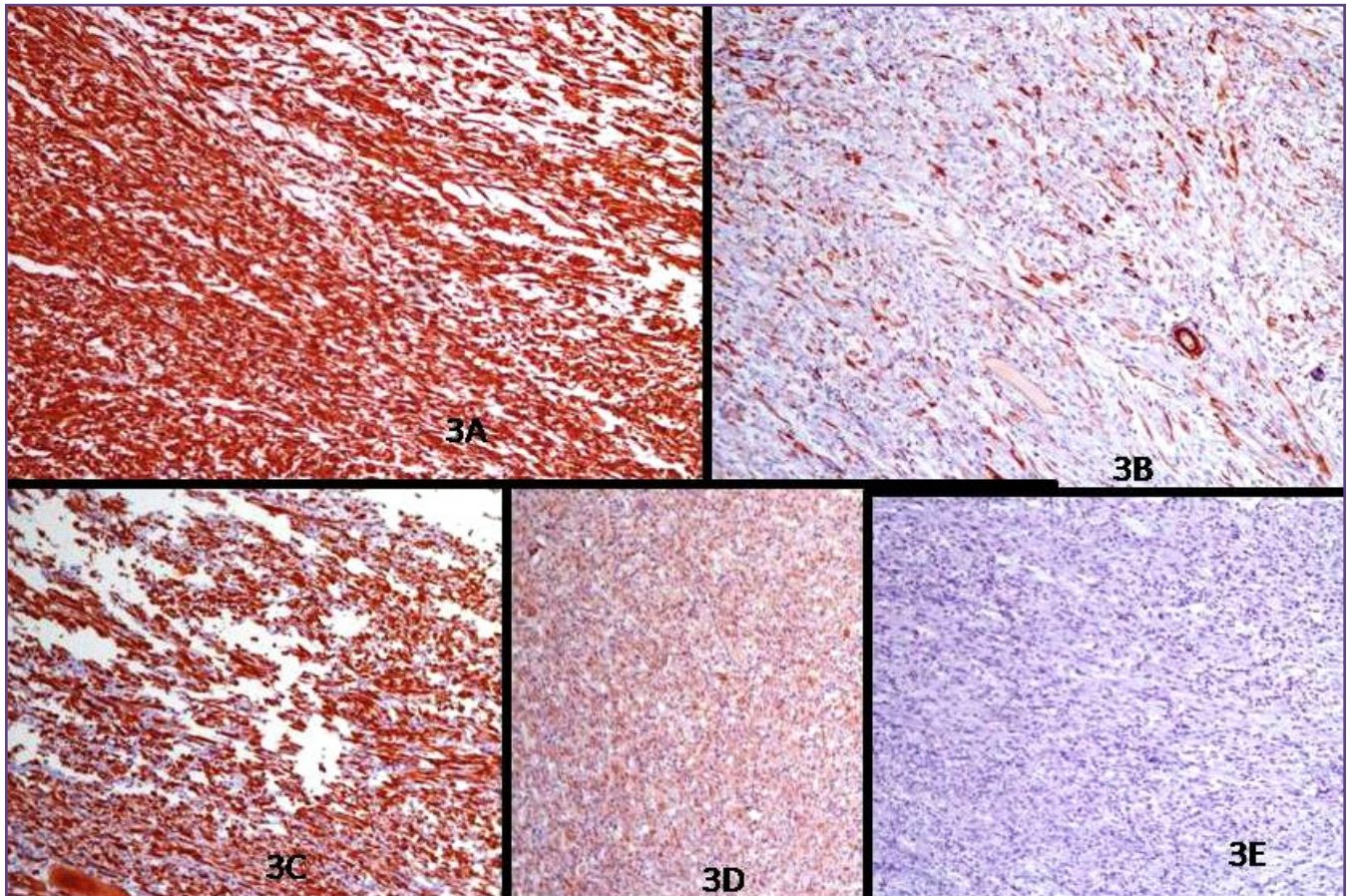


Fig. 3: Immunohistochemistry showing reactive for vimentin[3A], Smooth muscle actin[3B], Desmin[3C], Myo-D 1[3D] and negative for ALK -1[3E].

diagnosis. Leiomyosarcomas and leiomyomas lack ALK protein. Myogenin or MyoD1 is a potent marker that will help in exclusion of rhabdomyosarcoma.^[7]

The ALK-1 positivity confirms the chances of local recurrence and muscle invasion.^[6-8] Originally it was identified as a protein overexpressed in anaplastic large-cell lymphoma, ALK-1 has subsequently been shown to be overexpressed in a substantial proportion of IMFTs of various anatomic locations, including the urinary bladder.^[8-9] In IMFT of the urinary bladder, positivity for ALK-1 by immunohistochemistry ranges from 33% to 89%, whereas ALK-1 protein expression in leiomyosarcoma and sarcomatoid urothelial carcinoma has not been reported, suggesting that ALK-1 immunohistochemical studies may be useful in the differentiation of IMFT from other spindle cell lesions in the urinary bladder. In our case, ALK 1 was negative and other immunomarkers positivity ruling out IMFT and favoured the diagnosis of leiomyosarcoma.

Urinary bladder leiomyosarcomas have always been considered highly aggressive tumors that require aggressive

surgical extirpation, and radical cystectomy with wide margins should be performed whenever possible.^[9-11] In most reported cases of IMFTs of the urinary bladder, surgical resections, including transurethral resection and partial/radical cystectomy were done. However in our case, in view of aggressive histological nature, patient was regularly monitored and is on close follow up without any recurrence and metastasis.

Conclusion

In conclusion, we agree with previous literature that due to limited experience with this rare tumour, there are insufficient data to suggest an optimum management strategy and prognosis, and as we are in an exciting period of discovery about tumours further options might be available in future.^[11]

References

1. Yamada T, Nagai S, Kanimoto Y. Rapid progression of a urinary bladder leiomyosarcoma: Report of a case. *Case Reports in Urology* 2011;532081: 3.

2. Bjergaard JP, Jonsson V, Pedersen M, Jensen KH. "Leiomyosarcoma of the urinary bladder after cyclophosphamide". *J Clin Oncol* 1995;13(2):532-3.
3. Rosser CJ, Slaton JW, Izawa JI, Levy LB, Dinney CPN. Clinical presentation and outcome of high-grade urinary bladder leiomyosarcoma in adults. *Urology* 2003;61(6):1151-5.
4. Roth JA. Reactive pseudosarcomatous response in urinary bladder. *Urology* 1980;16:635-7.
5. Zones EC, Clement PB, Young RH. Inflammatory pseudotumour of the urinary bladders. A clinicopathologic, immunohistochemical, ultrastructural and flowcytometric study of 13 cases. *Am J SurgPathol* 1993;17:264-74.
6. Coffin CM, Fletcher JA. Inflammatory myofibroblastic tumour. In: Fletcher CD, Unni KK, Mertens F, editors. *World Health Organization Classification of Tumours: Tumours of Soft Tissue and Bone*. Lyons, France: IARC Press; 2002. p. 91-3.
7. Montgomery EA, Shuster DD, Burkart AL, Esteban JM, Sgrignoli A, Elwood L, et al. Inflammatory myofibroblastic tumors of the urinary tract: A clinicopathologic study of 46 cases, including a malignant example of inflammatory fibrosarcoma and a subset associated with high-grade urothelial carcinoma. *Am J Surg Pathol* 2006;30:1502-12.
8. Cook JR, Dehner LP, Collins MH, Ma Z, Morris SW, Coffin CM, et al. Anaplastic lymphoma kinase (ALK) expression in the inflammatory myofibroblastic tumor: A comparative immunohistochemical study. *Am J Surg Pathol* 2001;25:1364-71.
9. Spiess PE, Kassouf W, Steinberg JR et al., Review of the M.D. Anderson experience in the treatment of bladder sarcoma. *Urologic Oncol* 2007;25(1); 38-45.
10. Ricciardi E, Maniglio P, Schimberni M, Moscarini M. A case of high-grade leiomyosarcoma of the bladder with delayed onset and very poor prognosis. *World J Surgical Oncol* 2010;8.
11. Hamadalla NY, Rifat UN, Safi KC, Mohammed M, Farsakh HA. Leiomyosarcoma of the urinary bladder: A review and a report of two further cases. *Arab J Urol* 2013;11:159-64.
12. Yagnik V, Chadha A, Chaudhary S, Patel K. Inflammatory myofibroblastic tumour of the urinary bladder. *Uro Ann* 2010;2(2):78-9.