

# Brunner's Gland Hamartoma - A Rare Cause of Upper GI Bleed: Report of Two Cases Emphasising Pathogenesis

Rakesh Kumar Gupta<sup>1</sup>, Ravindra Kumar Saran<sup>1\*</sup>, Shivakumar Varakanahalli<sup>2</sup> and Amarender Singh Puri<sup>2</sup>

<sup>1</sup>Department of Pathology, G B Pant Institute of Postgraduate Medical Education and Research,  
Jawaharlal Nehru Marg, New Delhi, India

<sup>1</sup>Department of Gastroenterology, G B Pant Institute of Postgraduate Medical Education and Research,  
Jawaharlal Nehru Marg, New Delhi, India

*Keywords: Brunner's gland, Hamartoma, Endoscopy, Gastrointestinal*

### ABSTRACT

Brunner's gland hamartoma (BGH) is a rare benign tumor of duodenum and mostly presents as an incidental finding. However, large lesions may cause obstructive symptoms and bleeding. Herein, we report two cases of BGH, one with upper gastro-intestinal bleed and other with recurrent vomiting which were managed successfully by endoscopic resection.

**\*Corresponding author:**

Dr Ravindra Kumar Saran, MD, DNB, Department of Pathology, Academic Block, G B Pant Institute of Post graduate Medical Education and Research, Jawahar Lal Nehru Marg, New Delhi-110002. INDIA

Phone: +91 9718599074

E-mail: ravindrakrsaran@hotmail.com



## Introduction

Brunner's gland hamartoma (BGH) is also known as Brunneroma and Brunner gland adenoma. It is a rare benign tumor of the duodenum which commonly occurs in fifth to sixth decade of life. It usually presents as an incidental finding. However, large polyps can present with obstructive features or gastrointestinal bleed. Duodenal bulb is the most common site of occurrence.<sup>[1]</sup> We report two cases of successful endoscopic removal of a large BGH arising from the first part of duodenum.

## Case report 1

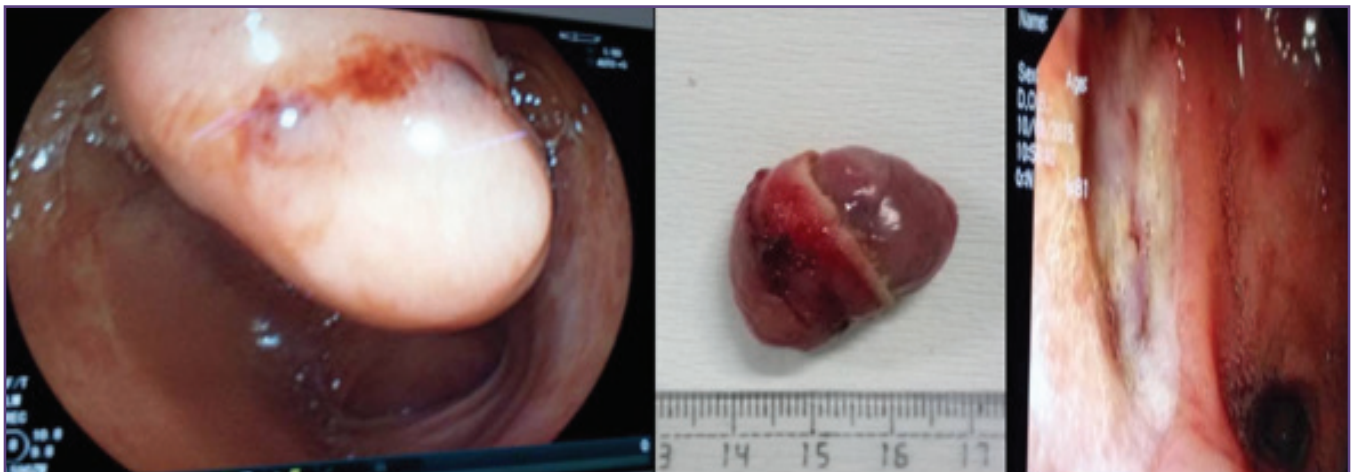A 47-year-old male, referred to our hospital with the history of 2 discrete episodes of black tarry stools 3 weeks ago. Blood loss in each episode was approximately 500 ml followed by giddiness, palpitations and sweating. For these symptoms the patient was transfused three units of packed cells. No history of prolonged NSAID use was documented. Systemic examination was unremarkable except for mild pallor. Upper gastrointestinal endoscopy done revealed a large polypoidal mass measuring 3x3 cm with overlying erosions on the anterior wall of the duodenal bulb (Figure 1a). Contrast enhanced computer tomography showed a polypoidal mass in the first part of the duodenum measuring 26x16 mm (Figure 2). Polypectomy was attempted elsewhere but failed and so the patient was referred to our hospital. Polypectomy was attempted at our hospital using a forward viewing endoscope (Fujinon, Japan). The polyp was snared using polypectomy snare (Wilson-cook, USA). Post-operatively the patient had two episodes of hematemesis with malena which was managed with transfusion of two units of blood and two units of fresh frozen plasma. A relook endoscopy

done the next day showed a clean based ulcer with no signs of active bleed (Figure 1c). The patient was asymptomatic at the next follow-up visit 4 weeks later.

## Case report 2

A 52-year-old female, presented to our hospital with the history of intermittent, non-retention vomiting since 1.5 years. No history of upper gastro-intestinal bleeding, prolonged NSAID use was documented. Upper gastrointestinal endoscopy done revealed a large polypoidal mass measuring 3x2 cm with overlying erosions on the anterior wall of the duodenal bulb. Rest of the duodenum, esophagus and stomach were unremarkable. Polypectomy was done using a forward viewing endoscope and the polyp was snared. Post-operatively patient was stable, discharged next day and later lost to follow-up.

**Pathological Findings:** Both the specimens showed a similar histomorphology. Grossly, both the polyps were large, smooth surfaced with focal ulceration and congestion (Figure 1b). No stalks were identified in both the specimens. On microscopy, a polypoidal structure comprising of innumerable proliferating benign Brunner's gland (BG) separated by thick fibrocollagenous and fibromuscular septae and focal ulceration of the overlying mucosa was seen (Figure 3a). At places the septae showed adipose tissue, smooth muscle bundles and infiltration by aggregates of mature lymphocytes (Figure 3c). Focal gastric foveolar metaplasia was seen (Figure 3b). Helicobacter pylori infection was not detected in Giemsa stain. The BGs were diffusely and uniformly positive for MUC1 (Thermo-scientific), while few draining ducts and focal overlying surface epithelium with gastric foveolar metaplasia were MUC5AC (Neomarkers) positive (Figure 3d).



**Fig. 1: Endoscopic photomicrographs of case 1. a: showing a polyp with focal surface ulceration, b: Gross image of polyp measuring 3 cm, c: post-operative day 3 image showing healing ulcer with clean base.**

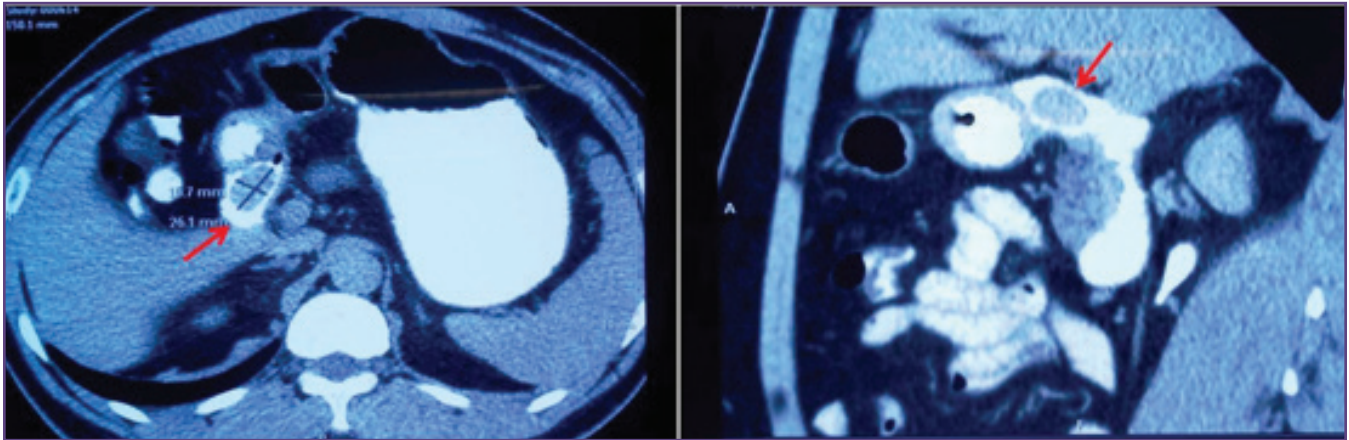


Fig. 2: CECT images showing a polypoidal mass in the first part of the duodenum measuring 26x16 mm (arrow).

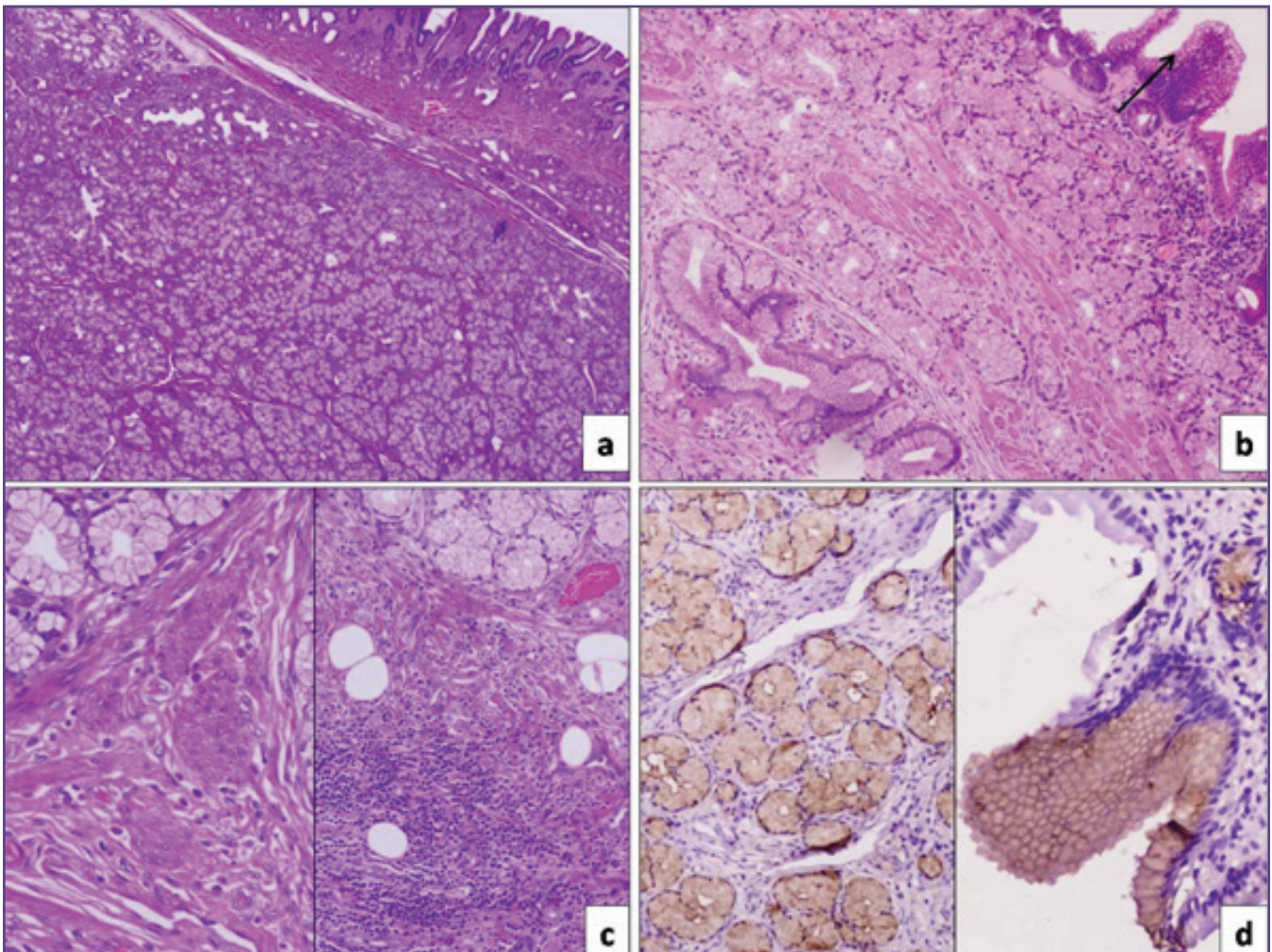


Fig. 3: Histomorphological and immunohistochemistry photographs a: A polypoidal structure comprising of innumerable proliferating Brunner's gland (HEx40), b: Focal gastric foveolar metaplasia (arrow) of the overlying epithelium and submucosal duct (HEx40), c: Thick fibrocollagenous and fibromuscular septae with focal adipose tissue elements and mature lymphocytes (Hex100), d: Diffuse and uniform MUC1 positivity in Brunner's gland and MUC5AC in the gastric foveolar metaplastic epithelium (x200).

## Discussion

Since its first description by Cruveilhier about 200 cases of BGH have been reported in the literature. [2] The mean size of the tumor is 2-3 cm but larger tumors can also occur which have a higher tendency for obstruction and bleeding. BGs are compound tubular submucosal glands exclusively found between the pylorus and the ampulla of Vater. Their major function is secretion of mucus-rich alkaline fluid protecting the intestinal epithelium and maintaining the pH for the functioning of the intestinal enzymes. The exact pathogenesis of the lesion is not known. However, some reports hypothesised that any cause of gastric hyperacidity or accelerated gastric emptying can lead to BG hyperplasia to counteract the damage to intestinal mucosa. [2,3] Though, this hypothesis cannot be completely justified because such a cause will lead to a more generalized phenomenon of BGs hyperplasia rather than isolated polypoidal growth. Also, rarity of this lesion is not explained by numerous cases of gastric hyperacidity or in cases of short gastric emptying time. So, some other factors, still unknown, are likely to interact with the proliferating BGs leading to isolated polypoidal presentation. Absence of response to proton pump inhibitors (PPI) in the form of reduction of hyperplasia or decrease in size of BGH, in clinical setting is against the above hypothesis. By definition, BGH should have accompanying mesenchymal elements and their presence cannot be explained. Stolte et al suggested that diffuse hyperplasia of the duodenal glands is likely to be an adaptive reaction to the exocrine insufficiency of the pancreas or gastric hyperacidity and accelerated emptying of the stomach caused by chronic pancreatitis. [4] The secretion of urogastrone an inhibitor of gastric acid secretion by the BGs supports this hypothesis. A role of *Helicobacter pylori* (*H. pylori*) in the pathogenesis of BGH has been also described. [5]

Gastric foveolar metaplasia is a frequent finding noted in BGHs, which may further progress to the development of dysplastic changes. [6,7] Our case also delineated focal gastric foveolar metaplasia of the overlying surface epithelium and few ducts which were highlighted by MUC5AC positivity. Akaki et al found that gastric foveolar differentiation is possibly related to the proliferative activity of Brunner's glands. [8]

Chong et al subclassified BG lesions based on size and presence of mesenchymal elements. [9] They used the term 'hyperplasia' for lesions <1cm; 'adenoma' for lesions >1cm and term 'hamartoma' if it contains mesenchymal elements too. However, in gastro-intestinal tract 'adenoma' is a self-explanatory term used for a lesion with dysplastic change, and it should not interchangeably be used for BGHs which are

absolutely benign. Hamartoma will be a more appropriate term for all such lesions revealing disorganization of the BGs contributed by admixed mesenchymal elements.

Endoscopic resection is the treatment of choice; however in large polyps open surgery may be required. Recurrence after endoscopic or surgical excision has not been reported. However, one case with malignant transformation has been reported. [10]

## Conclusion

To conclude, we report two symptomatic cases of BGH treated successfully by endoscopic resection.

## References

1. Levine JA, Burgart LJ, Batts KP, Wang KK. Brunner's gland hamartomas: clinical presentation and pathological features of 27 cases. *Am J Gastroenterol.* 1995;90:290-4.
2. Sen R, Gupta V, Sharma N, Chawla N, Kumar S, Malik S. Brunner gland hamartoma masquerading as malignancy; a rare case report. *Middle East J Dig Dis.* 2014;6:237-40.
3. Peison B, Benisch B. Brunner's gland adenoma of the duodenal bulb. *Am J Gastroenterol.* 1982;77:276-8.
4. Stolte M, Schwabe H, Prestele H. Relationship between diseases of the pancreas and hyperplasia of Brunner's glands. *Virchows Arch A Pathol Anat Histol.* 1981;394:75-87.
5. Kovacevic I, Ljubicic N, Cupic H et al. *Helicobacter pylori* infection in patients with Brunner's gland adenoma. *Acta Med Croatica.* 2001;55:157-160.
6. Kim K, Jang SJ, Song HJ, Yu E. Clinicopathologic characteristics and mucin expression in Brunner's gland proliferating lesions. *Dig Dis Sci.* 2013;58:194-201.
7. Sakurai T, Sakashita H, Honjo G, Kasyu I, Manabe T. Gastric foveolar metaplasia with dysplastic changes in Brunner gland hyperplasia: possible precursor lesions for Brunner gland adenocarcinoma. *Am J Surg Pathol.* 2005; 29:1442-1448.
8. Akaki M, Taniguchi S, Hatakeyama K, Kushima R, Kataoka H. Duodenal mucosal damage is associated with proliferative activity of Brunner's gland hamartoma: a case report. *BMC Gastroenterol.* 2014;14:14.
9. Chong KC, Cheah WK, Lenzi JE, Goh PM. Benign duodenal tumours. *Hepatogastroenterology.* 2000;47:1298-1300.
10. Zanetti G, Casadei G. Brunner's gland hamartoma with incipient ductal malignancy: report of a case. *Tumori.* 1981;67:75-8.