

Cholesterol Granuloma of Paratesticular Tissue: Report of a Rare Case

Amoolya Bhat^{1*}, Vijaya C¹, D.H. Biradar², Safarulla and Suraksha Rao B¹

¹Department of Pathology, Sapthagiri Institute of Medical Sciences and Research Centre, Bangalore, India

²Department of Surgery, Sapthagiri Institute of Medical Sciences and Research Centre, Bangalore, India

Keywords: *Cholesterol Clefts, Cholesterol Granuloma, Fibrinous Necrosis, Paratesticular Tissue*

ABSTRACT

Cholesterol granuloma (CG), also known as cholesterol cyst was first reported by Manasse in 1894. It is as an expansible benign mass that contains brownish-yellow debris with cholesterol crystals. Clinically it has a slow growth. It can affect any organ or tissue, though the temporal bone, chiefly the petrous apex is the most common site. We report an unusual case of cholesterol granuloma that developed in the paratesticular tissue in a 61 year old man.

***Corresponding author:**

Dr. Amoolya Bhat, Assistant Professor, Department of Pathology, #15, Chikkasandra, Hesarghatta Main Road, Sapthagiri Institute of Medical Sciences and Research Centre, Bangalore – 90. INDIA

Phone: +91 9480315066

E-mail: amoolyabhat@rediffmail.com



Introduction

Cholesterol granuloma is a fibrogranulomatous cystic lesion that develops from foreign body reaction to cholesterol crystals and exhibits the accumulation of foreign body giant cells along with mononuclear cells. Commonest sites of occurrence are air-filled spaces of the middle ear region of the temporal bone^[1]. It is known to arise in the kidney, testis, epididymis, tunica vaginalis, tunica albuginea^[2] breast, orbit, lung, peritoneum, subcutaneous tissues, parotid gland, liver, and spleen^[3]. It is a benign inflammatory lesion, sometimes referred to as a pseudotumor and is not classified as a true tumor as it lacks a definitive lining epithelium. We present a very rare case of cholesterol granuloma of the paratesticular tissue.

Case Report

A 61 years old man came to the surgery OPD with the chief complaints of painless swelling in the left side of the scrotal sac since past 20 years. There was no history of trauma or sudden increase in size of the swelling. On examination the lesion was round to oval and measured about 8x6cm. It was non-tender and firm in consistency. Transillumination test was negative. The right inguinal region showed an indirect reducible hernia. The right testis was unremarkable. He did not have fever, cough or any other swellings in the body. A fine needle aspiration cytology of the swelling on left side of scrotum yielded haemorrhage and scanty necrotic material. Hence a definitive cytological diagnosis was not rendered. A provisional clinical diagnosis of left paratesticular tumor was made and excision biopsy was carried out along with excision of the left testes as the mass was adherent to the testes [Figure 1a]. Right sided inguinal hernioplasty was also performed.

Grossly the mass measured 7.5x6.5x4.5cm and the detached testis measured 6.5x4.5x4cm. Cut section of the mass showed a cyst with intraluminal brownish friable necrotic material. The wall thickness of the cyst was 0.5cm. Inner surface of the cyst wall showed ragged appearance. Cut surface of the testes showed thickened covering layers along with unremarkable testicular tissue and epididymis [Figure 1b].

Histopathological examination showed cyst wall composed of dense fibrocollagenous tissue and smooth muscle cell bundles along with small foci of calcifications. Dilated and congested blood vessels were seen surrounded by dense mononuclear cell infiltrates [Figures 1c&d]. The luminal aspect did not exhibit a definite lining epithelium [Figure 2a]. Lumen showed abundant fibrinous necrotic material and numerous cholesterol clefts [Figure 2b]. Foreign body type of giant cells in aggregates surrounding the cholesterol clefts [Figure 2c] were seen along with

haemosiderin laden macrophages [Figure 2d]. Areas of haemorrhage and cystic degenerations were seen. There was no atypia or increased mitosis. Acid fast stain was negative for acid fast bacilli. The patients' post operative course was uneventful. His complete haemogram, urine examination findings, chest x ray and ultrasonography of the abdomen and pelvis was unremarkable. The features were suggestive of cholesterol granuloma. His serum lipid levels were evaluated and were within normal limits.

Discussion

Cholesterol granuloma is a benign fibrogranulomatous lesion that develops secondary to a foreign body reaction to cholesterol crystals. It usually affects the middle ear and paranasal sinuses, however it can affect any site. Its etiopathogenesis is unknown. It has been hypothesized that an inflammatory reaction induces ischemic necrosis, granulomatous reaction, and fibrosis. Ischemia induced rupture of blood vessels results in extravasation of blood containing cholesterol, fibrin, and hemosiderin. The cholesterol crystals elicit a foreign body reaction forming giant cells and granulomatous tissue^[1-4]. Leakage from the ectatic ducts in breast lesions and trauma in case of middle ear and air sinuses has been postulated as etiologic factors^[3]. It is sometimes referred to as a pseudotumor as it lacks lining epithelium. Also, it can present as a cystic or partially cystic lesion. Elevated serum lipid levels and hypercholesterolemia have been suggested as etiologic factors by some authors^[5]. Our patient did not have features of dyslipidemia.

The scrotal lesions are clinically asymptomatic. The commonest presenting complaint is painless lump in the scrotal sac^[2,4]. Occasionally it can present as acute scrotum^[7] or may be just incidental findings at general health check up or autopsy^[3].

Histopathologically it shows fibrinous necrotic material and abundant cholesterol clefts surrounded by foreign body giant cells monocytes and lymphocytes. Haemosiderin laden macrophages and areas of haemorrhage are seen. The cyst wall doesn't exhibit lining epithelium and shows only dense fibrocollagenous tissue along with bundles of smooth muscles^[2-4]. Our case showed focal areas of calcifications in the cyst wall in addition to these findings. Occasional report has described osseous metaplasia within the cholesterol granuloma^[6].

Their clinical differential diagnoses include spermatocele, adenomatoid tumour and benign /malignant paratesticular neoplasms. Other granulomatous lesions that can arise in this location include tuberculosis, sarcoidosis, malakoplakia and spermatic granuloma^[4,7].

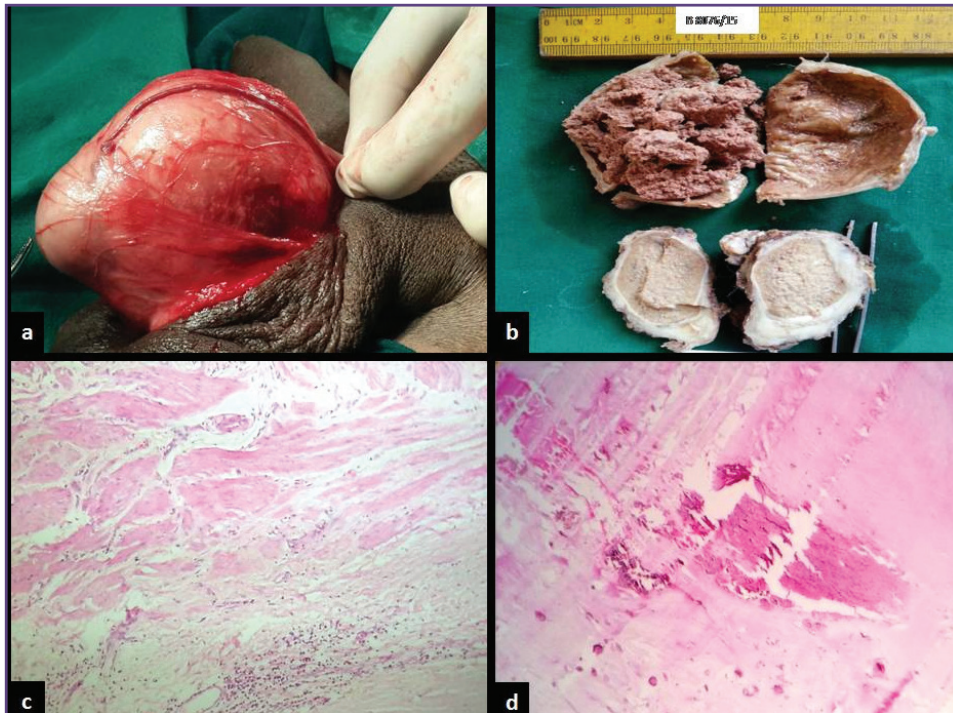


Fig. 1: a) Paratesticular mass adherent to testis. b) Specimen consisted of cystic lesion with intraluminal brownish material and ipsilateral testis. Photomicrographs showing c) cyst wall with bundles of smooth muscle cells d) dense fibrocollagenous tissue and foci of calcifications.

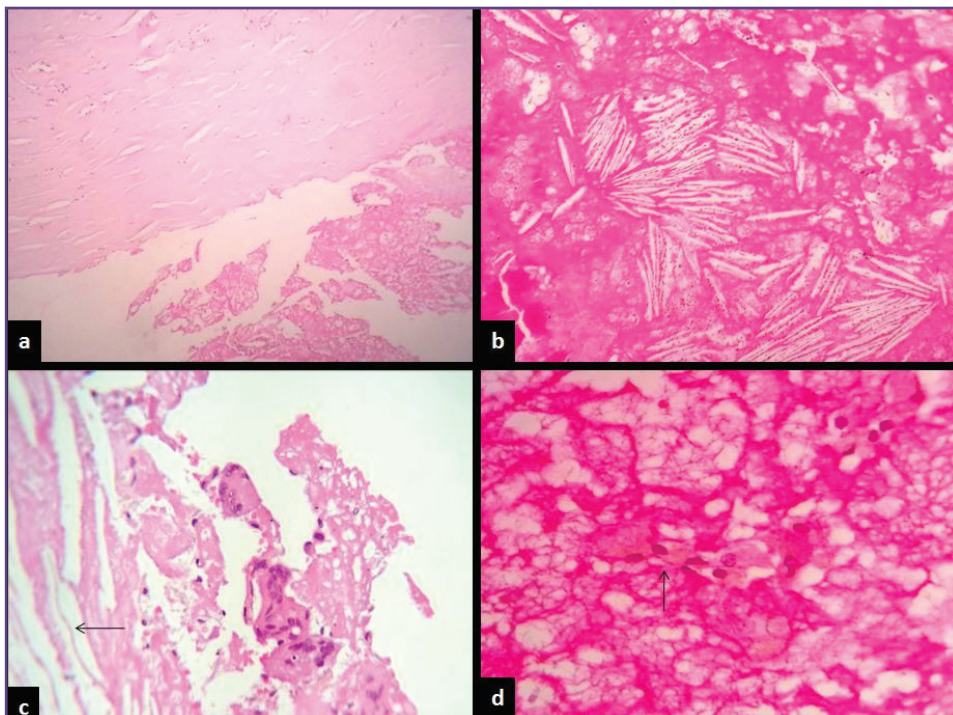


Fig. 2: Photomicrographs showing a) intaluminal aspect of the cyst lacking the lining epithelium b) fibrinous necrotic material and numerous cholesterol clefts c) cholesterol clefts (arrow) surrounded by foreign body giant cells and mononuclear cells d) haemosiderin laden macrophages (arrow).

Tuberculosis shows well formed granulomas composed of epithelioid histiocytes and Langhans giant cells with central caseation necrosis surrounded by peripheral cuff of lymphocytes and fibrosis. Acid fast bacilli may be positive. Sarcoidosis shows non caseating granulomas with giant cells showing asteroid bodies. Malakoplakia shows sheets of foamy histiocytes, chronic inflammatory cells and Michaelis Gutman bodies within the giant cells. Cholesterol crystals are lacking in all these lesions. Spermatic granulomas can be painful and grow up to several centimeters. However they show central area of degenerated sperms surrounded by well formed granulomas and develop in men after vasectomy^[8].

Spermatocoeles are the most common cysts of the scrotum. They are formed from retention of a tubule of rete testis and head of the epididymis. They are painless and grow upto several centimeters in size. They are transilluminaton test positive and show cyst wall line by ciliated columnar cells and intraluminal proteinaceous fluid and spermatozoa^[8].

The adenomatoid tumor of epididymis arises from the mesothelial cells and has multiple microscopic appearances. The three basic patterns are tubules, cords, and small nests. The tumor cells are cuboidal with vacuolated cytoplasm. Lymphatic infiltration may be seen. Gaping spaces without lining epithelium, representing necrotic tubular components, and smaller spaces, representing remnants of the typical vacuolar spaces, are major clinching points to the diagnosis^[9].

Histologically, papillary cystadenoma shows encapsulated tumor composed of multiple cystic spaces with intracystic papillary projections lined by clear cells, mimicking renal cell carcinoma. It is of mesonephric derivation^[10].

Conservative management is the treatment of choice for cholesterol granuloma; however, if there is a clinical suspicion of tumor, surgical exploration with biopsy and histopathological examination may be considered^[3,6].

Conclusion

Cholesterol granuloma arising in the paratesticular region is an extremely uncommon. It can grow into large dimension in this unusual site unlike in head and neck areas and lead to diagnostic dilemma. In our case the preoperative diagnosis was extremely challenging, considering the unusual site, and unusually large size. Cytodiagnosis can also be misleading due to the presence of necrotic material.

In this area, it can be mistaken for tumors of the testes and epididymis. Hence it should be considered as a differential diagnosis in evaluation of patients with scrotal masses.

Funding

None

Competing Interests

None Declared

Reference

1. Nikolaidis V, Malliari H, Psifidis D, Metaxas S. Cholesterol granuloma presenting as a mass obstructing the external ear canal. *BMC Ear, Nose and Throat Disorders* 2010, 10:4.
2. Unal D, Kilic M, Oner S, Erkinuresin T, Demirbas M, Coban S, MAYdos M, Cholesterol granuloma of the paratesticular tissue: A case report. *Can Urol Assoc J* 2015;9(5-6):E390-2.
3. Luckraz H, Coulston J, Azzu A. Cholesterol Granuloma of the Superior Mediastinum. *Ann Thorac Surg* 2006;81:1509–10.
4. Lam CY, Lin CM, Tsai SW, Hsieh TS. Cholesterol granuloma of the epididymis mimicking a paratesticular tumor. *JTUA* 2009;20:89-91.
5. Mendonça R, Peron C S, Stefani MA, Gallo P. Cerebral cholesterol granuloma. *Arq Neuropsiquiatr* 2007; 65(2-B):540-541.
6. Ezzat TF, Alowami S. Cholesterol granuloma of the anterior mediastinum with osseous metaplasia. *Rare Tumors* 2012;4: e47.
7. Spajic B, Cupic H, Stimac G, Brigic I, Kruslin B, Kraus O. Cholesterol granuloma of the right epididymis mimicking an acute scrotum. *Asian J Androl* 2006;8(6):749- 50.
8. Rosai J, Ed. In: *Rosai and Ackerman's Surgical Pathology*, Mosby an imprint of Elsevier, 9edition, 2009.
9. Kontos S, Fokitis I, Karakosta A, Koritsiadis G, Mitsios K, Koutsikos S, Koritsiadis S. Adenomatoid tumor of epididymidis: A case report. *Cases Journal* 2008, 1:206 doi:10.1186/1757-1626-1-206.
10. Odrzywolski K J and Mukhopadhyay S. Papillary Cystadenoma of the Epididymis. *Archives of Pathology & Laboratory Medicine* 2010; 134: 630-3.